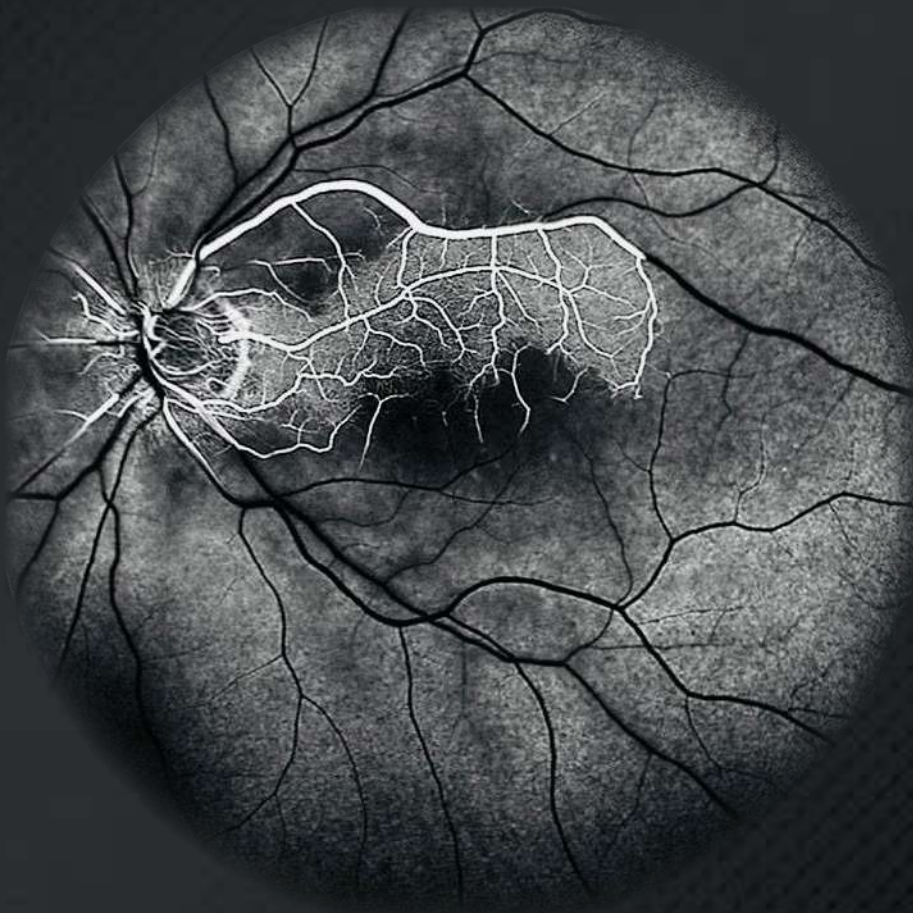




ISSN 2395-4698  
Vol 3, Issue 1, May 2022

# JOURNAL OF VISION SCIENCES

OFFICIAL PUBLICATION OF THE KARNATAKA OPHTHALMIC SOCIETY



**Dr. Sunil Ganekal**  
Editor in Chief

# From Editor's Desk



## *Dear Readers*

*Hope you and your family are safe. The Covid-19 Pandemic has brought us all in an unprecedented situation and we have challenging and uncertain times ahead. Journal of visual science is an online, peer-reviewed open access journal. This is the first issue during this pandemic. Editorial article includes the art of writing and publishing a manuscript which is very essential. Highlights of the current issue are Review articles on current topics, original articles, case reports, practice pearls, novel surgical techniques and master class on handling cataract surgery complications. I thank all the office bearers of the KOS for their support and guidance. I would like to thank Dr Rohit shetty and Dr Pooja Khamar for their valuable time and assistance in bringing this issue. Please reach out to us at [editorjvsjournal@gmail.com](mailto:editorjvsjournal@gmail.com). We will respond to your queries at the earliest.*

**- Dr Sunil Ganekal**

*Editor-in-chief JVS*

# TABLE OF CONTENTS

<b>1. Editorial - Art of publishing a Scientific Paper</b> - Dr Sunil Ganekal	1
<b>2. Tips for writing a well composed scientific paper</b>	5
<b>3. Guest Editorial- Orbital Exenteration for the oculo-plastic surgeon: what has changed now?</b> - Dr.Akshay Gopinathan Nair	6 - 8
<b>4. Six Steps to Successful Publishing</b> - Dr Sabyasachi Sengupta	9 - 10
<b>5. Ophthalmic practice pearls- Mergers and Acquisitions (M&amp;A) in Indian Ophthalmology</b> - Dr Senthil	11 - 13
<b>6. Review articles</b>	
• <b>Update on Minimally Invasive Glaucoma Surgery (MIGS)</b> - Dr Isabella V. Wagner, Dr Syril Doriraj,	14 - 23
• <b>Keratoconus management and updates</b> - Dr. Ritika Mullick, Dr. Ritica Mukherjee	24 - 31
• <b>Implantable collamer lens (ICL)</b> - Dr. Pooja Khamar, Dr. Savitri Deval, Dr. Anuj Satija	32 - 41
<b>7. Original articles</b>	
• <b>Safety and efficacy of Intracameral Mydriatics: Lignocaine and Epinephrine in manual small Incision cataract surgery and their effect on blood pressure and heart rate</b> - Dr Suresha Rajappa, Dr Gunashree	42 - 46
• <b>Modified classification of Indirect Choroidal rupture (ICR) based on morphological pattern by Optical coherence Tomography and its relation to choroidal neovascularization</b> - Dr Unnikrishnan Nair, Dr Manoj Soman	47 - 52
• <b>Anterior capsule sparing parsplana lensectomy in cataract with severely compromised corneal endothelium</b> - Dr Sunil Ganekal, Dr Nirmal Prasad	53 - 56

# TABLE OF CONTENTS

- **Refractive and Keratometric outcomes of supervised novicesurgeon-performed limbal relaxing incisions (LRI'S)**  
- Dr Satyamurthy KV, Dr Mahantesh P shetty 57 - 61

## 8. Case Reports

- **Ocular pemphigus masquerading as Ocular Surface Squamous neoplasia (OSSN)**  
- Dr Shylaja Shivashankarappa 62 - 63
- **Vitreoretinal Lymphoma masquerading as posterior Uveitis-**  
- Dr Prakash V. S. 64 - 65
- **Bilateral combined Central retinal artery& vein occlusion (CCRAVO) in COVID**  
- Dr Sunil Ganekal, Dr Nirmal Prasad 66 - 68
- **Absorbable gelatin sponge plug for posterior scleral perforation secondary to impacted metallic intraocular foreignbody (IOFB)**  
- Dr Rajesh Ramanjulu 69 - 70
- **A Fungating mass in Anterior chamber secondary to adenocarcinoma of Lung**  
- Dr Suresha AR, Dr Fayiza Musthafa 71 - 73
- **Loop Myopexy in the management of Myopic Strabismus Fixus –**  
- Dr Sunayana Bhat, Dr Shachi Shetty 74 - 76
- **Seborrheic Keratosis masquerading as basal cell carcinoma**  
- Dr Chinmayee J T, DR Anjali Hiroli 77 - 78
- **Corneal bee sting injury**  
- Dr Kaiyoor Surya Divyalakshmi, Dr Aditi Vidha 79 - 80

## 9. Surgical Pearls in handling cataract surgery complications

- **How to manage post cataract surgery temporal reflections and shadows –**  
- Dr Prakash V. S. 81 - 82
- **How to manage Descemet's membrane detachment?**  
- Dr Varun Malhotra 83 - 85

## 10. Surgical Technique -Artificial Bag with Optic Capture (ABC) surgical Approach for Secondary Intraocular Lens Implantation

- Dr Sunil Ganekal 86 - 87

# Art of publishing a Scientific Paper

- Dr Sunil Ganekal

**“A professional writer is an amateur who didn’t quit.” - Richard Bach.**

### Introduction

With the stringent regulations from various academic bodies making it desirable for a post graduate resident to have submitted an original article prior to appearance for their exams or those working in teaching institutions to have published articles to claim credit for applying for promotions and private practitioners to increase their visibility on the academic front, paper, everyone is on a publishing spree. In this article, I attempt to elucidate the processes involved in publication; approaching it in a systematic and practical manner, incorporating some tips and tricks. This collection of pearls is aimed to serve as a beginner’s guide to scientific writing and publications. The pearls cover assorted topics like- benefits of publications, collecting resources, various tools available and technical processes related to how a manuscript is processed.

**Key Words:** Articles, beginners, paper publication, scientific writing.

### “Why”and “why not” of publishing?

It is important for the uninitiated reader to realize the benefits of publication. Publishing papers has obvious advantages for all stakeholders. It adds value to one’s resume and opens up avenues for scientific collaboration with others working in the same field. A talk in a conference may be forgotten with time, but a published paper remains recorded forever, as if etched in stone. Another advantage is that working up clinical material for publication also helps in developing an in-depth understanding of the particular condition. With professional career promotions and grants directly linked to the number of papers, there is more pressure to publish. Finally, every clinician by default is a scientist too and is duty bound to aid the evolution and dissemination of scientific knowledge.

### What to Write and Where to Send? (The Navigation)

For a beginner, it is easy and advisable to submit articles to sections that demand fewer words so that the preparation of the manuscript and the submission process becomes less tedious. This, of course, does not mean that a good original study should not be your first article. In addition, do not refrain from submitting your innovative or crazy ideas if you can put it across in a good way. While journals having a low impact factor are easier to publish, we would suggest submitting to a journal with good impact factor initially. Even if it is rejected, you would get some useful points based on which you can improve your manuscript. For original studies, we suggest that the author be familiar with Glassick’s scholarship criteria.<sup>1</sup> In addition, make sure that the choice of journal is right – the “scope” of the journal is usually mentioned explicitly

in the home page of the journal. Submit your article only if you think it would cater to the targeted readership. One of the most common reasons for rejection of an article is that it addresses an area beyond the scope of the journal. Once you decide on the journal, one important point is to always stick meticulously to the instructions given. Avoidable delays are often due to the manuscript being returned for changing the format to the one prescribed by the journal, especially in some areas such as word limits and reference styles.

### Gather Resources and Organize Them Too (The Pebble Collection)

Try to have a complete set of the material required for the publication. Do not ever give a chance for you to get disheartened just because the images are not traceable after completing the rest of the manuscript preparation for submission. This is just to cite an example and to stress the importance of gathering all the basic requirements (viz., histopathology images, references, clinical pictures, consents, and copyrights to name a few). Catalog clinical images and diagnostic images, keep building databases and keep looking out for patterns. People often start off with case reports – then progress to case series and randomized controlled trials, but case reports still retain an inherent value.<sup>2</sup> Images are vital in Ophthalmology. Learn to take and store good clinical images. Keep consent forms for photography and get it signed at the time of shooting itself. Ideally, the signed form should be scanned and saved as well.<sup>3</sup> I would suggest keeping all data connected with a particular article organized in folders with easily recognizable names for effortless retrieval later. Manuscript Preparation:

How to Overcome Language Barriers and Handle Other Technical Requirements (The Armamentarium) when you are not a native English speaker, there can sometimes be difficulties in drafting the manuscript especially when you submit the manuscript to an international journal in the English language format. Some publishers have their language editing services, which are a good utility in such situations.<sup>4</sup> The author can also get it peer reviewed by colleagues for correcting linguistic and grammatical errors prior to submission. There are also various online sources who offer these services for nominal charges. An article with unsatisfactory language or gross grammatical errors will get unnecessarily delayed in the publication process. Remember when it comes to your paper seeing the light of day at the earliest, every minute counts! The basic model in any journal submission is comprised the title file (called first page file by some journals), article file, image files, videos, charts, tables, and copyright/consent forms. Though the content may vary, the basic structure can be replicated from your other articles thus saving a lot of time and effort. It is best to submit a good quality image – well focused, with good resolution, and without background distractions for easy acceptance and review.<sup>5</sup> However good an article may be, a bad image corrupts its value. Submit as many images as possible when the upper limit for the number of images is not defined. Collaborate with histopathology expert to get the best quality histology images. In general take more images than you need. You can always delete the unnecessary ones later. Software such as MS (Microsoft) Office Word™ and Adobe Acrobat Reader™ are adequate for almost all the works for paper publication. Knowledge of Picasa™/Adobe Photoshop™ would be a bonus for working on images. Referencing software like EndNote™ can be a valuable addition to MS Office.<sup>6</sup>

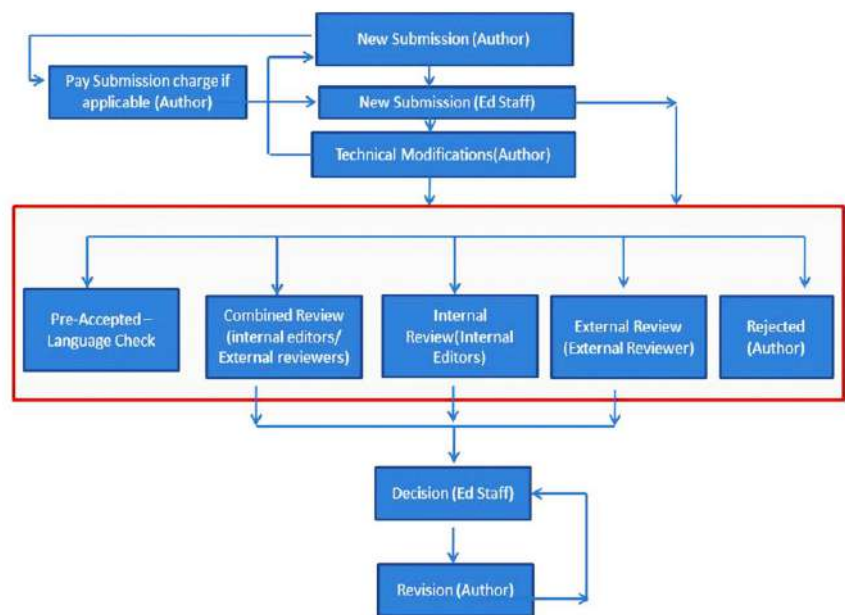
### Sourcing Articles (The Treasure Hunt)

One of the biggest hurdles researchers is article sourcing. With the advent of information technology, things are easier than before. Some of the never miss resources for article sourcing are Google Scholar™, Pubmed™, Scopus™, MD Consult™, Ebsco™, etc., apart from journal and books. For solo practitioners without institutional attachment, it may be even more difficult and participating in forum of professionals (ACAD\_IADVL yahoo group of IADVL is one such forum), networking with people as in congresses and network sites such as ResearchGate™ and seeking pharmaceutical help to source articles are all ways for those who have the

“never say die” attitude. Moreover, many journals have the option to register via mail for the table of content. This facilitates an E-mail alert whenever an article is published in the respective journal. The researcher can benefit by choosing and collecting articles that are useful for them and their area of interest.

### Understand Statistics (Not always Latin and Greek!)

Most of us just hand over the statistics part to the statistician and blindly follow their findings. It is always better to gain a basic understanding of the fundamental statistical principles and one should try to learn along the way with each study or article. You do not have to be an expert, but an understanding helps in proper planning and determining the feasibility of the project in the initial phases itself. Be Thankful (Courteousness Pays) Be generous in thanking every person who has helped in making your paper worthwhile. You do not lose anything but gain a lot by winning their confidence and leaving the door open for future help requests. The acknowledgment section of the article is exclusively for this purpose and does not dilute the value of the paper in any way. This is to accommodate people who otherwise do not qualify to be co-authors. Furthermore, it is always better to follow the standard recommendations for authorship as far as possible.<sup>7</sup> Abstract (The Visiting Card) This is the gist of what is in the article. The abstract can be structured or unstructured according to the type of article. It is important to make the abstract short enough to comply to the journal instruction and sweet enough to attract readership. Abstracts help users judge the relevance of the research work and provide a handy synopsis of its contents, and sometimes, they may even serve as a substitute for the original document. Referencing should not be used in abstracts and foreign languages are best



Flow of events from submission to acceptance of a manuscript in the review process of article cycle.

avoided. A usual mistake which many 1st time authors do it to mistake an abstract for the introduction. The abstract is a short summary of the entire article, not a condensed version of the introduction.<sup>8</sup> Key Words Most journals require 4–8 key words to be submitted along with the manuscript. Most journals specifically request key words used in the US National Library of Medicine’s collection of Medical Subject Headings and some journals will ask the author to select from a list of key words already present in the journal’s submission site. It is best to choose terms which best explain the essence of the article. Keep it simple and avoid esoteric terms and abbreviations. If your title is well crafted, you can choose key words from within the framework of the title.<sup>9</sup> The Submission and After There are mainly five situations that happen to an article once submitted. The editors or after an editorial board review, checks the manuscript for the quality and then comes to one of these conclusions [Figure 1].

- Accept with minor revision: Do this process and resubmit as soon as possible before the referees forget the paper
- Major revision needed: Find time but it is worth the effort because the journal may be ready to accept the article provided the revision is made as desired
- A complete rewrite required: This needs to be taken seriously and do it if you have the resources and time in hand and is worth effort
- Change format and resubmit: Usually this involves changing to a short format – for example from an original report to a letter. If you feel that it really important for the study to be published as such, it would make sense to withdraw the article and go for an alternate journal. However, if you feel that the essence of the material can be conveyed in the suggested modified format it may be worth submitting in the changed format. This is a bit of gambling and one needs to try the luck of changing format as asked by the journal and resubmitting though there is no guarantee that it will be accepted then unless committed by the editorial
- Outright rejection. This door is closed. Please try your luck elsewhere is the message
- It is very rare, though not impossible, for an article to be accepted without any changes in a good journal.

### **Hope for the Best but Expect the Worst! (The Fear Factor of Rejection)**

It can be very frustrating for a novice to face rejection. The reasons for rejection may often seem unfair, but this is something which all authors have to live with, even those who have “heavily” published. Keep trying in alternative journals, the scope of which fits in with your work. Common reasons for rejection of an article are beyond the

scope of this article but an interesting and very useful take on the same is given in an article by Hagger, titled “How to get your article rejected.” We would suggest all first time authors to go through this article.<sup>10</sup>

### **Sooner the Better. Leave Your Mark (Early Bird)**

Do not wait for the right day or the best time. It is right here already. Someone else may be already working on the same concept elsewhere and they may get their article published ahead of you. If you have an original thought or a work ready with you, try to submit it as fast as possible even if the journal asks you to convert it to a letter to the editor or a short communication. It may be worth the compromise. The first one is the most cited article and the article type is immaterial. Two classic examples are Watson and Crick’s structure of DNA published in Nature and the teratogenic potential of thalidomide published in Lancet, as “mere” letters to the editor.<sup>11,12</sup>

### **Familiarity Factor**

Once we submit one or two articles in a journal, we get used to the system and are often advantageous because many journals will be from the same publishing house and technical aspects of paper submission are the same and follow similar general templates and instructions for submission of articles.

### **Attend Conferenes, Network & Create an Identity (Being a More Social Being)**

Attend conferences whenever you get a chance. You can interact with great authors and researchers and forge a tie to interact later. You also get to meet a lot of seniors and experienced professional colleagues who can give you the much needed guidance on how to go about with the paper you are working. They may also be able to help you by offering to be a co-author or contributing material that would be otherwise impossible for you to get yourself. Sites such as ResearchGate<sup>TM</sup> or Academia.edu<sup>TM</sup> can be compared to the Facebook<sup>TM</sup> or Twitter<sup>TM</sup> of researchers. Their mission is to connect researchers and make it easy for them to share and access scientific output, knowledge, and expertise. On ResearchGate<sup>TM</sup>, you find what you need to advance one’s research and helps to connect and collaborate with researchers across the globe. ResearchGate<sup>TM</sup> today has more than 6 million members.<sup>13</sup> One needs to have an institutional E-mail id to register (which can be changed thereafter) and can follow and get followers. This helps to get alerts and updates from people working in one’s area of interest, interact with them and request their publications for references. Some researchers are generous enough to upload their published works on their profiles which can be freely downloaded at your end for references. Open Researcher and Contributor (ORCID<sup>TM</sup>) is an open, nonprofit, community-based effort to provide a registry of unique researcher identifiers and a transparent method of linking research activities and outputs to these identifiers. ORCID<sup>TM</sup> is unique in

its ability to reach across disciplines, research sectors, and national boundaries and its cooperation with other identifier systems.<sup>14</sup> This is a unique identification mark every author should have to make them easily identifiable for the journals and editors. It takes very less time to register, is absolutely free, and can be linked to all your profile and manuscript submission sites. More than 1000 journals are now using ORCIDTM for identification.<sup>15</sup> This is cited at the time of submission of the manuscript and by default gathers all the relevant information about yourself and your works published earlier. One of the best things that can happen in your literary life is finding colleagues with whom you can work without ego. It is a win-win game and one person's weak area may be the other person's strong point. With present day electronic communication infrastructure, partnering or collaborating with even a distant colleague is very easy. .

### Dare to Compare

After a couple of articles are through, you can very well try to apply as a reviewer in some journal. Being a good reviewer helps you become a better author and vice-versa. The process through which a manuscript travels improves your understanding of the publication process. This increases the morale and motivates you to take up scientific writing more aggressively and effectively.

### Make the Best of Expected and Unexpected Holidays (Piggy Back Effect)

India is a land of celebrations and festivals in plenty and holidays that come in handy to finish pending works. It is a hard fact too that India is one country where you may get "impromptu holidays" all on a sudden due to hartals.<sup>16</sup> and strikes. Someone who has compiled and collected all the material can do adequate works on such days. To put it in better words, make the best out of the worst.

### Stick with the Ethics

Be truthful, try to avoid short cuts, and be ethical in all aspects of publications – data collection, data recording/

interpretation, and the manuscript writing part. Unethical practices can lead to very severe setbacks to your career. Avoid all forms of plagiarism and salami research.

A related area is authorship criteria. You need to have a clear idea on who deserves to be a co-author. Basically, four important criteria are to kept in mind:

- Substantial contributions to the conception or design of the work; or the acquisition, analysis, or interpretation of data for the work;
- Drafting the work or revising it critically for important intellectual content; final approval of the version to be published;
- Agreement to be accountable for all aspects of the work in ensuring that questions related to the accuracy or integrity of any part of the work are appropriately investigated and resolved.

All those designated as authors should meet all the above mentioned criteria, and also all who meet the four criteria should be identified as authors. Detailed guidelines are available at the International Committee of Medical Journal Editors site.<sup>17</sup> Good Things Take Time (The Patience Effect) Nothing happens overnight. The time taken by an article from submission to final publication depends on various factors. The perceived impact of the manuscript, a delay from one or more of the referees, a delay on the side of the editorial in reaching a decision, a technical delay at the publisher level, and the frequency of publication of the journal are some of the factors associated with a delay in publication. Even an accepted paper goes through a lot of scrutiny at various levels. Some sections have higher volume of submission in some journals and obviously the queue gets longer. Such things are to be kept in mind especially by the novice who has more anticipation and excitement to see his research published. As a rule of thumb, from our limited experience, we have perceived 1 year to be the average expected time for an article from submission to publication, although this is an arbitrary figure with wide variability.

---

## References

1. Glassick CE, Huber MT, Maeroff GI. Scholarship Assessed: Evaluation of the Professoriate. San Francisco: Jossey Bass; 1997.
2. Rao A, Ramam M. The case for case reports. Indian Dermatol Online J 2014;5:4135.
3. Kaliyadan F, Manoj J, Venkitakrishnan S, Dharmaratnam AD. Basic digital photography in dermatology. Indian J Dermatol Venereol Leprol 2008; 74:5326.
4. Available from: <http://www.wileyeditingservices.com/en/>. [Last accessed on 2015 Apr 10].
5. Ramam M. Awards, images, instructions. Indian J Dermatol Venereol Leprol 2015; 81:13.



6. Available from: <http://www.endnote.com/productdetails>. [Last accessed on 2015 Apr 10].
7. Guidelines on authorship. International committee of medical journal editors. Br Med J (Clin Res Ed) 1985; 291:722.
8. Tenopir C, Jasco P. Quality of abstracts. Online 1993;17:44-55.
9. Editing Tip of the Week Choosing Effective Keywords. Available from: <http://www.expertedge.aje.com/2014/04/08/editing-tip-of-the-week-choosing-effective-keywords/>. [Last accessed on 2015 Aug 25].
10. Hagger MS. How to get your article rejected. Stress Health 2012; 28:2658.
11. Watson JD, Crick FH. Molecular structure of nucleic acids: A structure for deoxyribose nucleic acid. Nature 1974; 248:765.
12. McBride WB. Thalidomide and congenital abnormalities. Lancet 1961;278:1358.
13. Available from: <http://www.researchgate.net/about>. [Last accessed on 2015 Apr 10].
14. Available from: <http://www.orcid.org/content/aboutorcid>. [Last accessed on 2015 Apr 10].
15. Anstey A. How can we be certain who authors really are? Why ORCID is important to the British Journal of Dermatology. Br J Dermatol 2014;171:67980.
16. Available from: <http://www.en.wikipedia.org/wiki/hartal>. [Last accessed on 2015 Apr 10].
17. Available from: <http://www.icmje.org/recommendations/browse/roles-and-responsibilities/defining-the-role-of-authors-and-contributors.html>. [Last accessed on 2015 Oct 12].



<b>MANUSCRIPT PREPARATION TIPS</b>	
1	Assemble all the data and create an outline
2	Identify important scientific findings
3	Select data/figures/schemes/tables that support the scientific story
4	Select a journal based on the scope of your work, and not based on the journal's impact factor
5	Write a creative and attractive title that accurately represents scientific content
6	Write an abstract that clearly identifies the key scientific finding(s) and appeals to broad readership
7	Keep the abstract brief with minimal experimental details
8	Provide a good background and motivation that led to the research activity in the Introduction
9	Raise some degree of curiosity in the last paragraph of the Introduction
10	Discuss the results with a sequence that makes a nice story
11	Include a healthy scientific discussion, quantitative analysis, a model or a mechanistic scheme to explain the results
12	Draw figures with readable fonts. Make sure axis titles and units are correct and all data plots are clearly marked and explained in the caption
13	Provide experimental conditions or computational parameters in figure captions
14	Check the figure numbers and citations in the text to ensure correct referencing
15	Include complete experimental details so that the experiments can be reproduced elsewhere
16	Include name of the funding agency and others whose assistance made this work possible
17	Include additional details, as needed, in the supporting information
18	Make sure the references, formatted according to journal requirements, are accurate, and present a balance between seminal work and recent advances
19	Explain briefly the significance and scope of the work in the cover letter
20	Submit the manuscript and follow through the review process. Provide all the requested information during submission

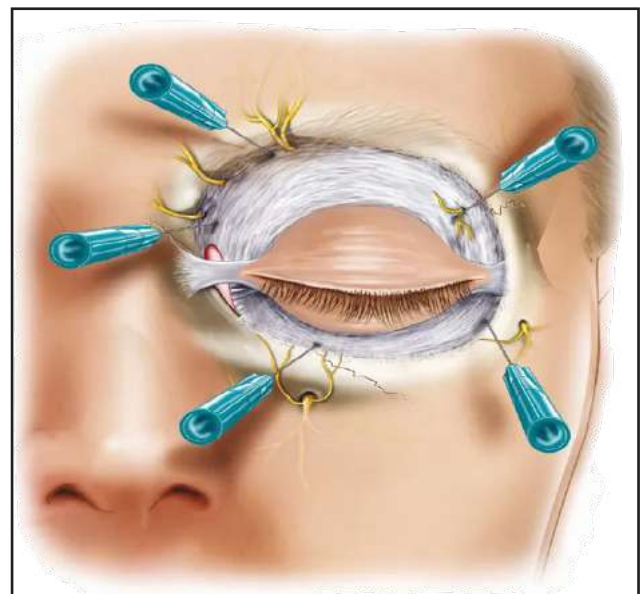
# Orbital Exenteration for the oculoplastic surgeon: what has changed now?

- Akshay Gopinathan Nair,<sup>1</sup> DNB

Consultant, Ophthalmic Plastic Surgery and Ocular Oncology Services;  
Advanced Eye Hospital & Institute, Navi Mumbai; Aditya Jyot Eye Hospital, Mumbai;  
R. Jhunjhunwala Sankara Eye Hospital, Panvel;  
Lokmanya Tilak Municipal Medical College & General Hospital, Mumbai  
.correspondence-akshay@drakshaynair.com

Orbital Exenteration is one of the most mutilating surgeries in ophthalmic practice. Many other specialists such as head and neck surgeons, ENT surgeons and neurosurgeons often perform this surgery; however, oculoplastic surgeons, by far are the commonest group performing this surgery. The indications for orbital exenteration are many including large, diffuse orbital malignancies as well as eyelid and conjunctival malignancies that have extended into the surrounding structures such as the globe and the orbit. The aim of performing an orbital exenteration in such cases is to achieve cure with tumour-free margins. However, the indications and the frequency of this surgery being performed have changed dramatically in the past two years. Most oculoplastic surgeons in the Indian subcontinent have performed more orbital exenterations for non-malignant conditions in the recent past than ever before. The culprit being the dreaded and potentially fatal invasive fungal disease, Rhino-Orbito-Cerebral Mucormycosis (ROCM). The recent spurt in COVID-19 associated mucormycosis (CAM) has led to an all-time high global burden of rhino-orbital-cerebral mucormycosis (ROCM) with India accounting for most of these cases.<sup>1</sup>

In cases of mucormycosis, the treatment strategy is multi-pronged with three main pillars of management: controlling the underlying immunodeficient, intravenous antifungal medications and endoscopic sinus debridement with or without adjuvant local intraoperative amphotericin B (AMB).<sup>[1,2]</sup> Orbital exenteration is typically recommended in patients who show progression of disease in spite of medical and surgical treatments.<sup>1-3</sup> Historically, the indications for orbital exenteration have been less specific with some authors advocating orbital exenteration for



clinical findings such as ophthalmoplegia, proptosis, cranial involvement and ocular involvement.<sup>4-10</sup> Some authors have even reported that exenteration could increase patients' survival in the presence of intracranial spread and rapid progression.<sup>6</sup> Controversially, it has also been reported that orbital exenteration, by itself, does not actually affect the patients' survival in ROCM.<sup>3</sup> The plausible explanation in these cases being that orbital exenteration was performed by these authors for patients in the end-stage disseminated fungal disease with intracranially extension, where reducing the disease load in the orbit may not particularly be helpful.<sup>3,7</sup> To summarise, there was no standard of care to guide physicians on when exenteration may benefit a mucormycosis patient.<sup>[10]</sup> In the early days of the mucormycosis pandemic, it is likely

that we, oculoplastic surgeons were possibly over treating and 'over-exenterating' in an attempt to be aggressive. However, over time, our understanding of the disease has helped us evolve our decision making..

### The rationale behind exenteration in ROCM:

In our experience, the decision to perform orbital exenteration in orbital mucormycosis must be based on the findings of radiological investigations, namely MRI of the orbit with contrast. The presence or absence of contrast enhancement on MRI is very important in understanding the disease process.<sup>11</sup> Typically in the orbit because mucormycosis affects the extraconal space and then involves the extraocular muscles. As a result, there is inflammation hyperaemia and congestion in the extraocular muscles. On MRI this is seen as increase in size of the extraocular muscles along with contrast enhancement as a result of the inflammatory changes and hyperaemia. Therefore, when contrast enhancement of the extraocular muscle is seen, it indicates that the contrast material which is injected intravenously is reaching the site that is visualised on the scan; therefore the intravenous amphotericin B that is given to treat the patient would also reach the involved site.<sup>11</sup>

Typically, mucormycosis causes angio-invasion and subsequent occlusive thrombosis of the involved blood vessel. This is seen radiologically as loss of contrast enhancement: if the contrast material is not able to reach the site that is seen on the scan, it is unlikely that the intravenous drug would also be able to reach the site. Therefore, the site and amount of loss of contrast enhancement decides the type of surgical intervention in cases of mucormycosis.<sup>11,12</sup> Based on this understanding of the disease or recommended indications for orbital exenteration are as follows:

- Loss of contrast enhancement over apex
- Generalized loss of contrast enhancement in entire orbit
- Globe distortion with intraconal abscess
- Perineural with diffuse intraconal involvement

While mutilating and associated with significant quality of life issues, exenteration in ROCM when indicated has helped in local disease eradication which has resulted in better survival.<sup>1</sup>

Clear guidelines on the indications of orbital exenteration have since been laid down as a guide for treating surgeons.<sup>13</sup>

### Exenteration in periocular malignancies.

Recently, Malik et al. published an insightful paper which looked at their data on orbital exenteration in advanced periocular tumours.<sup>14</sup> The aim was to evaluate the survival benefit of orbital exenteration in periocular malignancy. They looked at details of patients undergoing orbital exenteration between 1993 and 2019 at Moorfields Eye Hospital. The demographics, location, histology, and prior management of the primary tumor were derived from clinical records, together with details of the exenteration, complications of the surgery, and the nature of any postoperative adjuvant therapy. They classified the patients into two classes: Class I included patients that were 'T<sub>4</sub>N<sub>0</sub>M<sub>0</sub>' where exenteration possibly to be of "curative" intent. Class II included those with known active widespread disseminated disease ("Class II"; T<sub>4</sub>N<sub>1</sub>M<sub>0</sub> or T<sub>4</sub>N<sub>1</sub>M<sub>1</sub>), where exenteration is likely to only be "palliative." A further classification was also done: based on the extent of orbital disease and exenteration intent: Group A - where surgery was locally curative or Group B when was locally palliative. Interesting outcomes from their paper included the finding that histological clearance margins of >1 mm to improve overall survival at 5 and 10 years, but a wide clearance margin (of >5mm) did not appear to significantly improve the prognosis after exenteration. Furthermore, survival was significantly better after type IIA procedures (locally curative but systemic disseminated disease) as compared to type IIB (locally palliative with systemic disease): this suggests that even in systemically incurable patients, ~12% will survive more than 5 years with local control of disease and it underlines the importance of exenteration local management for incurable patients. Often times, an orbital exenteration may not be offered to a patient with a locally aggressive periocular/eyelid tumour with orbital extension and systemic spread, but this data shows that if an orbital exenteration is performed in such cases with adequate margin clearance, it may help in increasing the survival. We continue to learn from history and a surgery which was described centuries ago by George Bartisch and refined later by Arlt over a hundred and fifty years ago, still finds relevance in today's time and age.<sup>15,16</sup> Newer indications, newer techniques and better rehabilitation – have led to further refinement and evolution of this surgery which still saves lives.

## References

1. Nair AG, Adulkar NG, D'Cunha L, Rao PR, Bradoo RA, Bapaye MM, Kothari A, Dave TV, Shinde CA. Rhino-orbital mucormycosis following COVID-19 in previously non-diabetic, immunocompetent patients. *Orbit*. 2021. doi: 10.1080/01676830.2021.1960382.
2. Abdolalizadeh P, Kashkouli MB, Khademi B, Karimi N, et al. Diabetic versus non-diabetic rhino-orbito-cerebral mucormycosis. *Mycoses*. 2020; 63(6):573-578.
3. Kashkouli MB, Abdolalizadeh P, Oghazian M, Hadi Y, et al. Outcomes and factors affecting them in patients with rhino-orbito-cerebral mucormycosis. *Br J Ophthalmol* . 2019;103(10):1460-1465.
4. Peterson KL, Wang M, Canalis RF, Abemayor E. Rhinocerebral mucormycosis: evolution of the disease and treatment options. *Laryngoscope* 1997;107:855-62.
5. Ketenci I, Unlü Y, Kaya H, Somdaş MA, et al. Rhinocerebral mucormycosis: experience in 14 patients. *J Laryngol Otol* 2011; 125:e3.
6. Jung SH, Kim SW, Park CS, Song CE, et al. Rhinocerebral mucormycosis: consideration of prognostic factors and treatment modality. *Auris Nasus Larynx* 2009;36:274-9.
7. Reed C, Bryant R, Ibrahim AS, Edwards J Jr., et al. Combination polyene-caspofungin treatment of rhino-orbital-cerebral mucormycosis. *Clin Infect Dis* 2008;47:364-71.
8. Dhiwakar M, Thakar A, Bahadur S. Improving outcomes in rhinocerebral mucormycosis—early diagnostic pointers and prognostic factors. *J Laryngol Otol* 2003;117:861-5.
9. Kursun E, Turunc T, Demiroglu YZ, Alışkan HE, et al. Evaluation of 28 cases of mucormycosis. *Mycoses* 2015;58:82-7.
10. Hargrove RN, Wesley RE, Klippenstein KA, Fleming JC, et al. Indications for orbital exenteration in mucormycosis. *Ophthalmic Plast Reconstr Surg*. 2006;22(4):286-91.
11. Sreshta K, Dave TV, Varma DR, Nair AG, Bothra N, Naik MN, Sistla SK. Magnetic resonance imaging in rhino-orbital-cerebral mucormycosis. *Indian J Ophthalmol*. 2021;69(7):1915-1927.
12. Kalin-Hajidu E, Hirabayashi KE, Vagefi R, Kersten RC. Invasive fungal sinusitis: treatment of the orbit. *Curr Opin Ophthalmol* 2017,28:522-533.
13. Nair AG, Dave TV. Transcutaneous retrobulbar injection of amphotericin B in rhino-orbital-cerebral mucormycosis: a review. *Orbit*. 2021. doi: 10.1080/01676830.2021.1990351.
14. Malik M, Vahdani K, Rose GE et al. Orbital Exenteration for Advanced Periocular Adnexal Malignancies: Curative Versus Palliative Surgical Intent. *Ophthalmic Plast Reconstr Surg* . 2022. doi: 10.1097/IOP.0000000000002137.
15. Bartisch G. *Ophthalmomodoulcia*. Dresden 1583;3:208.
16. Graefe-Saemisch *Handbuch der ges. Augenheilk*. 1 Ed. Vol III. 1874. P. 434

# Six Steps to Successful Publishing

**Dr Sabyasachi Sengupta. DNB (Gold medalist), FRCS (G).**

Director, Sengupta's research academy,  
Chief Vitreoretina Surgeon, Future Vision eye care, Mumbai,  
Associate Editor, Indian journal of Ophthalmology.

Scientific publishing matters a lot these days. A lot of the renowned physicians are clinician – scientists with a volume of research work behind them. There are many advantages of publishing in peer-reviewed literature, including fame and recognition, grants and funding opportunities, academic promotions and the sheer thrill of contributing to patient care in your own way. However, the scientific journey of getting published requires you to follow a stepwise process, very much like learning surgery and other skills involved in good patient care. In this write up, I will attempt to simplify this process and divide it into six key steps.

## Step 1:

Do a good literature review and see what has not been done in your field of interest - find lacunae (gaps) in literature. This will make your paper novel and give something new for journal editors, reviewers and your readers to remember. The best way to do a good literature review is to use PubMed wisely. The PubMed website has a lot of tutorials that teach you how to optimize its use. For e.g., use of Boolean search strategies in the advanced search option to narrow down your search, use of Major Subject Heading (MeSH) terms to get better results etc. Learning how to use PubMed in an efficient way will save you a lot of effort and help you find gaps in literature that are worth pursuing.

## Step 2:

Design your study well based on the PICO approach where P = Participants, I = Intervention, C = Control group and O = Outcomes.

Participants refer to inclusion and exclusion criteria and your sample size. These go a long way in defining whom you are exactly studying and more importantly, on which patient populations your study results are most applicable to. So think hard and define these well.

Intervention refers to what was exactly done in the study. This does not necessarily imply an invasive intervention like surgery, but has much broader implications including the interviews conducted (qualitative research), drug(s) administered (RCT), screening tests used etc. In summary, any tool used to gather data becomes the intervention. Controls mean anyone who does not have the disease condition being studied or does not receive the intervention under study. This is a crucial step in study design that provides a comparative group and helps to make your results robust. Unfortunately, this is missed by

a lot of researchers and not having a control group can make your study weak. Always think about controls when you are designing a study.

Outcome, as the name suggests, is the primary result that you want to study. In addition to study design, having a well-defined outcome measure is critical from many angles such as sample size calculation, statistical analysis, manuscript writing, journal of choice and finally, novelty and publication potential. So think long and hard about the outcome measure and define it well including how it will be actually measured, how it will be recorded and the unit in which it will be recorded.

## Step 3:

Communicate with biostatistician for sample size calculations and discussing study design and methodology. It is essential to bring in the expertise of a biostatistician at the start of the study, rather than after data collection. Remember that statisticians are not clinicians and are not able to understand terms as intuitively as a fellow clinician will. For e.g., progression of glaucoma is worsening of disease. However, for a statistician, progression could mean improvement since he is not aware of the disease process and terminology used. Hence, explain every column of your excel sheet to the statistician in as much detail as possible. Also explain the study hypothesis and the main outcome measure. These will go a long way in getting appropriate results quickly from your statistician.

## Step 4:

Collect data from all possible variables while conducting the study, including measurement of confounders. For example, think carefully about how you want to record follow up duration for your study (e.g. in days, months or years), how you want to record patient satisfaction (e.g.

very satisfied to not satisfied) if that matters etc. Always think about other factors that could influence the interaction between your intervention and your outcome. For example, you may conclude that drug A is better than drug B for a particular disease, however, it may be that drug A was used in much younger patients with milder disease and thus was erroneously labeled as a better drug. In this example, the patient age and disease status are confounders. Try to measure all possible confounders when you are starting the study itself.

#### Step 5:

Design a good Excel sheet and perform appropriate statistical analysis. Some cardinal rules for Excel sheet design are:

1. Use the first row to label the variables in short.
2. Do not enter alphabets anywhere in the excel sheet except the first row.
3. For categorical variable (such as Yes/No), label the categories with numerical (Yes=1, No=0). Categories – choose the comparison group as “0”
4. Use the “**Insert Comment**” option (by right clicking a box in Excel) to enter comments where needed and maintain a codebook showing how variables have been labeled.
5. De – identify patient data that can directly identify a patient.

6. Maintain consistency in units for the continuous variables (e.g. all follow up in months)
7. All Vision parameters always in logMAR
8. Right eye and Left eye as separate rows most of the times
9. Maintain ONLY one Excel sheet for the entire study
10. There should be ONLY One entry in one cell. Never as 1,2,3
11. No special features like hiding a column etc.
12. What to do with missing data? Enter a Dot (.) or 999

#### Step 6:

Manuscript writing using standardized checklists such as CONSORT, STROBE, RECORD and CARE depending on the type of your study. You can Google these terms and find these checklists and use them for free. I insist that you check this out and not miss out on non-negotiable items in your manuscript.

Following these steps will help you come up with an unbeatable study that will have high potential for publication in one of the high-ranking journals in your field. Importantly, repeating these steps in every study will mean that you will not have to remember them every time, just like you don't have to remember surgical steps every time. Lastly, you can explore extensive material and online courses on Sengupta's research academy to learn more about every aspect of clinical research.



# Mergers and Acquisitions (M&A) in Indian Ophthalmology - A Happy Marriage or a Painful Divorce?

- Dr Senthil Tamilarasan<sup>1</sup>

<sup>1</sup>Ophthall Practice Development



A 70-Year-old Ophthalmologist, who was practicing for 40 years, did not think of any exit options, he developed cancer and passed away within 6 months. He did not have Children who were Ophthalmologists or nor planned his exit before or valued his practice. So, after his passing away, what the family could get out of a thriving practice is just value of depreciated equipment's which they sold after much difficulty. We should understand that we are all mortal and our time in the earth is limited, so its important to plan our exit and understand what value our practice will get once we hit 60 + Years of Age.Though consolidation in healthcare practices have been very common in developed economies. In India the concept of Mergers and Acquisitions is relatively new. Heavily Private Equity Funded Corporate Eye Care chains aim to acquire more and more practices to grow.

In Indian Scenario a very small number of Practices got acquired – but unfortunately in the last decade most of them have not been Happy Marriages and resulted in a Painful Divorce. Solo Private Practitioners feel the pressure today due to increased competition from the Corporate Eye Hospitals, Charitable Organizations and Government Hospitals. Also running a Private Practice is becoming more and more complicated with regulatory, manpower issues and increasing patient demands. Many times, solo practitioners wonder why they have started a practice at all.The idea of merging with a corporate player comes to our mind occasionally. Let us discuss regarding the pros and cons of Merging or Getting acquired by a Larger Practice and what are the steps to be taken during this process. Please note that the following discussions are based on my opinion and interactions with finance professionals and Hospital owners. There may be differences in the assumptions.

## Which Practice is ideal to get acquired?

### Size Matters

Out of around 6000+ Private Ophthalmology Practices in India, only a very small percentage reach a good revenue scale. A larger corporate always wants to acquire a practice which has a decent revenue scale for them to justify the time spent in the deal. So, in terms of revenue a practice which has more than 3 Crores Annual Revenue been considered optimal for an Acquisition.

### Profit is paramount

Profit making practices are sought after for acquisition. Earnings before Interest, Depreciation, Taxes and Amortization is an important metric that is calculated on arriving at a valuation for acquisition. Most private practices in India are bootstrapped and have good

EBIDTA margins. 40%-50% EBIDTA is very common in solo practitioner Eye Hospitals. The company which acquires a practice wants to earn back the money invested in the acquisition in 4-5 years, hence profits is one of the most important parameters for a successful acquisition.

### Team Size

A good team is valued more. A good team of Ophthalmologists and support staff will fetch more value than a single practitioner alone with very small team. Corporates like a good team since they want to save the time spent on team building. Moreover, the same team can be used for expansion purposes.

### Regulatory Compliances and Accounting Practices

Its Important to have all regulatory compliances in

place and follow good accounting practices. If you want to get good valuation, make sure that there are no Compliance issues and maintain clean books of accounts, Fixed Asset Details etc. Most practices don't get acquired since the revenue they quote is not justified by their records (Income Tax Filings etc.)

Private Limited Companies are easier to acquire – than Partnerships etc.

### **Loans and Litigations:**

If the practice has large Loans are having involved in Litigations, medico legal cases, etc.- the valuation will decrease based on that.

### **Patient Data Maintenance and Others**

Remember- Data is everything. Practices which have accurate data of patients including total number of patients seen since inception, the contact details – and accessibility of the data through digital mode (Good EMR) etc. are valued more. Even having a Logo and good website matters to the acquirer.

### **The Keyman:**

The owner of the practice is the face of the organization and his capability and potential fetches the value. Since the practice is build based on the reputation of the owner, his commitment after the acquisition and for how long he will stay with the organization, also makes a lot of impact in the acquisition process and in the valuation.

### **When should you not think of getting acquired?**

#### **Children are Ophthalmologists:**

The most common exit Option for Ophthalmology Practices in India is Children taking over the practice. Hence if your children are Ophthalmologists and willing to take care of your practice, then that will be a best option for you. But I have been observing two common trends these days 1) Children of Doctors, not interested to take up Medicine as a career 2) Even of Children become Doctors, they do not want to take up Ophthalmology or settle in smaller towns. Hence these two factors play a major role in deciding your exit option.

### **Personality of the Practice Owner**

If you have a personality of not being able to work with a corporate or a larger organization, then it would be a difficult exercise to consider an acquisition. Since once you get acquired, the acquirer will want you to stay with them at least for 3-5 years to transition the practice. Many acquisition deals failed due to this.

### **The M and A Process**

Please note the M and A process is going to be grueling and time consuming and will involve multiple people and you must be prepared for this.

- 1) The process starts with Discussions between both parties and Internal discussions within both

organizations if they would like to get into the process.

- 2) Hiring of advisors, auditors, and legal experts by both organizations.
- 3) Signing of NDA.
- 4) Due Diligence and Practice Valuations.
- 5) Agreement on pricing and signing of a Letter of Intent.
- 6) Share Purchase agreements are drafted, and agreements are signed.
- 7) Financial Transactions are completed.
- 8) The Deal is closed.

### **Valuation:**

There is no thumb rule for the valuation, they say valuation is what the Buyer wishes to buy and what the seller wishes to sell for, there is no fixed amount.

- Generally, Eye Hospitals get a EBIDTA Multiple of 5-15 times for Good Will and Business.
- Keyman Ophthalmologist gets a market salary for the committed period the buyer wants him to work for.
- If building is owned- a market rental shall be worked on.
- Equipment's get a depreciated value.

The payment of the arrived valuation may be done in a staggered manner- 50% Upfront and balance in 3 Installments provided revenue milestones are reached and so on. There can be other models of payment also 100 % upfront, 75% upfront and so on. This purely depends on the buyer and seller.

Seller will have to sign a Non-Compete Agreement for X Number of Years

### **Pros of Merging with a Larger Practice**

- Smaller practice gets an exit option and do not have to close once the owner becomes old or does not have someone to take care of practice after him, besides having a good financial incentive on merging.
- The Ophthalmologist can focus more on clinical care while the managerial aspects are taken care by the Acquirer.
- Access to wider variety of specialists provides enhanced clinical care with a small practice merge with a larger organization.
- The smaller practice has access to a wider variety of advanced technologies available in a larger organization (Example Femto Lasik, Femto Cataract etc.)
- Economies of Scale- Smaller Practice get access to Purchase, Manpower etc. provided by the acquirer.
- Branding of the larger organization and marketing support shall provide larger number of patient base.
- Increased Compliances and Less Regulatory Headaches.



### Cons of Merging with a Larger Practice

- **Clash of Culture and Core Values-** Many Smaller practices feel there is a culture clash and clash on core values between the two organizations.
- Sometimes a Merger may create negative effect on patients, and patients feel that they have lost the personal touch which was earlier available with a smaller practice.
- The future of the smaller practice depends on the future of the larger practice – so both are tied up if larger entity does well- the smaller one also and can happen vice versa also.

### Are there any Alternatives?

Yes, there are other alternatives for smaller practices to grow- A common Management platform is something which would work well while smaller practices also retain their freedom. Ophthall Practice Development is one such platform wherein smaller practices can join as members and then access support of the platform to

- Engage common Marketing Agencies and share costs of Marketing.
- Engage Manpower in each geography for Insurance

Empanelment and Approvals.

- Start Common Diagnostic Centers in each geography.
- Create Common Knowledge database to patients in terms of websites etc.
- Create Common Standard Operating Protocols,
- Share Existing Resources among Members (OT, Equipment's etc.)
- Purchase Equipment's / Consumables in bulk and reduce costs of purchases.
- Create common funds which can inturn fund smaller practices.
- Create a Larger fund to Acquire Practices which want to exit. Acquisition by Doctors shall be better when compared to acquisition by a business entity

As a first step request you to become a Life member of Ophthall Practice Development Club , you will also get a free registration to the Ophthall Conference in Chennai in July and – we can meet network and discuss more on these ideas Link to Register

<https://www.ophthall.in/ophthall-practice-development>

**Please also share your opinions  
and feedback to me in  
my personal whats app  
+919840324333**

# Minimally Invasive Glaucoma Surgery (MIGS)

- Isabella V. Wagner <sup>1</sup>, Dr Cyril Doriraj <sup>2</sup>

<sup>1,2</sup> Department of Ophthalmology, Mayo Clinic, Jacksonville, Florida, USA

## Abstract

Traditional glaucoma surgery has been challenged by the advent of innovative techniques and new implants in the past few years. There is an increasing demand for safer glaucoma surgery offering patients a timely surgical solution in reducing intraocular pressure (IOP) and improving their quality of life. The new procedures and devices aim to lower IOP with a higher safety profile than fistulating surgery (trabeculectomy/drainage tubes) and are collectively termed “minimally invasive glaucoma surgery (MIGS).” The main advantage of MIGS is that they are nonpenetrating and/or bleb-independent procedures, thus avoiding the major complications of fistulating surgery related to blebs and hypotony. In this review, the clinical results of the latest techniques and devices are presented by their approach, ab interno (trabeculotomy, excimer laser trabeculotomy, trabecular microbypass, suprachoroidal shunt, and intracanalicular scaffold) and ab externo (canaloplasty, Stegmann Canal Expander, suprachoroidal Gold microshunt). The drawback of MIGS is that some of these procedures produce a limited IOP reduction compared to trabeculectomy. Currently, MIGS is performed in glaucoma patients with early to moderate disease and preferably in combination with cataract surgery

**Keywords** -Minimally invasive glaucoma surgery, open angle glaucoma, trabecular microbypass, ab-interno canaloplasty, trabeculectomy, suprachoroidal, subconjunctival

## What is minimally invasive glaucoma surgery?

Given the limited success profile of current treatments, MIGS has become increasingly popular as a form of treatment for glaucoma. There are numerous MIGS approaches, including: (1) increasing flow through the trabecular meshwork and Schlemm’s canal; (2) directing flow through the supraciliary space; (3) directing aqueous outflow to the subconjunctival space; and (4) reducing the production of aqueous fluid at the ciliary processes.

All of these methods share some common features including an ab-interno approach which spares incision of the sclera, leading to a more favorable side effect profile compared with some other traditional pressure lowering procedures such as trabeculectomy or ab-externo drainage devices. However, one important distinction is that MIGS generally leads to a smaller reduction in intraocular pressure (IOP) than more invasive approaches, and for this reason it is important to consider the individual patient needs prior to deciding upon the glaucoma management.

In this study a literature review was performed, assessing the different types of MIGS procedures and providing an overview of their comparable efficacy in an effort to inform clinical decision making and bring attention to the variety of MIGS available.

Overview of current glaucoma procedures with MIGS.

Surgical Approach	Internal Filtration	External Filtration
Ab Interno	Trabeculotomy (Trabectome, Excimer Laser)	Subconjunctival implant (Aquesys)
	Trabecular micro-bypass (iStent), Suprachoroidal stent (Cypass)	
	Intracanalicular scaffold (Hydrus)	
Ab Externo	Canaloplasty Stegmann Canal Expander	
	Suprachoroidal Gold micro shunt	

## The different types of MIGS approaches

### MIGS aimed at improving outflow through Schlemm’s canal

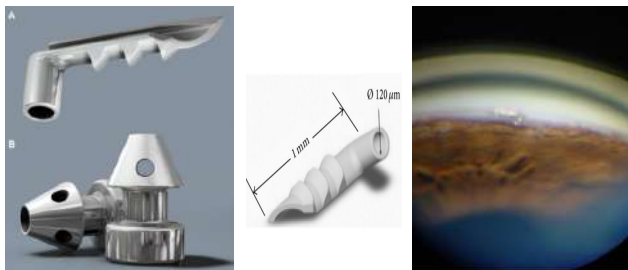
#### *iStent and iStent inject: Mechanism of action*

The iStent and iStent inject (Glaukos Inc, Laguna Hills, CA, USA) are first and second generation trabecular microbypass stents, aimed at improving outflow of aqueous humor through the trabecular meshwork into Schlemm’s canal (both pictured in [Figure 1](#)).<sup>1</sup>

Both are made of heparin coated titanium, and while the iStent is 1 mm × 0.3 mm in size, the iStent inject is significantly smaller at only 360 μm × 230 μm in size. Both are inserted using a disposable implantation device

through a clear corneal incision as a single procedure or in combination with cataract extraction, and in the case of iStent inject 2 devices are loaded into the injector and can be placed at 30°-60° apart. Both devices are usually followed up with a 4-week course of topical anti-inflammatory and anti-infective medication to reduce the risk of surgical complications.<sup>2</sup>

Generally, iStent or iStent inject is indicated in mild to moderate glaucoma with the aim to reduce dependence on topical medications and/or to reduce IOP. These trabecular microbypass devices have an advantage in that they are very small devices, and so are unlikely to cause endothelial damage in patients with shallow anterior chambers.



**Figure 1. First generation iStent trabecular microbypass stent (A). Second generation iStent inject trabecular microbypass stent (B).**

### iStent and iStent inject: Effectiveness

Hooshmand *et al.*<sup>1</sup> found that iStent and iStent inject (both combined with phacoemulsification) had comparable effectiveness in practice, with their study of 145 eyes with primary OAG showing 56.0% of the iStent and 51.3% of the iStent inject eyes achieved an IOP value of  $\leq 18$  mmHg and were medication free at 12 months. In a randomized prospective trial conducted by Samuelson *et al.*<sup>3</sup>, iStent inject with phacoemulsification was compared with phacoemulsification alone in terms of safety and efficacy. The proportion of eyes that had achieved an IOP reduction of  $\geq 20\%$  from baseline at 24-month follow-up was 75.8% in treatment eyes compared with 61.9% of eyes in the control group. 84% of treatment eyes compared with 67% of control eyes were medication free at the 23-month follow-up.<sup>3</sup>

It has also been demonstrated in an RCT by Katz *et al.*<sup>4</sup> that increasing the number of iStent devices implanted as a standalone procedure leads to an increased treatment effect. Whilst all patients in this trial were taking between one to three topical medications pre-implantation, all were taken off post-operatively, and in the 1-iStent group 18/38 participants required the addition of a topical medication by 42 months, compared with 4/41 in the 2-iStent group and 3/40 in the 3-iStent group.<sup>4</sup>

iStent trabecular microbypass devices have also demonstrated efficacy in secondary OAG. In one 24-eye study of iStent in combination with phacoemulsification in pigmentary glaucoma there was a reduction in IOP from  $19.50 \pm 6.7$  mmHg at baseline to  $14.68 \pm 3.0$  mmHg

( $P < 0.01$ ) at 36 months in addition to a reduction in medications from  $0.75 \pm 1.0$  topical medications to  $0.59 \pm 0.6$  ( $P > 0.05$ )<sup>5</sup>. Pseudoexfoliation glaucoma was also investigated by Ferguson *et al.*<sup>6</sup>, with iStent implantation in combination with phacoemulsification in 115 eyes leading to a statistically significant reduction in mean IOP and topical medication usage at 2 years. No studies were identified that solely investigated iStent or iStent inject in steroid induced glaucoma.

### iStent and iStent inject: Safety profile

Samuelson *et al.*<sup>3</sup> reported the overall adverse events to be less frequent in the intervention group who received iStent and

Frequency of microbypass stent complications.	
Type	Frequency in %
Mild hyphema	0-70
Transient IOP spike	0-30
Corneal edema	0-20
Transient IOP spike	0-21
Stent obstruction	4-14.9
AC collapse	0-2.3
Inability to implant stent	0-2.3
Vitreous incarceration	0-2.3
Stent malposition	0-21.4
Secondary surgery	0-4.5

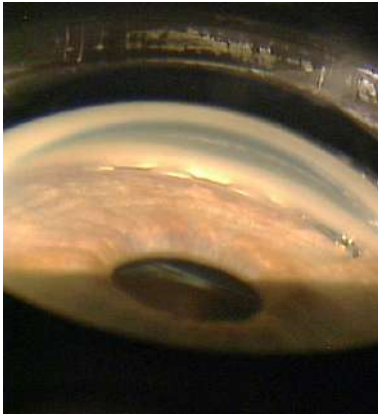
phacoemulsification (54.1%) vs. the control group (who only received cataract extraction) (62.2%), and the majority of these were minor complications, the most common being ocular surface disease, stent obstruction, intraocular inflammation, secondary surgical inflammation, and ocular allergies. Of those who had stent obstruction ( $n = 24$ ), 3 had a laser revision to clear the blockage and these were all successful.<sup>3</sup>

### Hydrus: Mechanism of action and effectiveness

The Hydrus microstent (Ivantis inc, Irvine, CA, USA) is an 8-mm intracanalicular scaffold that dilates an entire 90° quadrant of Schlemm's canal to increase aqueous humor flow through the trabecular meshwork (displayed in [Figures 2](#) and [3](#)). The Hydrus implant is introduced in a fashion similar to other trabecular microbypass stents, through a clear corneal incision with phacoemulsification or as a single procedure, and with the application of a topical corticosteroid and antibiotic solution during the post-operative period. The indication for Hydrus is mild to moderate glaucoma with the aim of reducing dependence on topical medication and to control IOP within a suitable target.<sup>2</sup>



**Figure 2. Hydrus microstent (Ivantis inc, Irvine, CA, USA). (A) diagram of the Hydrus microbypass stent with the anterior chamber forward. (B) is an image of the posterior chamber. Image copyright of Ivantis, Inc.**



**Figure 3.** Hydrus microstent (Ivantis inc, Irvine, CA, USA) viewed gonioscopically in position in the canal of Schlemm. The device is partially obscured by the overlying trabecular meshwork. Image copyright of Ivantis, Inc.

The efficacy of Hydrus in combination with phacoemulsification compared to phacoemulsification alone was investigated in the recent HORIZON study by Samuelson *et al.* In this 369-eye study, an unmedicated IOP reduction of > 20% was achieved in 77.3% of Hydrus eyes compared with 57.8% of control eyes at 24 months. There was a mean reduction of  $7.6 \pm 4.1$  mmHg in the Hydrus group and  $5.3 \pm 3.9$  mmHg in the phacoemulsification alone group. Mean medication burden was reduced from  $1.7 \pm 0.9$  pre-operatively (baseline value in both intervention and control was equivalent) to  $0.3 \pm 0.8$  in the Hydrus group and to  $0.7 \pm 0.9$  in the phacoemulsification alone group.<sup>3</sup>

Hydrus was also investigated as a head-to-head comparison with 2 first-generation iStent (both performed following uncomplicated cataract surgery) in the COMPARE trial, a 152-patient randomised clinical trial by Ahmed *et al.*<sup>7</sup> It was concluded in this study that Hydrus reduced IOP at 12 months by  $1.7 \pm 4.0$  mmHg compared with a reduction of  $1.0 \pm 4.0$  mmHg in the 2-iStent group, a difference of 0.7 mmHg (95%CI: -2.0-0.7). Medication reduction was also greater as Hydrus achieved a reduction of  $1.6 \pm 1.2$  medications vs.  $1.0 \pm 1.2$  in the 2-iStent group, a difference in 0.6 medications (95%CI: 0.9-0.2). Interestingly, Hydrus was able to achieve a  $\geq 20\%$  IOP improvement in 39.7% of patients compared with only 13.3% in the 2-iStent group and was able to achieve 30.1% in the  $\leq 18$  mmHg category compared with only 9.3% in the 2-iStent group.<sup>7</sup>

### Hydrus: Safety profile

Adverse events were roughly comparable between both of the groups in the COMPARE trial in terms of BCVA loss, IOP spikes, new cataracts and device obstruction. 2 patients in the Hydrus ( $n = 74$ ) and 1 in the 2-iStent ( $n = 76$ ) experienced a BCVA loss of > 2 lines at 12 months, and IOP spikes of > 10 mmHg were seen in 3 patients in the Hydrus group and 4 patients in the 2-iStent group. New cataracts were seen in 2 patients in the Hydrus group and in 1 patient in the 2-iStent group and device obstruction due to any cause was seen in 9 of the Hydrus and 10 of the 2-iStent patients.

Safety of the Hydrus microstent was generally reflective of the safety of other trabecular microbypass devices. There was also no need for any incisional glaucoma surgery

in the Hydrus group compared with in the 2-iStent group, where 2 patients (of 76 in that group) required a secondary trabeculectomy and 1 patient required a cataract surgery.<sup>7</sup>

### Ab-interno canaloplasty: Mechanism of action and efficacy

Ab-interno canaloplasty (ABiC) is a procedure where a microcatheter such as the iTrack device (Ellex Medical Lasers Pty Ltd, Adelaide, Australia) is used to perform 360° viscodilation of Schlemm's canal, without the requirement for suturing. This acts to reduce IOP by dilating the canal of Schlemm and downstream collector channels to improve aqueous outflow. The indication for ABiC in mild to moderate glaucoma is either as a solo procedure or in combination with other forms of trabecular microbypass devices to facilitate further dilation of the collecting channels, and greater outflow than would be achieved with these devices alone, a similar principle to other non-implantation techniques specifically targeting improved outflow through Schlemm's canal.

ABiC has been evaluated as both a sole procedure in phakic eyes and in combination with cataract surgery by Davids *et al.*<sup>8</sup> In one study of 36 eyes (20 pseudophakic and 16 phakic) a reduction in mean IOP was seen from  $19.8 \pm 4.1$  mmHg pre-operatively to  $13.8 \pm 3$  mmHg 12 months post-operatively across the 2 groups<sup>8</sup>. There was, however, no statistically significant reduction in the number of medications during this period, which stabilized at  $2.1 \pm 1.6$  ( $P = 1.0$ ). This would be an important point to include when counselling patients about ABiC as a sole procedure.<sup>8</sup>

ABiC also has the potential to be used as a combination therapy with other forms of MIGS. Heersink *et al.*<sup>9</sup> explored this concept in their 186-eye retrospective study comparing iStent and cataract surgery with iStent, ABiC and cataract surgery. The results showed a clear favorability for the IOP-lowering effects of iStent with ABiC and phacoemulsification, as this group achieved a mean IOP reduction of  $2.9 \pm 3.6$  mmHg compared with  $1.7 \pm 3.1$  mmHg in the iStent and phacoemulsification groups alone. The percentage of patients achieving treatment success (a final IOP of  $\leq 18$  mmHg and a mean reduction in IOP of > 20%) was 46% in the combined group compared with 35% in the trabecular microbypass and cataract surgery alone group. In terms of medication, 56% of patients in the combined group were off all medications compared with 48% in the control group, a mean reduction of 0.9 and 0.7, respectively.<sup>9</sup>

It is likely that ABiC would be an effective procedure to combine with existing trabecular microbypass methods. As a sole procedure it is also effective at lowering IOP; however, it has showed limited efficacy in medication reduction so far and this will need to be taken into account when considering its use in patients with a high medication burden.

### Ab-interno canaloplasty: Safety profile

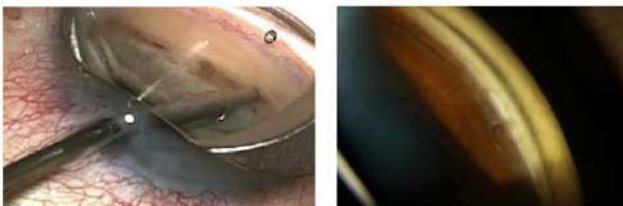Safety appears to be favorable, and according to

Heersink *et al.*<sup>9</sup>, inflammation was the most common adverse event in the combined group and occurred in 6% of participants, while loss of visual acuity was the most common adverse event in the control group, occurring in 8% of participants.

### Trabectome: Mechanism of action and efficacy

Trabectome or ab-interno trabeculectomy achieves an increase in aqueous humor outflow through the trabecular meshwork by applying a 0.8 W electrical current in order to ablate the trabecular meshwork. Access to the anterior chamber is achieved through a clear corneal incision and gonioscopy is used intraoperatively to visualise the trabecular meshwork. Trabectome and ABiC are significantly differentiated from the other trabecular microbypass techniques, as no indwelling devices are left in the eye after the operation. Esfandiari *et al.*<sup>10</sup> demonstrated the efficacy of Trabectome when compared against iStent implantation (both with phacoemulsification), and after 24 months a mean IOP of  $13.9 \pm 3.3$  mmHg was achieved in Trabectome patients ( $n = 154$ ) compared with  $16.8 \pm 2.8$  mmHg in iStent ( $n = 110$ ) from a baseline of  $15.3 \pm 3.1$  mmHg in both groups. Medication burden was  $0.7 \pm 1.0$  and  $1.7 \pm 1.2$  in the trabectome and iStent groups, respectively, at 24 months. In addition, the proportion of eyes with an unmedicated IOP of  $\leq 21$  mmHg was 53% and 16.6% in the trabectome and iStent eyes, respectively.<sup>10</sup>

Trabectome has also demonstrated efficacy in pseudoexfoliative glaucoma. Avar *et al.*<sup>11</sup> investigated Trabectome performed on patients either as a solo procedure or with concomitant cataract extraction (in combined data) described a significant IOP lowering effect in 28% of patients with POAG and 26% with pseudoexfoliative glaucoma, as well as a significant medication reduction in 32% and 29%, respectively. The median follow-up period in this study was 3.5 years.<sup>11</sup>



Frequency of reported Trabectome complications.

Type	Frequency in %
Hyphema	0–59
Goniosynechiae	0–14
Corneal epithelial defects	0–3
IOP spike	0–5
Iris and lens touch	0–1.3
Infection	0
Bleb formation	0
Wound leaks	0
Choroidal effusion	0
Choroidal hemorrhage	0

### Gonioscopy assisted transluminal trabeculotomy

Gonioscopy assisted transluminal trabeculotomy (GATT) is a procedure where a circumferential trabeculotomy is performed of

the trabecular meshwork, by running a suture the entire length of Schlemm's canal, retrieving and pulling the distal tip while applying traction to the proximal end of the suture. A study of XEN compared with GATT (both with or without cataract extraction, in combined data) showed that IOP was reduced from  $24.9 \pm 5.8$  mmHg to  $15.3 \pm 3.8$  mmHg at 24 months post-operatively, and medications were reduced from  $3.3 \pm 0.6$  to  $1.2 \pm 0.4$ . This is compared to a reduction in IOP from  $24.4 \pm 4.3$  mmHg to  $14.2 \pm 2.2$  mmHg at 24 months and medication reduction from  $3.4 \pm 0.5$  to  $2.0 \pm 2.2$  over the same period for the XEN gel stent. Transient hyphaema was the most common post-operative complication following GATT, occurring in 28% of patients.<sup>12</sup>

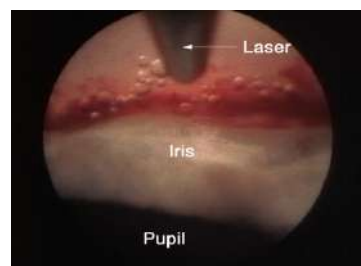
### Excisional goniotomy

Excisional goniotomy or trabeculectomy facilitates increased aqueous outflow by utilizing a device such as the Kahook Dual Blade (KDB, New World Medical, Rancho Cucamonga, CA) to incise the trabecular meshwork and in theory avoid the thermal damage associated with Trabectome or leaving remnant trabecular meshwork leaflets in-situ such as with GATT. In a 315-eye study comparing both iStent and Kahook Dual Blade in combination with phacoemulsification found that the mean IOP reduction at 12 months was 5.0 mmHg compared with 2.3 mmHg in the iStent group ( $P < 0.001$ ) and mean medication reductions were similar in both groups with 1.03 and 0.97 in the Kahook Dual Blade group and the iStent group, respectively. Transient IOP elevation and transient anterior chamber inflammation were the most complications following KDB, both occurring in 1% of patients.<sup>13</sup>

### Excimer Laser Trabeculotomy

Ab interno excimer laser trabeculotomy (ELT) (Glautec AG, Nurnberg, Germany) utilizes the energy of a xenon chloride pulsed excimer laser connected to a quartz fiber optic probe. The procedure intends to enhance outflow facility by creating microperforations in the TM and inner wall of SC. The probe tip is beveled at 65 degrees to aid the placement against the angle via gonioscopic or endoscopic guidance. Eight to ten laser punctures are spaced over 90 degrees, each pulse delivering a mean energy of 1.2 mJ over 80 ns duration. Presence of blood reflux following the laser ablation means that SC has been accessed.

With ELT, Intraocular pressure lowered from  $24.8 \pm 2.0$  to  $16.9 \pm 2.1$  mmHg in POAG refractory to topical medication after a mean follow-up of 2 years. Overall, 90.5% of the patients had an IOP reduction of  $\geq 20\%$  compared to baseline. Eight patients (38.1%) required additional medical therapy to achieve IOP control, and 9.5% failed the treatment.<sup>14</sup>



**SLT vs ELT-** No statistically significant differences in complete or qualified success rates between the two groups at 24 months were found, although the percentage of IOP reduction was slightly higher in the SLT than in the ELT group (29.6% versus 21%).<sup>15</sup>

**ELT vs Phaco+ ELT-** Patients treated only with ELT achieved an IOP reduction of 30% ( $24.1 \pm 0.7$  mmHg to  $16.8 \pm 1.0$  mmHg), while patients treated with the combined procedure had a decrease in IOP of 47% ( $22.4 \pm 0.6$  mmHg to  $12.8 \pm 1.5$  mmHg) at last follow-up. Antiglaucomatous drugs dropped from  $1.9 \pm 0.1$  to  $1.5 \pm 0.3$  in the ELT alone group, but paradoxically increased from  $1.1 \pm 0.2$  to  $1.8 \pm 0.9$  in the combined group.<sup>16</sup>

ELT has been described as simple and quick procedure only requiring topical anesthesia. Reported advantages are a low incidence of complications and no interference with future fistulating surgery if needed. A slight bleeding is expected during the procedure and may even be interpreted as patency of the TM with a good prognosis regarding IOP reduction. However, IOP increase in the first 24 hours and fibrin reaction may also be seen following ELT. Further, ELT requires expensive equipment and experience from the surgeon working with a direct view gonio lens.

### **MIGS aimed at creating an outflow channel to the supraciliary space**

**Mechanism of action, effectiveness, and safety profile.**

#### **CyPass: Mechanism of action and efficacy**

CyPass (Transcend Medical Inc, Menlo Park, CA, USA) was a tubular stent which aimed to reduce IOP by shunting fluid through a passage into the supraciliary space. It was performed through a clear corneal incision, and the stent is placed inferior to the trabecular meshwork and advanced into the suprachoroidal space. CyPass had proven efficacy in the COMPASS trial which compared CyPass combined with phacoemulsification to phacoemulsification alone. It was shown that at 2 years, patients who had received the CyPass microstent had a mean reduction in IOP of  $7.4 \pm 4.4$  mmHg (30%) compared to  $5.4 \pm 3.9$  mmHg (21%) in the control group ( $P < 0.001$  for CyPass microstent vs. control). A reduction from baseline values of  $17.0 \pm 3.4$  mmHg and  $19.3 \pm 3.3$  mmHg, respectively. This efficacy was also shown in the reduction in medications, as medications at 2 years had dropped from  $1.4 \pm 0.9$  to  $0.2 \pm 0.6$  in the CyPass group and from  $1.3 \pm 1.0$  to  $0.6 \pm 0.8$  in the control group. At 2 years 85% of CyPass recipients had maintained their IOP with no medications, compared to 59% in the phacoemulsification alone cohort.<sup>17</sup>

CyPass has also been compared with iStent in a head-to-head meta-analysis by Fard *et al.*<sup>18</sup>, and in that study, they showed that CyPass alone (without phacoemulsification) was a more effective intervention for reducing IOP than either 1 or  $\geq 2$  iStents with or without phacoemulsification, but both techniques were comparable in terms of medication reduction.

#### **CyPass: Safety concerns**

The COMPASS XT study was an extension of the original 24-month study for an additional 36 months to assess the safety of the stent. This study showed comparable safety between the study and control groups, and while there were 2 sight threatening complications in the CyPass group compared with only one in the control group, these were deemed to be unrelated to the stent. Despite this, evidence was found for increased corneal endothelial cell loss compared with the group that underwent phacoemulsification alone, and due to this it was announced in August 2018 that it would be voluntarily removed from the market by Alcon due to the potential risks, with the potential for reintroduction in the future.<sup>19</sup>

#### **iStent Supra: Mechanism of action, effectiveness, and safety profile**

iStent Supra (Glaukos Inc, Laguna Hills, CA, USA) is currently an experimental microbypass stent which also harnesses the uveoscleral pathway similarly to CyPass. Myers *et al.*<sup>20</sup> evaluated iStent Supra in combination with 2 iStents and post-operative Travoprost for the treatment of refractory open angle glaucoma following trabeculectomy and maximal medical therapy. The pre-operative mean medicated IOP was  $22.0 \pm 3.1$  mmHg, with  $1.2 \pm 0.4$  medications on average. The post-operative mean medicated IOP at 48 months was  $\leq 13.7$  mmHg ( $12.9 \pm 0.9$  mmHg at month 48) and unmedicated mean IOP was  $18.4 \pm 1.4$  mmHg at month 49 (post-washout). The safety profile of the suprachoroidal stent was favorable, and throughout the 48-month follow-up no patients required additional glaucoma surgery.<sup>20</sup>

Assessing the efficacy of iStent supra in this form of study alone is challenging, as there are confounding variables in the form of the 2 iStent devices, and the effects of the topical Travoprost. Further studies to determine the efficacy of iStent supra would be beneficial, preferably in the form of randomized controlled studies, and in comparison, with other methods or in combination with phacoemulsification.

#### **MIGS targeted at the subconjunctival space**

**Mechanism of action, effectiveness, and safety profile.**

#### **Xen: Mechanism of action and effectiveness**

The XEN gel implant (Allergan inc, Irvine, CA, USA) was a form of MIGS targeting aqueous outflow to the subconjunctival space; however, in November 2019, Allergan Australia Pty Ltd. announced that there would be a voluntary global recall of all un-implanted XEN units due to a portion of them failing quality control. They did not recommend the explantation of implants that had already been placed.<sup>21</sup>

The XEN gel stent was implanted into the trabecular meshwork with a needle through an ab-interno approach, which was then advanced to puncture the sclera entirely and pass the flexible stent into the sub-

conjunctival space. This then creates a channel for aqueous humour outflow and creates an internal bleb to reduce IOP. XEN was indicated for moderate to advanced glaucoma, as it was a bleb-based procedure with the associated risks/complications associated with this. Karimi *et al.*<sup>22</sup> investigated the efficacy of XEN alone or in combination with phacoemulsification with a 259 eye consecutive case series. The results showed that mean IOP (of both groups combined) was reduced from  $19.3 \pm 6.0$  mmHg at baseline to  $13.5 \pm 3.3$  mmHg at 18-month follow-up, and medications were reduced from  $2.6 \pm 1.1$  to  $1.1 \pm 1.3$  at 18 months. It was also interesting to note that simultaneous cataract extraction or solo stent implantation did not significantly impact outcomes, as these groups had an IOL of  $13.8 \pm 2.6$  mmHg and  $14.3 \pm 4.7$  mmHg at 12-month follow-up, respectively ( $P = 0.5367$ ).<sup>25</sup>

As a form of bleb forming procedure, it is also important to compare the XEN gel stent with trabeculectomy, which is still the predominant incisional procedure for glaucoma. Wagner *et al.*<sup>26</sup> compared the 2 as standalone procedures performed in a 171-eye study, which demonstrated that complete surgical success at 12 months post-operative follow-up was higher in the trabeculectomy group at 65.5% (95%CI: 55.6%-75.9%) compared with the XEN gel stent group at 58.5% (95%CI: 47.6%-69.4%). There was however no significant difference between both groups' surgical outcomes ( $P = 0.16$ ). In addition, an IOP reduction at 12-month follow-up of  $7.2 \pm 8.2$  mmHg in the XEN group and  $10.5 \pm 9.2$  mmHg in the trabeculectomy group were observed from baseline values of 19.0 mmHg (95%CI: 16.8-25.0 mmHg) and 21.0 mmHg (95%CI: 17.0-27.0 mmHg), respectively ( $P = 0.003$ ). Medication reduction was also reduced to  $0.3 \pm 0.5$  and  $0.2 \pm 0.4$  in the XEN and trabeculectomy cohorts, respectively from baseline values of 2.0 (95%CI: 1.0-3.0) and 3.0 (95 CI: 2.0-4.0), respectively.<sup>26</sup>

The XEN gel stent was also shown to have comparable efficacy in other secondary forms of open angle glaucoma, including pseudo exfoliation glaucoma as demonstrated by Gillmann *et al.*<sup>21</sup>, where 110 eyes with either pseudoexfoliative OAG or POAG underwent either XEN as a standalone or with cataract surgery (with data combined). In this study the mean medicated IOP was  $14.2 \pm 3.8$  mmHg (a 28.3% reduction) in the pseudoexfoliative group compared with  $14.5 \pm 3.6$  mmHg (a 26.8% reduction) in the POAG group after 2 years, a reduction from  $19.8 \pm 8.2$  mmHg and  $19.8 \pm 5.8$  mmHg respectively. Medication reduction was also comparable, with a drop from  $2.0 \pm 1.3$  to  $0.4 \pm 0.7$  in pseudoexfoliation glaucoma and from  $1.9 \pm 1.6$  to  $0.6 \pm 0.9$  in POAG. Success rates were not different to a statistically significant degree, and the rate of adverse effects and rates of needling were similar in both groups (42.8% POAG vs. 43.2% pseudoexfoliative).<sup>24</sup> There were no studies showing evidence of the efficacy of the XEN implant in pigmentary or steroid induced glaucoma.

### **Xen: Safety profile**

Important to note is that 40.9% of cases required post-

operative management including bleb needling or the administration of an antimetabolite injection, and adverse events included IOP spikes of  $\geq 30$  mmHg (12.7%), follow-up glaucoma filtration surgery (9.3%), and exposure of the implant (2.3%), as well as some cases of persistent hypotonous maculopathy, persistent choroidal effusions, a cyclodialysis cleft, and endophthalmitis following bleb resuturing.<sup>22</sup> This is partially to be expected with a bleb forming operation and reflects the safety profile of this class of procedure.

### **Preserflo microshunt: Mechanism of action, effectiveness, and safety profile**

The Preserflo microshunt (Santen Inc, Emeryville, CA, USA) previously known as the InnFocus microshunt aims to address the need for a form of MIGS that can be effectively applied to moderate to severe glaucoma. The Preserflo device is implanted into the subconjunctival space below Tenon's capsule via an ab-externo approach and threaded through a needle tunnel into the anterior chamber. The biocompatible material of the Preserflo tube (SIBS) in combination with intraoperative Mitomycin C is used to reduce the risk of scarring and fibrosis. Sadruddin *et al.*<sup>25</sup> showed in a 23 patient post-market study of Preserflo with and without phacoemulsification, a reduction from the mean baseline IOP in both groups of  $23.8 \pm 5.3$  mmHg (26.4 mmHg in phacoemulsification combination group vs. 22.1 mmHg for Preserflo alone) to  $10.7 \pm 3.5$  mmHg at 3-years follow-up (10.2 mmHg with phacoemulsification vs. 11.1 mmHg for Preserflo alone). Medication reduction was 71% overall at 3 years, and 64% of participants no longer required topical glaucoma medications.<sup>25</sup>

Transient hypotony, shallow anterior chambers and the device touching the iris occurred in 13% of patients individually, while transient choroidal detachment, hyphema and exposed Tenon's capsule were also common adverse events occurring in 9% of patients respectively. All of these issues resolved spontaneously within 3 months of surgery being performed.<sup>25</sup> There is currently a lack of randomized control trials on the efficacy of Preserflo, however one RCT is in progress and with more high-level evidence the safety and efficacy of this novel method will be made increasingly clear in order to establish it as a viable option in OAG management.

### **MIGS targeting the ciliary process**

#### **Endocyclophotocoagulation: Mechanism of action, effectiveness and safety profile**

Endocyclophotocoagulation (ECP) is a procedure that can be performed in conjunction with phacoemulsification for refractory glaucoma and aims to reduce the production of aqueous humor by the ciliary processes by shrinking these using a directed laser. ECP is generally indicated in end-stage glaucoma. Pantaloni *et al.*<sup>26</sup> have demonstrated the efficacy of ECP through conducting a 12-month retrospective study with patients receiving either 2 iStents, with concurrent ECP and cataract extraction, or

phacoemulsification and 2 iStents alone. The ECP procedure proved efficacious in reducing IOP from a baseline value of  $19.97 \pm 4.31$  mmHg to  $13.05 \pm 2.18$  mmHg (a 35% reduction) compared with  $17.63 \pm 3.86$  mmHg to  $14.09 \pm 1.86$  mmHg (a 21% reduction) in the phacoemulsification and 2 iStent alone group. Medications were also reduced from  $2.22 \pm 1.6$  to  $1.24 \pm 1.05$  in the ECP group and from  $2.07 \pm 1.02$  to  $1.39 \pm 1.03$  in the phaco-iStent alone group, a comparable reduction in both, and safety results were also comparable. These results appear promising for the utilization of ECP as a combined procedure with other MIGS and cataract surgery.<sup>26</sup> There is, however, limited knowledge of the safety profile of ECP due to the lack of high-level evidence in the form of randomized controlled trials. One study, currently in the data collection phase, is investigating patients with POAG receiving either ECP with phacoemulsification or phacoemulsification as a standalone procedure.<sup>27</sup>

### MicroPulse Transscleral Laser Therapy (MP-TLT):

Mechanism of action, effectiveness and safety profile

MicroPulse Transscleral Laser Therapy (MP-TLT) is an updated method of cyclophotocoagulation involving use of a diode laser to deliver short, cycled pulses of 810nm infrared radiation to the ciliary body epithelium, with “off” intervals to maintain structural integrity and minimize damage to the surrounding tissues.<sup>28</sup> Laser delivery is achieved with the MicroPulse P3 probe (Iridex Corporation, Mountain View, CA), which includes the first-generation

700- $\mu$ m fiberoptic device (2000mW power), or the recently released second-generation 600- $\mu$ m fiberoptic device (2500mW power), both of which are typically used at aduty cycle of 31.33%.

While there are no published studies evaluating efficacy of the second generation P3 probe, there are various studies detailing the effects of MP-TLT with the first-generation probe. In particular, Marchand et al evaluated MP-TLT in patients with uncontrolled glaucoma over 18 months follow-up. IOP was moderately reduced from  $23.6 + 6.5$  mmHg to  $15.2 + 4.1$  mmHg (a 35.6% reduction), and a good safety profile was demonstrated, with only 2 patients (4%) sustaining a persistent visual loss of  $\geq 2$  lines.<sup>29</sup> Similarly, in a sample of mild to severe glaucoma patients receiving MP-TLT, Elgwaity et al observed IOP and medication reductions of 35.9% and 34.6% respectively, with no complications persisting in any eyes at 6 months.<sup>30</sup> When compared to older methods, MP-TLT has been found to produce a comparable IOP-lowering efficacy coupled with an improved safety profile. For instance, when compared to continuous-wave transscleral cyclophotocoagulation (CW-TSCPC) over 12 months, Bernadina and Töteberg-Harms found MP-TLT to achieve a comparable success rate (IOP between 6-19 mmHg and IOP reduction  $\geq 20\%$ ) [MP-TLT: 87.5%; CW-TSCPC: 88.6%;  $P=0.883$ ], although CW-TSCPC did lower IOP (MP-TLT: 31.1%; CW-TSCPC: 42.4%) and medications (MP-TLT: 7.14%; CW-TSCPC: 33%) by a higher percentage.<sup>31</sup> Regardless, MP-TLT appears to be a promising treatment

TABLE. COMPARISON OF CURRENT MIGS OPTIONS\*

	FDA Approval or Expected	CE Mark Approval	Implanted Device	TM Destruction	Degree of TM Treated Through 1 Incision	FDA Approved for Use Alone and With Cataract Extraction	IOP Reduction (Stand-Alone Procedure)	Medication Reduction (Stand-Alone Procedure)	IOP Reduction (When Combined With Phacoemulsification)	Medication Reduction (When Combined With Phacoemulsification)	
Trabecular Meshwork	iStent	✓	✓	✓					8%-17.3% 1 stent, 20%-27% 2-3 stents at 12 mo	80%-88% 1 stent, 64%-91% 2-3 stents at 12 mo	
	iStent Inject		✓	✓			29%-48% at 12 mo	47%-60% at 12 mo			
	Trabectome	✓	✓		✓	60-120	✓	29%-44% at 6 to 30 mo	21%-59% at 6 to 30 mo	16%-35% at 12 mo	31%-48% at 12 mo
	Hydrus Microstent	2018	✓	✓		90	✓			50% washed out IOP at 24 mo	75% washed out at 24 mo
	Trab360	✓	✓		✓	180-360	✓	32% at 4 mo	82% at 4 mo		
	Visco360	✓	✓			180-360	✓				
	GATT	✓	✓		✓	360	✓	39% at 12 mo	53% at 12 mo	35% at 12 mo	48% at 12 mo
	ABC	✓	✓			360	✓	37% at 12 mo	67% at 12 mo	23% at 12 mo	50% at 12 mo
Supraciliary	Kahook	✓	✓	✓	✓	60-120	✓				
	CyPass Micro-stent	✓	✓	✓			35% at 12 mo	36% at 12 mo	35% at 12 mo	49%-75% at 12 mo	
Subconjunctival	iStent Supra	2018	✓	✓			47%-50% at 13 to 18 mo	98% discontinued at least 1 medication			
	Xen	2016	✓	✓			40% at 36 mo <sup>b</sup>	74% at 36 mo <sup>b</sup>	See footnote <sup>b</sup>	See footnote <sup>b</sup>	
	InnFocus MicroStent	2018	✓	✓			55% at 36 mo <sup>c</sup>	64% at 36 mo with no medications <sup>c</sup>	See footnote <sup>c</sup>	See footnote <sup>c</sup>	

Abbreviations: MIGS, microinvasive glaucoma surgery; GATT, gonioscopy-assisted transluminal trabeculotomy; ABC, ab interno canaloplasty; TM, trabecular meshwork. Manufacturing information: iStent, iStent Inject, and iStent Supra (Glaukos); Trabectome (NeoMedix); Hydrus Microstent (Ivantis); Trab360 and Visco360 (Sight Sciences); Kahook Dual Blade (New World Medical); CyPass Micro-Stent (Alcon); Xen (Allergan); InnFocus MicroStent (InnFocus).  
<sup>a</sup>Data from Richter GM,<sup>8</sup> Junemann A,<sup>10</sup> white paper,<sup>12</sup> Reitsamer H,<sup>13</sup> Sarkisian S.<sup>14</sup>  
<sup>b</sup>Results include all versions of the Xen gel stent. Data for stand-alone procedure and combined procedure showed no statistically significant difference.  
<sup>c</sup>Data include grouped outcomes of stand-alone procedures and procedures combined with phacoemulsification. These results cannot be compared across devices. Study populations and criteria were completely different across trials.



option for early and moderate glaucoma.

## Emerging MIGS procedures

### MINIject

The MINIject device (iStar Medical, Wavre, Belgium) is a 4 mm stent designed to follow the curvature of the sclera and utilises porous silicone to allow aqueous outflow via the uveoscleral pathway. No studies were identified investigating the MINIject device, and this is an area where more evidence is required before a clear comment can be made about this form of MIGS.<sup>28</sup>

### Beacon aqueous microshunt

This device is designed to reduce IOP by shunting aqueous fluid onto the ocular surface via a clear corneal incision. There are currently no clinical trials on this device.<sup>32</sup>

## MIGS vs Trabeculectomy

Currently, there are only a few reports comparing MIGS to fistulating trabeculectomy. In a retrospective study,<sup>33</sup> canaloplasty was compared with trabeculectomy regarding safety and efficacy. The IOP dropped from  $21.2 \pm 6.6$  mmHg preoperatively to  $13.8 \pm 4.9$  mmHg (32% reduction of IOP) in the canaloplasty group and from  $23.4 \pm 10.4$  mmHg to  $11.6 \pm 4.0$  mmHg (43% reduction of IOP) in the trabeculectomy group at 12 months ( $P = 0.03$ ). Also, the study confirmed the different profile of complications between the two techniques. Among canaloplasty patients, the most common complications were hyphema (21%) followed by peripheral anterior synechiae (6%) and Descemet's detachment (3%). In the trabeculectomy group, choroidal detachment was observed in 17% of the patients, followed by bleb revision (15%), hypotony maculopathy (4%), and suprachoroidal hemorrhage (2%). Brüggemann et al. compared trabeculectomy and canaloplasty between both eyes of the same patient.<sup>34</sup> In this consecutive case series of 30 eyes, mean IOP reduction was of 50.3% ( $26.73 \pm 6.4$  mmHg preoperatively to  $13.21 \pm 2.83$  mmHg postoperatively) in canaloplasty, while IOP decreased by 53.4% in trabeculectomy ( $26.3 \pm 10.9$  mmHg preoperatively to  $15.2 \pm 11.2$  mmHg postoperatively). In the canaloplasty group, only two eyes required further intervention (anterior chamber reformation and goniotomy), while in the trabeculectomy group, a total of 112 procedures were necessary to control IOP (5-FU injection, 5-FU needling, bevacizumab injection, laser suture lysis, anterior chamber reformation, bleb revision, cataract surgery, and conjunctival closure). Furthermore, it is important to emphasize that canaloplasty patients needed an average of  $3.9 \pm 0.8$  follow-up visits, while trabeculectomy patients needed  $8.5 \pm 3.6$  follow-up visits, indicating that bleb-independent procedures need less postoperative care. One recent study evaluated the results after combined procedures—phacotrabeculectomy and

phacocanaloplasty.<sup>35</sup> In the phacotrabeculectomy group, IOP decreased from  $30.0 \pm 5.3$  mmHg to  $11.7 \pm 3.5$  mmHg, while in phacocanaloplasty group, the observed decrease was from  $28.3 \pm 4.1$  mmHg preoperatively to  $12.6 \pm 2.1$  mmHg postoperatively. Though the phacotrabeculectomy group showed greater IOP decrease results, there was no statistical significance over time between the two groups. The incidence of complications had no statistical significance between groups, but phacotrabeculectomy-related complications (choroidal detachment, bleb leakage, and the need for anterior vitrectomy) showed a greater risk profile. Furthermore, the number of invasive postsurgical interventions, like laser suture lysis and subconjunctival injections (needling), was greater in the phacocanaloplasty group. Besides comparison regarding safety and efficacy, any new surgical techniques and devices must have a good cost-value ratio for the health care system in order to become a true alternative to classic fistulating surgery. Currently, there is only one study comparing the costs between a new procedure, that is, canaloplasty and trabeculectomy.<sup>36</sup> The mean duration of hospitalization was  $5.3 \pm 0.8$  days in the canaloplasty group, whereas it was  $10.7 \pm 2.8$  days in the trabeculectomy group. In the beginning, operating time was greater in canaloplasty which directly implies greater costs; however, with larger surgeon's experience, there was a great decrease in surgical time. Although both procedures achieved good IOP control, longer hospitalization, higher readmission rates, and more postoperative visits in the trabeculectomy group resulted in a higher total cost. This comparison may be exemplarily for other MIGS procedures. One must not only consider the expenses for the new device itself, but also the time and effort for the follow-up visits, including postoperative interventions which ultimately reflect better quality of life for the patient and health professionals and lower health care costs.

## Conclusion

Minimally invasive glaucoma surgery has, for several years, been a disrupting force in the area of glaucoma management and is a therapy that has effectively established itself between medical management and more invasive glaucoma surgery. MIGS offer significant advantages in terms of safety and efficacy for the patient with mild to moderate glaucoma and a significant medication burden. As this area of glaucoma surgery continues to grow, so too will the evidence in support of MIGS as a legitimate intermediate step in the glaucoma management pathway.

## Financial Disclosure- None

## Conflicts of Interest- None

## References

1. Hooshmand J, Rothschild P, Allen P, Kerr NM, Vote BJ, Toh T. Minimally invasive glaucoma surgery: Comparison of iStent with iStent inject in primary open angle glaucoma. *Clin Exp Ophthalmol* 2019;47:898-903.
2. Pillunat LE, Erb C, Junemann AG, Kimmich F. Micro-invasive glaucoma surgery (MIGS): a review of surgical procedures using stents. *Clin Ophthalmol* 2017;11:1583-600.
3. Samuelson TW, Sarkisian SR Jr., Lubeck DM, et al. Prospective, randomized, controlled pivotal trial of an Ab interno implanted trabecular micro-bypass in primary open-angle glaucoma and cataract: two-year results. *Ophthalmology* 2019;12:811-21.
4. Katz LJ, Erb C, Carceller Guillamet A, et al. Long-term titrated IOP control with one, two, or three trabecular micro-bypass stents in open-angle glaucoma subjects on topical hypotensive medication: 42-month outcomes. *Clin Ophthalmol* 2018;12:255-62.
5. Ferguson TJ, Ibach M, Schweitzer J, Karpuk KL, Stephens JD, Berdahl JP. Trabecular micro-bypass stent implantation with cataract extraction in pigmentary glaucoma. *Clin Exp Ophthalmol* 2020;48:37-43.
6. Ferguson TJ, Swan R, Ibach M, Schweitzer J, Sudhagoni R, Berdahl JP. Trabecular microbypass stent implantation with cataract extraction in pseudoexfoliation glaucoma. *J Cataract Refract Surg* 2017;43:622-6.
7. Ahmed IIK, Fea A, Au L, et al. A prospective randomized trial comparing hydrus and iStent microinvasive glaucoma surgery implants for standalone treatment of open-angle glaucoma: The COMPARE study. *Ophthalmology* 2020;127:52-61.
8. Davids AM, Pahlitzsch M, Boeker A, Winterhalter S, Maier-Wenzel AK, Klamann M. Ab interno canaloplasty (ABiC)-12-month results of a new minimally invasive glaucoma surgery (MIGS). *Graefes Arch Clin Exp Ophthalmol* 2019;257:1947-53.
9. Heersink M, Dovich JA. Ab interno canaloplasty combined with trabecular bypass stenting in eyes with primary open-angle glaucoma. *Clin Ophthalmol* 2019;13:1533-42.
10. Efsandiari H, Taubenslag K, Shah P, et al. Two-year data comparison of ab interno trabeculectomy and trabecular bypass stenting using exact matching. *J Cataract Refract Surg* 2019;45:608-14.
11. Avar M, Jordan JF, Neuburger M, et al. Long-term follow-up of intraocular pressure and pressure-lowering medication in patients after ab-interno trabeculectomy with the Trabectome. *Graefes Arch Clin Exp Ophthalmol* 2019;257:997-1003.
12. Olgun A, Aktas Z, Ucgul AY. XEN gel implant versus gonioscopy-assisted transluminal trabeculectomy for the treatment of open-angle glaucoma. *Int Ophthalmol* 2020;40:1085-93.
13. ElMallah MK, Seibold LK, Kahook MY, et al. 12-month retrospective comparison of Kahook dual blade excisional goniotomy with iStent trabecular bypass device implantation in glaucomatous eyes at the time of cataract surgery. *Adv Ther* 2019;36:2515-27.
14. Babighian, S., Rapizzi, E., & Galan, A. (2006). Efficacy and safety of ab interno excimer laser trabeculectomy in primary open-angle glaucoma: two years of follow-up. *Ophthalmologica. Journal international d'ophtalmologie. International journal of ophthalmology. Zeitschrift fur Augenheilkunde*, 220(5), 285–290. <https://doi.org/10.1159/000094616>
15. Babighian, S., Caretti, L., Tavalato, M., Cian, R., & Galan, A. (2010). Excimer laser trabeculectomy vs 180 degrees selective laser trabeculectomy in primary open-angle glaucoma. A 2-year randomized, controlled trial. *Eye (London, England)*, 24(4), 632–638. <https://doi.org/10.1038/eye.2009.172>
16. Wilmsmeyer, S., Philippin, H., & Funk, J. (2006). Excimer laser trabeculectomy: a new, minimally invasive procedure for patients with glaucoma. *Graefe's archive for clinical and experimental ophthalmology = Albrecht von Graefes Archiv fur klinische und experimentelle Ophthalmologie*, 244(6), 670–676. <https://doi.org/10.1007/s00417-005-0136-y>
17. Vold S, Ahmed II, Craven ER, et al. Two-year COMPASS trial results: supraciliary microstenting with phacoemulsification in patients with open-angle glaucoma and cataracts. *Ophthalmology* 2016;123:2103-12.
18. Mahdavi Fard A, Patel SP, Pourafkari L, Nader ND. Comparing iStent versus CyPass with or without phacoemulsification in patients with glaucoma: a meta-analysis. *Ther Adv Chronic Dis* 2019;10:2040622318820850.
19. Reiss G, Clifford B, Vold S, et al. Safety and effectiveness of cypass supraciliary micro-stent in primary open-angle glaucoma: 5-year results from the COMPASS XT study. *Am J Ophthalmol* 2019;208:219-25.
20. Myers JS, Masood I, Hornbeak DM, et al. Prospective evaluation of two iStent((R)) trabecular stents, one iStent Supra((R)) suprachoroidal stent, and postoperative prostaglandin in refractory glaucoma: 4-year outcomes. *Adv Ther* 2018;35:395-407.
21. Kerr N. MIGS: what's happening now and on the Horizon. Glaucoma Australia 2019. Available from: <https://glaucoma.org.au/news-details/treatment/migs-whats-happening-now-and-on-the-horizon>. [Last Accessed on 1 Mar 2021].

22. Karimi A, Lindfield D, Turnbull A, et al. A multi-centre interventional case series of 259 ab-interno Xen gel implants for glaucoma, with and without combined cataract surgery. *Eye (Lond)* 2019;33:469-77.
23. Wagner FM, Schuster AK, Emmerich J, Chronopoulos P, Hoffmann EM. Efficacy and safety of XEN(R)-Implantation vs. trabeculectomy: Data of a "real-world" setting. *PLoS One* 2020;15:e0231614.
24. Gillmann K, Bravetti GE, Mermoud A, Rao HL, Mansouri K. XEN gel stent in pseudoexfoliative glaucoma: 2-year results of a prospective evaluation. *J Glaucoma* 2019;28:676-84.
25. Sadruddin O, Pinchuk L, Angeles R, Palmberg P. Ab externo implantation of the MicroShunt, a poly (styrene-block-isobutylene-block-styrene) surgical device for the treatment of primary open-angle glaucoma: a review. *Eye Vis (Lond)* 2019;6:36.
26. Pantaloni AD, Barata ADO, Georgopoulos M, Ratnarajan G. Outcomes of phacoemulsification combined with two iStent inject trabecular microbypass stents with or without endocyclophotocoagulation. *Br J Ophthalmol* 2020;104:1378-83.
27. Toth M, Shah A, Hu K, Bunce C, Gazzard G. Endoscopic cyclophotocoagulation (ECP) for open angle glaucoma and primary angle closure. *Cochrane Database Syst Rev* 2019;2:CD012741.
28. Zaarour K., Abdelmassih Y., Arej N., Cherfan G., Tomey K. F., Khoeir Z. (2019). Outcomes of Micropulse Transscleral Cyclophotocoagulation in Uncontrolled Glaucoma Patients. *J Glaucoma*, 28(3):270-275. doi: 10.1097/IJG.0000000000001174. PMID: 30601220.
29. Marchand M., Singh S., Agoumi Y. (2021). Micropulse trans-scleral laser therapy outcomes for uncontrolled glaucoma: a prospective 18-month study. *Canadian Journal Ophthalmology*, 56(6):371-378. ISSN 0008-4182. <https://doi.org/10.1016/j.jcjo.2021.01.015>.
30. ELGwaily, A. M., Khedr, S. A., Assaf, A. H., Latif, M., Elsayed, H. A., & Latif, A. (2021). MicroPulse® transscleral laser therapy in the management of glaucoma patients. Terapia láser transescleral de micropulsos en el manejo de los pacientes de glaucoma. *Archivos de la Sociedad Espanola de Oftalmologia*, S0365-6691(21)00055-1. Advance online publication. <https://doi.org/10.1016/j.oftal.2020.12.02>
31. Bernardi E, Töteberg-Harms M. MicroPulse Transscleral Laser Therapy Demonstrates Similar Efficacy with a Superior and More Favorable Safety Profile Compared to Continuous-Wave Transscleral Cyclophotocoagulation. *J Ophthalmol*. 2022 Feb 8;2022:8566044. doi:10.1155/2022/8566044. PMID: 35178250; PMCID: PMC8846995.
32. Shah M. Micro-invasive glaucoma surgery - an interventional glaucoma revolution. *Eye Vis (Lond)* 2019;6:29.
33. Ayyala RS, Chaudhry AL, Okogbaa CB, Zurakowski D. Comparison of surgical outcomes between canaloplasty and trabeculectomy at 12 months' follow-up. *Ophthalmology*. 2011;118(12):2427-2433.
34. Brüggemann A, Despouy JT, Wegent A, Müller M. Intraindividual comparison of canaloplasty versus trabeculectomy with mitomycin C in a single-surgeon series. *Journal of Glaucoma*. 2013;22(7):577-583.
35. Matlach J, Freiberg FJ, Leippi S, Grehn F, Klink T. Comparison of phacotrabeculectomy versus phacocanaloplasty in the treatment of patients with concomitant cataract and glaucoma. *BMC Ophthalmology*. 2013;13(article 1)
36. Brüggemann A, Müller M. Trabeculectomy versus canaloplasty—utility and cost-effectiveness analysis. *Klinische Monatsblätter für Augenheilkunde*. 2012;229:1118-1123.



# Keratoconus management and updates

Dr. Ritika Mullick <sup>1</sup>, Dr. Ritica Mukherjee <sup>2</sup>

<sup>1,2</sup> Cornea and Refractive Surgery, Narayana Nethralaya, Bengaluru, India

## Introduction

Keratoconus is a bilateral, noninflammatory disease characterised by corneal ectasia that may lead to irregular astigmatism and topographic irregularities with an associated decrease in visual acuity. German oculist Burchard Mauchart first described this condition in 1748. It can present in early puberty and progress till 3rd-4th decade of life. Beyond this age, progression of the disease is rare, except for hormonal changes in the body eg. pregnancy. Advanced stages of the disease are characterised by marked thinning or ectasia and scarring. The patient can present with very mild symptoms including slight blurring of vision to extreme decrease of vision, distortion of images, glare, topographic abnormalities to acute hydrops. Variants of keratoconus may include predominant axial corneal thinning, pellucid marginal degeneration or keratoglobus. <sup>1,2</sup>

There have been a variety of associated factors that have been identified with keratoconus, including chronic eye rubbing, allergic diseases of eyes or atopy, Down syndrome, Leber congenital amaurosis,<sup>2</sup> connective tissue disease, retinal degenerations, inflammation, and inheritance factors. <sup>3</sup> The development of the disease is a complex and challenging phenomenon, including histochemistry, biomechanics, enzymology, proteomics, and molecular genetic factors. Although there has been extensive research regarding the same, understanding the exact etiopathogenesis of keratoconus has been difficult. Newer modalities and techniques are now being developed for better diagnosis and treatment of corneal ectatic disorders. We discuss the advancements in the understanding of pathophysiology, diagnostics as well as treatment of keratoconus here.

## Pathophysiology:

Keratoconus has been identified as a non-inflammatory asymmetric thinning of the corneal stroma, along with a steepening of the cornea leading to an irregular astigmatism. A number of theories have led to the basic understanding of pathogenesis.

The first theory suggests that it begins with a primary insult of the epithelium, resulting in the release of proteolytic enzymes that lead to degeneration and thinning of the stromal collagen and thus weaken the cornea.<sup>4</sup> This leads to structural irregularities in the epithelium that progress with the disease. Further changes lead to breaks in Bowman's layer and stromal thinning.<sup>5</sup> To understand the etiopathogenesis of the disease, it is easier to understand the factors leading to disease formation and progression.

### • Genetics :

A positive family history of keratoconus in a diseased individual is not unusual. The Collaborative Longitudinal Evaluation of Keratoconus study showed rate of 14% of 1209 patients having a family history of keratoconus.<sup>6</sup> Wang et al found that a major gene model, that is consistent with recessive transmission, fitting their data although sporadic and environmental models were not

supported.<sup>7</sup> Few studies have demonstrated increased concordance for keratoconus in monozygotic twins. <sup>8</sup>

### • Cellular biochemistry :

Around 117 proteins and protein classes have been identified in the pathophysiology of keratoconus. Changes in the structural integrity and morphology of the keratoconic cornea, occurs through altering collagen content, differential expression and keratocyte apoptosis and necrosis in the stroma <sup>9,10</sup>. Keratoconus is associated with an increase in oxidative stress markers, especially reactive oxygen species (ROS) and reactive nitrogen species (RNS). It is also associated with an overall decrease in antioxidants. It has been found that oxidative stress markers are higher in tears and in the cornea of keratectatic eyes than aqueous humour, and antioxidants were lower in tears, aqueous humour and blood. As a result of up regulation of degradative enzymes and inhibition of the activity of protease inhibitors, corneal thinning occurs. <sup>[10]</sup> Further degenerative processes in the cornea lead to further damage. In the keratectatic cornea, the greatest level of damage is between the centre of the cone and the periphery <sup>11</sup>. Progression of disease caused by structural damage has also been seen due to increased levels of lysosomal enzymes (Cathepsin B and G).

- **Biomechanical factors :**

Numerous biomechanical factors associated with the degeneration of proteoglycans around the stromal collagen fibrils, leads to breakage and degeneration of the microfibrils. These changes result in reduced number and different distribution of lamellae, along with degenerated fibrils, that result in a biomechanically weak cornea<sup>12,13</sup>

Hence, these changes will gradually result in alteration of the curvature of the cornea leading to a cone formation. Polymorphisms of the antioxidant enzymes (catalase and glutathione peroxidase) can act as independent predictors of the severity of keratoconus, as they highlight the role of oxidative stress in the pathogenesis of the disease.<sup>14</sup> Aldehyde dehydrogenase and superoxide dismutase enzymes play important roles in the reactive oxygen processes of different species that cause cytotoxic deposition of malondialdehyde and peroxynitrites, which could potentially damage corneal tissue. Rigid contact lens wear has also been associated with keratoconus development.<sup>15</sup>

- **Diagnostics and advances:**

The diagnosis of keratoconus to begin with will affect the prognosis and treatment. Therefore earlier the diagnosis, the outcome of treatment will provide better visual rehabilitation to the patient. Early or forme fruste keratoconus include a pre-clinical keratoconus with no topographic abnormalities or no findings on the slit lamp, while keratoconus suspects are preclinical or subclinical keratoconus with no detectable abnormalities on slit lamp examination, but inferior corneal steepening on topography with unaffected visual acuity. Some scoring parameters have been devised taking in account multiple diagnostic values in order to provide a staging for keratoconus.

- **Corneal thickness mapping**

The property of corneal epithelium to adapt to the changes in the rest of the layers of cornea has been used to diagnose keratoconus where epithelial remodeling can mask changes in the corneal curvature, leading to irregular topography. Anterior segment optical coherence tomography (AS-OCT) is known for measuring corneal epithelial thickness, and is thus widely used. A custom-designed polarization-sensitive OCT was designed by Pircher et al the thickness of the Bowman's layer in addition to the epithelium from limbus-to-limbus was noted and they found out a highly irregular "moth-like" damage pattern in the Bowman's layer in keratoconic eyes.<sup>16</sup> Studies have also employed a swept-source OCT by delineation of the air-epithelium edge and making a epithelium-Bowman's layer interface which enabled them to quantify the curvature and aberrations in the cornea.<sup>17</sup>

- **Corneal biomechanics**

The development of Brillouin microscopy for analysis of corneal biomechanical properties can allow a timelier

diagnosis. Brillouin spectroscopy is a noncontact technique that relies on the detection of a Brillouin frequency shift in a laser light that occurs during an interaction with the phonons in a cornea. The theory is derived by using the mathematical relationship between the frequency shift and the velocity of the interacting phonons, which can distinguish eyes with keratoconus from normal eyes.<sup>18</sup> An Optical coherence elastography is a newer method that provides a depth-dependent analysis of the cornea using the ultrasound elastography principle.<sup>19</sup> A pilot study for the same has shown selective anterior stromal weakening in eyes with keratoconus when compared with normal eyes.<sup>20</sup> Other techniques that are still in the development phase include the biomechanical characterization of the cornea with digital image correlation,<sup>21</sup> high-resolution shear wave imaging,<sup>22</sup> and phase-decorrelation OCT.<sup>23</sup>

- **Biomarkers**

The role of tear inflammatory cytokine and matrix metalloproteinase levels along with significant reductions in tear IgA, total tear protein production, and lactoferrin, have always been a topic of research. Several studies have suggested a link between atopy and keratoconus. Atopic diseases include asthma, allergic rhinitis, combination of allergic conjunctivitis, chronic blepharitis, and vernal keratoconjunctivitis wherein the serum IgE levels are high. McKay et al studied the distribution of tear immunoglobulin heavy and light chains is different between keratoconus and healthy controls, and concluded that a disturbance in B-cell function may play a role in keratoconus pathogenesis.<sup>24</sup> Another study by Fodor et al demonstrated a concomitant increase in tear nerve growth factor and interleukin (IL)-13 that was related to keratoconus progression.<sup>25</sup> Other studies have shown that there are altered hormone levels in the saliva, plasma, tear, hair follicles, and aqueous humor in patients with keratoconus as also the saliva prolactin-induced protein levels.

- **Artificial Intelligence**

Combining features from AS-OCT and Scheimpflug imaging has shown to differentiate a neural network algorithm for subclinical keratoconus compared to single instrument-derived parameters.<sup>26</sup> Corneal OCT images (CorneaNet) is a newer technique to create a model that could be used for early keratoconus detection. Several techniques using artificial intelligence have also shown greater potential to differentiate forme fruste or suspected keratoconus from normal eyes or manifest keratoconus from suspected keratoconus.

- **Treatment and advances:**

The spectrum of keratoconus treatment will depend on symptomatic presentation, diagnostic evaluation and progression of the disease. The combination of different protocols and modes of treatment are to arrest progression of ectasia and avoid full-thickness keratoplasty surgery and associated complications. We review the treatment protocols depending on the stage of the disease.

Medical management of keratoconus: Multiple studies and researches have proved the role of IgE associated with allergy and atopy in the pathogenesis of keratoconus. IgE mediated cellular responses directly mediate the severity of symptoms and signs in patients with keratoconus. A study conducted by Kemp et al, stated that the total serum IgE and allergen specific IgE values were raised in patients with keratoconus.<sup>27</sup>

Increased serum IgE is also proven to be associated with the disease progression and graft rejection in KC patients.<sup>28</sup> Newer studies have proven that there is a significant increase in both serum and tear IgE levels in ectatic disorders without allergy as compared to controls. More studies assessing tear IgE levels in KC are the need of the hour to improve the knowledge about tear IgE levels. Management with respect to identification and managing allergy and altered IgE status in KC patients to slow the progression of disease, and also to improve the clinical outcome of surgical treatments. Patients with associated allergy are more likely to progress and complications like acute hydrops are more likely due to the associated inflammation and eye rubbing. It is therefore necessary to adequately treat the ocular as well as systemic allergy.

- **Spectacles and Contact lenses:**

In very early stages of the disease, spectacles can provide acceptable improvement in vision and can provide vision of 20/40 or better. In cases of irregular astigmatism that cannot be corrected with spectacles, hard contact lenses are an option for treatment.<sup>29</sup> In early stages of ectasia, a Toric soft lens may be used for correction of regular astigmatism. Special lenses such as Rose K, hybrid lenses, piggy back, or scleral lenses may be used in progressive diseases and irregular astigmatism.<sup>30</sup> Rigid gas permeable lenses and scleral lenses are mainstay for management of moderate to advanced keratoconus. These lenses offer patients more stable vision, but are not well tolerated by some patients. Smiddy et al. in their study showed that upto 70% of patients could benefit in multiple ways by using contact lenses after corneal grafting.<sup>31</sup>

- **Collagen Cross-linking:**

Corneal collagen cross-linking (CXL) was introduced by Wollensak et al. as a technique to slow or halt the progression of keratoconus<sup>32</sup>. In collagen cross linking of the cornea, riboflavin (vitamin B2) is administered in conjunction with ultraviolet A (UV-A, 365 nm). The interaction of the two that follows, leads to the formation of reactive oxygen species, which leads to the formation of additional covalent bonds between collagen molecules in the tissue. These added covalent bonds lead to consequent biomechanical stiffening of the cornea<sup>33</sup>. Collagen cross linking is now widely used in the treatment of keratoconus and post-LASIK ectasia. The Dresden or Epithelium-off protocol was the originally accepted and still widely used procedure, wherein epithelium debridement is followed by isotonic Riboflavin application and UV-A irradiation

(3nW/cm<sup>2</sup>) for 30 minutes. Further modifications in the original protocol were based on following factors:

1. Increasing Oxygen availability
2. Increasing Riboflavin delivery
3. Reducing UV-A irritation exposure time
4. Challenges in treatment of extremely thin corneas (<400um)

In conjunction with these requirements, certain modifications were made in the epithelium off protocol. Accelerated or high-fluence protocols are an alternative to the conventional crosslinking protocol in terms of reduced exposure time. It follows Bunsen-Roscoe's law of reciprocity, which states that an increased intensity along with reduced exposure time of UV-A irradiation will deliver a total energy dose to the tissue which is equivalent to the conventional treatment, ultimately providing a similar biological effect. Shetty *et al.* in a prospective randomised interventional study of 138 eyes with keratoconus which underwent crosslinking at radiance of 3, 9, 18 or 30mW/cm<sup>2</sup>, for 30,10, 5 and 3 minutes respectively, studied that while there was an improvement in the corrected distance visual acuity in all groups at 12 months, the change was not significant in the 30mW/cm<sup>2</sup> group and the most improvement occurred in the 18mW/cm<sup>2</sup> group.<sup>34</sup>

Corneal collagen bonds are formed at a depth of 300 μm in the anterior stroma and a minimum of 400 μm stromal thickness is required for keeping the endothelium safe<sup>34,35</sup>. Patients with advanced progressive keratectasia, with corneal pachymetry less than 400μm have to be excluded from the standard CXL treatment protocol. Various modifications of the standard protocol have thus been made so as to treat extremely thin and ectatic corneas. Hafezi *et al* proposed an alternative treatment protocol by using hypoosmolar riboflavin solution to swell the corneal stroma. Hypo-osmolar riboflavin solution (0.1%) is prepared by diluting vitamin B2-riboflavin-5-phosphate 0.5% with physiological salt solution (sodium chloride 0.9% solution; 310 mOsmol/L).

A contact lens assisted cross-linking was developed wherein, the contact lens provides the functional thickness necessary to overcome the two potential complications associated with cross-linking of thin corneas, namely - ultraviolet-related endothelial cell damage and permanent stromal haze. It does not require additional time, additional expensive equipment or special solutions. The SMILE lenticule assisted CXL is another technique recently proposed that uses a riboflavin soaked SMILE lenticule for artificially increasing functional corneal thickness.<sup>36</sup> A recent study by Randleman *et al.* that compared the biomechanical efficacy of CACXL and standard CXL porcine eyes using Brillouin microscopy and extensometry testing showed that CACXL achieved 70% stiffening effect of the standard CXL group

The customised CXL, is a further modification of the standard procedure, where a smaller eccentric

debridement area is treated along with a customised UV-irradiation profile. There is a concentric superposition of 3 circular areas centred on the maximum of the posterior sphere. The diameter of the inner circle is equal to the shortest diameter of the posterior sphere minus 0.5 mm, while the outer circle is 1mm larger than the maximum diameter of the posterior sphere. The middle circle is the mean of the other two diameters. The irradiation is varied in all the three circles, the inner circle is 10J/cm<sup>2</sup>, in the middle 7.5J/cm<sup>2</sup> and in the outer 4.5J/cm<sup>2</sup>. Kanellopoulos et al first described a case of customized crosslinking, using irradiation that was applied in a customized toric pattern in a transepithelial

approach, where it was concluded that there was a mean astigmatic reduction with a subsequent improvement in uncorrected visual acuity noted at 6 months.<sup>37</sup> Seiler et al in their study showed that customized CXL flattens the cornea at least as efficiently as standard CXL, the regularization effect of cross linking is stronger in the customized group, and the healing of the epithelium is faster compared to standard epi off-CXL. They also introduced a new concept, called the index of the regularization RI, was significantly higher in the customized group as compared to the control group, which basically signifies the regularisation of cornea, following a customised cross linking.

Protocol	Epithelium	UV-A Irradiation / Energy (J/cm <sup>2</sup> )	Riboflavin Solution	Riboflavin soaking
Dresden (Epithelium-off)	Off	3mW/cm <sup>2</sup> for 30 minutes 5.4J/cm <sup>2</sup>	Isotonic riboflavin 0.1% with dextran 20% solution	Every 2 minutes for 30 minutes
Epithelium-on / Trans-epithelial	On	3mW/cm <sup>2</sup> for 30 minutes 5.4J/cm <sup>2</sup>	0.1% riboflavin + 15% dextran solution supplemented with Tris-hydroxymethylaminomethane and sodium ethylenediaminetetraacetic acid (EDTA)	Two drops every 5 minutes
Accelerated	Off	30 mW/cm <sup>2</sup> for 3 minutes 7.2J/cm <sup>2</sup>	Dextran-free riboflavin 0.1% solution	Every 2 minutes for 10 minutes
Hypo-osmolar	Off	3mW/cm <sup>2</sup> for 30 minutes 5.4J/cm <sup>2</sup>	0.1% vitamin B2-riboflavin-5-phosphate 0.5% with physiological salt solution (sodium chloride 0.9% solution; 310 mOsmol/L)	Every 3 minutes for 30 minutes
CACXL	Off + Contact lens	3 mW/cm <sup>2</sup> for 30 min or 10 mW/cm <sup>2</sup> for 9 minutes	Isotonic riboflavin 0.1% with dextran 20% solution	Every 3 minutes for 30 minutes
Customised CXL	On/Off	Inner circle - 10J/cm <sup>2</sup> Middle circle - 7.5J/cm <sup>2</sup> Outer circle- 4.5J/cm <sup>2</sup>	Isotonic riboflavin 0.1% with dextran 20% solution	

- Intracorneal Ring Segments :**

Intacs or intracorneal ring segments are ring segments that are implanted into the stroma to alter the corneal curvature. They are indicated in patients with severe reduction of visual acuity, that cannot be corrected with spectacle or lens correction, minimum age of 21 years, clear central corneas, minimum corneal thickness of 400 µm, and when keratoplasty is the only remaining option for regaining visual function.<sup>38</sup> They are contraindicated

for cases with Kmax>70 D, central corneal scarring, corneal opacity, or hydrops. In a study by Hashemi et al. on 12 patients with post-LASIK ectasia, better results were obtained when the ring was implanted at a depth equal to 60–80% of the corneal thickness; while it was proven that rings implanted deeper in the cornea may have no effect on improving visual acuity.<sup>39</sup> ICRS and its combination with CXL has been well described; and is a better treatment modality. Triple procedures combining PRK + C-CXL and ICRC are also under review for treatment.<sup>40</sup>

- **Phakic Intraocular Lenses:**

Phakic intraocular lenses are one of the surgical treatment options in patients with high irregular astigmatism, not suitable for refractive surgery, with progressive keratoconus, which could be combined with cross-linking procedures.<sup>41</sup> Various types of phakic IOL can include anterior chamber angle-fixated PIOL, anterior chamber iris-fixated PIOL, and posterior chamber PIOL or Implantable collamer lens. Implantable collamer lenses (toric and non-toric) are used in the correction of myopia, astigmatism associated with keratoconus. Phakic iris-fixated anterior chamber lenses offer a feasible refractive treatment for stabilised keratoconus. Isaak Fischinger et al, in their study of toric IOL implantation in keratoconus patients concluded that the Uncorrected visual acuity is better than the post-operative best corrected vision in patients with keratoconus, and implantation of phakic IOLs in PMD-like ectatic disorders have greater efficacy than in Keratoconus.<sup>42</sup> Phakic IOL implantation post CXL, have also shown promising results, ranging from 3 months to 6 months post-CXL period.<sup>43,44</sup> One study done by Izquierdo et al., was done to study the outcomes of phakic Artiflex lenses in grade 1 or 2 keratoconus.<sup>45</sup>

Multiple advancements in terms of IOL modalities, including iris-claw lens are being studied for the better surgical management of keratoconus, not suitable for excimer laser surgery.

- **Conductive keratoplasty:**

Conductive therapy has been used in the treatment of hyperopia and presbyopia. Alio et al first described the treatment of advanced keratoconus by performing conductive keratoplasty.<sup>46</sup> Later, few study groups with small patient sample size reported efficacy of conductive keratoplasty in keratoconus in terms of best corrected visual acuity and better contact lens tolerance. Study conducted by Sinjab et al showed improvement and stabilisation of visual acuity in patients with moderate to severe loss of vision due to keratoconus or post-LASIK ectasia.<sup>47</sup> The parameters like ISV, anterior corneal index derived from Scheimpflug corneal topography, may be a useful technique of corneal surface irregularity measurement in the progression of ectatic disorders. A topography-guided conductive keratoplasty (TGCK) is a newer treatment in advanced keratoconus which was studied by Kato et al., that suggested stable vision improvement at 12 months after surgery in the majority of the eyes.<sup>48</sup> TGCK can be a treatment option for non-progressive advanced keratoconus and patients not tolerating contact lenses.

- **Gene therapy:**

The role of genetics is under thorough research,

and multiple studies have identified genes associated with ectatic disorders. Genome studies can evaluate complex genetic factors associated with keratoconus and through genomic studies ZNF469 was found in 23% of Keratoconus.<sup>49</sup> and seems to play an important role in progression. Other important genes associated are, visual system homeobox 1 (VSX1) and superoxide dismutase 1 (SOD1).<sup>50</sup> In gene therapy treatment, there is delivery of the gene of interest into the target cell using a vector and the subsequent genetic expression begins with protein synthesis.<sup>51</sup> Gene therapy can prove to be a promising and effective way, which is still under research, to change the course of the disease and progression.

- **Bowman layer transplantation :**

This technique was described by Digk et al, wherein an isolated Bowman's layer graft is to be placed mid-stroma in order to stabilise cornea.<sup>52</sup> After manual creation of the graft, about 9-11mm in diameter, and staining with trypan blue, it is placed into a mid-stromal pocket through a scleral tunnel. It is recommended in patients who are contact lens intolerant, patients with corneal scarring, treating higher order aberrations, especially spherical aberration. Post surgical results have proven better results in terms of vision. In case of DM perforation, surgery may be converted to DALK or Penetrating keratoplasty.

- **Keratoplasty:**

Treatment of advanced keratoconus mainly includes surgical procedures depending upon the depth of the scarring. The Singapore corneal transplant study consisted of 168 patients with keratoconus, who underwent keratoplasty, the mean BCVA of the PK and DALK groups also were not significantly different at 24 months after surgery.<sup>53</sup>

Risk factors of allograft rejection, suture and wound healing related problems, persistent irregular astigmatism and progression of the disease in the recipient rim are common complications with these procedures.<sup>[54,55]</sup> Currently there are techniques based on manual and automated dissection of the donor and receptor graft (microkeratome, femtosecond laser and excimer laser) to obtain lamellar transplants at different depths.<sup>56,57</sup> Recent trend is to use a femtosecond laser to perform a precise tissue disruption at predetermined depths with the aim of achieving uniform dissection and better visual results.<sup>58</sup> Recent advancement in deep anterior lamellar transplant assisted by pachymetry (PALK) involves performing a photoablation with an excimer laser guided by topography and pachymetry of 95% of the stromal surface in a way that more regular cuts can be made at specific diameters.<sup>59,60</sup>

**Financial Disclosure- None**

**Conflicts of Interest- None**



## References

1. Elder MJ. Leber congenital amaurosis and its association with keratoconus and keratoglobus. *J Pediatr Ophthalmol Strabismus*. 1994 Jan-Feb;31(1):38-40.
2. Krachmer JH, Feder RS, Belin MW. Keratoconus and related noninflammatory corneal thinning disorders. *Surv Ophthalmol*. 1984 Jan-Feb;28(4):293-322.
3. Rabinowitz YS. Keratoconus. *Surv Ophthalmol*. 1998;42 (4):297–319.
4. Teng CC. Electron microscope study of the pathology of keratoconus part 1 *Am J Ophthalmol* 1963;51:18–47.
5. Sawaguchi S, Fukuchi T, Abe H, Kaiya T, Sugar J, Yue BY. Three dimensional electron microscopic study of keratoconus. *Arch Ophthalmol*. 1998;116:62–98.
6. Wagner H, Barr JT, Zadnik K. Collaborative longitudinal evaluation of keratoconus (CLEK) study: methods and findings to date. *Cont Lens Anterior Eye*. 2007;30:223–232.
7. Wang Y, Rabinowitz YS, Rotter JI, et al. Genetic epidemiological study of keratoconus: evidence for major gene determination. *Am J Med Genet*. 2000;93:403–409.
8. McMahon TT, Shin JA, Newlin A, et al. Discordance for keratoconus in two pairs of monozygotic twins. *Cornea*. 1999;18:444–451.
9. Srivastava OP, Chandrasekaran D, Pfister RR. Molecular changes in selected epithelial proteins in human keratoconus corneas compared to normal corneas. *Mol Vis* 2006;12:1615–25.
10. Yam GHF, Fuest M, Zhou L, Liu YC, Deng L, Chan ASY, et al. Differential epithelial and stromal protein profiles in cone and non-cone regions of keratoconus corneas. *Sci Rep* 2019;9:2965. <https://doi.org/10.1038/s41598-019-39182-6>.
11. Brookes NH, Loh IP, Clover GM, Poole CA, Sherwin T. Involvement of corneal nerves in the progression of keratoconus. *Exp Eye Res* 2003;77:515–24. [https://doi.org/10.1016/S0014-4835\(03\)00148-9](https://doi.org/10.1016/S0014-4835(03)00148-9).
12. Alkanaana A, Barsotti R, Kirat O, Khan A, Almubrad T, Akhtar S. Collagen fibrils and proteoglycans of peripheral and central stroma of the keratoconus cornea – ultrastructure and 3D transmission electron tomography. *Sci Rep* 2019;9:19963. <https://doi.org/10.1038/s41598-019-56529-1>.
13. Göttinger E, Pircher M, Dejaco-Ruhswurm I, Kaminski S, Skorpik C, Hitzemberger CK. Imaging of birefringent properties of keratoconus corneas by polarization-sensitive optical coherence tomography. *Investig Ophthalmol Vis Sci* 2007;48:3551–8. <https://doi.org/10.1167/iovs.06-0727>. [
14. Abdul-Maksoud RS, Fouad RA, Elsayed TG, Ibrahim RA, Badawi AE. The impact of catalase and glutathione peroxidase-1 genetic polymorphisms on their enzyme activities among Egyptian patients with keratoconus. *J Gene Med* 2020;22:e3192. <https://doi.org/10.1002/jgm.3192>.
15. Gasset AR, Houde WL, Garcia-Bengochea M. Hard contact lens wear as an environmental risk in keratoconus. *Am J Ophthalmol* 1978;85:339–41. [https://doi.org/10.1016/S0002-9394\(14\)77725-6](https://doi.org/10.1016/S0002-9394(14)77725-6).
16. Pircher N, Beer F, Holzer S, et al.. Large field of view corneal epithelium and bowman's layer thickness maps in keratoconic and healthy eyes. *Am J Ophthalmol* 2020; 209: 168–177.
17. Matalia H, Francis M, Gangil T, et al.. Noncontact quantification of topography of anterior corneal surface and bowman's layer with high-speed OCT. *J Refract Surg* 2017; 33: 330–336.
18. Seiler TG, Shao P, Eltony A, et al.. Brillouin spectroscopy of normal and keratoconus corneas. *Am J Ophthalmol* 2019; 202: 118–125.
19. De Stefano VS, Ford MR, Seven I, et al.. Live human assessment of depth-dependent corneal displacements with swept-source optical coherence elastography. *PLoS ONE* 2018; 13: e0209480.
20. De Stefano VS, Ford MR, Seven I, et al.. Depth-dependent corneal biomechanical properties in normal and keratoconic subjects by optical coherence elastography. *Transl Vis Sci Technol* 2020; 9: 4.
21. Hang X, Wang Q, Wang L, et al.. Cornea full-field displacement and strain measurement in vivo using three-dimensional digital image correlation. *Optom Vis Sci* 2018; 95: 1027–1034.
22. Chen PY, Shih CC, Lin WC, et al.. High-resolution shear wave imaging of the human cornea using a dual-element transducer. *Sensors (Basel)* 2018; 18: 4244.
23. Blackburn BJ, Gu S, Ford MR, et al.. Noninvasive assessment of corneal crosslinking with phase-decorrelation optical coherence tomography. *Invest Ophthalmol Vis Sci* 2019; 60: 41–51.
24. McKay TB, Serjersen H, Hjortdal J, et al.. Characterization of tear immunoglobulins in a small-cohort of keratoconus patients. *Sci Rep* 2020; 10: 9426.
25. Fodor M, Vitályos G, Losonczy G, et al.. Tear mediators NGF along with IL-13 predict keratoconus progression. *Ocul Immunol Inflamm*. Epub ahead of print 4 March 2020. DOI: 10.1080/09273948.2020.1716024.

26. Shi C, Wang M, Zhu T, et al.. Machine learning helps improve diagnostic ability of subclinical keratoconus using Scheimpflug and OCT imaging modalities. *Eye Vis (Lond)* 2020; 7: 48.
27. Kemp EG, Lewis CJ. Measurement of total and specific IgE levels in the management of a family exhibiting a high incidence of keratoconus. *Acta Ophthalmol (Copenh)* 1984;62:524–9.
28. El Rami H, Chelala E, Dirani A, Fadlallah A, Fakhoury H, Cherfan C, et al. An update on the safety and efficacy of corneal collagen cross-linking in pediatric keratoconus. *Biomed Res Int.* 2015;2015:257927.
29. Smiddy W.E., Hamburg T.R., Kracher G.P., Stark W.J. Keratoconus. Contact lens or keratoplasty? *Ophthalmology.* 1988;95(4):487–492.
30. Rathi V.M., Mandathara P.S., Dumpati S. Contact lens in keratoconus. *Indian J Ophthalmol.* 2013;61(8):410–415.
31. Smiddy W.E., Hamburg T.R., Kracher G.P., Stark W.J. Keratoconus. Contact lens or keratoplasty? *Ophthalmology.* 1988;95(4):487–492.
32. G. Wollensak, E. Spoerl, and T. Seiler, “Riboflavin/ultraviolet-a induced collagen crosslinking for the treatment of keratoconus,” *The American Journal of Ophthalmology*, vol. 135, no. 5, pp. 620– 627, 2003
33. G. Wollensak, E. Spoerl, and T. Seiler, “Stress-strain measurements of human and porcine corneas after riboflavin ultraviolet-A-induced cross-linking,” *Journal of Cataract and Refractive Surgery*, vol. 29, no. 9, pp. 1780–1785, 2003.
34. Shetty R., Pahuja N.K., Nuijts R.M., Ajani A., Jayadev C., Sharma C., Nagaraja H. Current protocols of corneal collagen cross-linking: Visual, refractive, and tomographic outcomes. *Am. J. Ophthalmol.* 2015;160(2):243–249. doi: 10.1016/j.ajo.2015.05.019.
35. A. J. Kanellopoulos and G. Asimellis, “Keratoconus management: long-term stability of topography-guided normalization combined with high-uecnce CXL stabilization (e Athens Protocol),” *Journal of Refractive Surgery*, vol. 30, no.2
36. A. J. Kanellopoulos, I. M. Aslanides, and G. Asimellis, “Correlation between epithelial thickness in normal corneas, untreated ectatic corneas, and ectatic corneas previously treated with CXL; is overall epithelial thickness a very early ectasia prognostic factor?” *Clinical Ophthalmology*, vol. 6, no. 1, pp. 789–800, 2012
37. Sachdev MS, Gupta D, Sachdev G, Sachdev R. Tailored stromal expansion with a refractive lenticule for crosslinking the ultrathin cornea. *J Cataract Refract Surg.* 2015;41:918–23.
38. Chou B., Wachler B.S.B. Intacs for a keratocone: a promising new option? *Rev Optometry.* 2000;137(4) 97–97.
39. Hashemi H., Yazdani-Abyaneh A., Beheshtnejad A., Jabbarvand M., Kheirkhah A., Ghaffary S.R. Efficacy of intacs intrastromal corneal ring segment relative to depth of insertion evaluated with anterior segment optical coherence tomography. *Middle East Afr J Ophthalmol.* 2013;20(3):234–238. [[PMC free article](#)] [[PubMed](#)] [[Google Scholar](#)]
40. Ertan A., Colin J. Intracorneal rings for keratoconus and keratectasia. *J Cataract Refract Surg.* 2007;33(7):1303–1314.
41. Kamiya K., Shimizu K., Ando W., Asato Y., Fujisawa T. Phakic toric Implantable Collamer Lens implantation for the correction of high myopic astigmatism in eyes with keratoconus. *J Refract Surg.* 2008;24(8):840–842.
42. Fischinger IR, Wendelstein J, Tetz K, Bolz M, Tetz MR. Toric phakic IOLs in keratoconus-evaluation of preoperative parameters on the outcome of phakic anterior chamber lens implantation in patients with keratoconus. *Graefes Arch Clin Exp Ophthalmol.* 2021 Jun;259(6):1643-1649. doi: 10.1007/s00417-020-05041-8. Epub 2021 Jan 19. PMID: 33464378; PMCID: PMC8166703.
43. Izquierdo L, Henriquez MA, McCarthy M. Artiflex phakic intraocular lens implantation after corneal collagen cross-linking in keratoconic eyes. *J Refract Surg.* 2011;27(7):482–487. doi: 10.3928/1081597X-20101223-02.
44. Güell JL, Morral M, Malecaze F, Gris O, Elies D, Manero F. Collagen crosslinking and toric iris-claw phakic intraocular lens for myopic astigmatism in progressive mild to moderate keratoconus. *J Cataract Refract Surg.* 2012;38(3):475–484. doi: 10.1016/j.jcrs.2011.10.031.
45. Alio JL, Caramonte PJ, Caliz A, et al. Corneal modeling of keratoconus by conductive keratoplasty. *J Cataract Refract Surg.* 2005;31(1):190–197. doi:10.1016/j.jcrs.2004.10.042
46. Sinjab, Mazen M et al. “Outcomes of Conductive Keratoplasty Combined with Corneal Crosslinking in Advanced Ectatic Corneal Disease.” *Clinical ophthalmology (Auckland, N.Z.)* vol. 15 1317-1329. 29 Mar. 2021, doi:10.2147/OPHTH.S259012.
47. Kato N., Toda I., Kawakita T., Sakai C., Tsubota K. Topography-guided conductive keratoplasty: treatment for advanced keratoconus. *Am J Ophthalmol.* 2010;150(4):481–489. E481.
48. Vincent A.L., Jordan C.A., Cadzow M.J., Merriman T.R., McGhee C.N. Mutations in the zinc finger protein gene, ZNF469, contribute to the pathogenesis of keratoconus. *Invest Ophthalmol Vis Sci.* 2014;55(9):5629–5635.
49. Gordon-Shaag A., Millodot M., Shneur E., Liu Y. The genetic and environmental factors for keratoconus. *BioMed Res Int.* 2015;2015:795738.
50. Farjadnia M., Naderan M., Mohammadpour M. Gene therapy in keratoconus. *Oman J Ophthalmol.* 2015;8(1):3–8
51. van Dijk K., Parker J., Tong C.M. Midstromal isolated Bowman layer graft for reduction of advanced keratoconus: a technique to postpone penetrating or deep anterior lamellar keratoplasty. *JAMA Ophthalmol.* 2014;132(4):495–501.

52. Kemp EG, Lewis CJ. Immunoglobulin patterns in keratoconus with particular reference to total and specific IgE levels. *Br J Ophthalmol*. 1982;66:717–20.
53. Tan DT, Janardhanan P, Zhou H, et al. Penetrating keratoplasty in Asian eyes: the Singapore Corneal Transplant Study. *Ophthalmology* 2008;115:975–982.
54. Reinhart WJ, Musch DC, Jacobs DS, Lee WB, Kaufman SC, Shtein RM. Deep anterior lamellar keratoplasty as an alternative to penetrating keratoplasty a report by the american academy of ophthalmology. *Ophthalmology* 2011; 118:209-18.
55. Han DC, Mehta JS, Por YM, Htoon HM, Tan DT. Comparison of outcomes of lamellar keratoplasty and penetrating keratoplasty in keratoconus. *Am J Ophthalmol* 2009; 148:744- 751.e1.
56. Buzzonetti L, Laborante A, Petrocelli G. Refractive outcome of keratoconus treated by combined femtosecond laser and bigbubble deep anterior lamellar keratoplasty. *J Refract Surg* 2011; 27:189-94.
57. Busin M, Scorcio V, Zambianchi L, Ponzin D. Outcomes from a modified microkeratome-assisted lamellar keratoplasty for keratoconus. *Arch Ophthalmol* 2012 ;130:776-82.
58. Tan DT, Ang LP. Modified automated lamellar therapeutic keratoplasty for keratoconus: a new technique. *Cornea* 2006; 25:1217-9.
59. Almousa R, Samaras KE, Khan S, Lake DB, Daya SM. Femtosecond laser-assisted lamellar keratoplasty (FSLK) for anterior corneal stromal diseases. *Int Ophthalmol* 2014; 34:49- 58.
60. Spadea L, Gizzi R, Evangelista Conocchia N, Urbano S. Optical pachymetry-guided custom excimer laser-assisted lamellar keratoplasty for the surgical treatment of keratoconus. *J Cataract Refract Surg* 2012; 38:1559-67.



# Implantable collamer lens (ICL)

Dr. Pooja Khamar<sup>1</sup>, Dr. Savitri Deval<sup>2</sup>, Dr. Anuj Satija<sup>3</sup>

<sup>1,2,3</sup> Cataract and Refractive Surgery, Narayana Nethralaya, Bengaluru, India.

## Introduction

Despite the fast pace of evolution in the field of refractive surgery, refractive errors still continue to be the most common cause of ocular morbidity and visual impairment all across the globe. Approximately 101.2 million people across the globe suffer from visual impairment owing to uncorrected refractive error and these numbers have been steadily increasing over time. [1] Myopia being the most common of all, affects approximately every 6<sup>th</sup> person in the world. <sup>2,3,4</sup>

Despite causing morbidity, refractive error also effects the economy of different strata of the society. <sup>5,6</sup> A study by Smith et al revealed it to be causing an annual economy loss of 269 billion dollar worldwide. <sup>6</sup>

### Refractive procedures can broadly be classified into -

1. Keratorefractive procedures
2. Lens-based refractive procedures
3. Combined lens-based and cornea-based refractive procedures

Cornea can be modified by incision-based procedures [e.g., radial keratotomy (RK)] or by laser-based procedures [e.g., photorefractive keratectomy (PRK), laser assisted in-situ keratomileusis (LASIK) or femtosecond laser assisted small incision lenticule extraction (SMILE)].

For higher degrees of refractive error and in cases where corneal refractive procedures are contraindicated, lens based refractive surgery offers a suitable alternative, which includes Refractive Lens Exchange (RLE) or Phakic Refractive lenses (PRLs).

In RLE, myopia in the range of -16D to -30D is treated with clear lens extraction by phacoemulsification followed by intraocular lens implantation to achieve emmetropia. Since accommodation is compromised, it is more suited for patients having lens opacities (even early) in the presbyopic age group. One of the main concerns about RLE in highly myopic eyes is the increased risk for retinal detachment (RD), especially in younger patients and in eyes with long axial lengths (>26 mm). The incidence of RD after RLE ranges from 0% to 8%. <sup>7,8</sup>

In PRL, an IOL of an appropriate power is implanted inside the eye without touching the natural crystalline lens, thereby preserving the accommodation. They are preferred over RLE due to their better safety profile, predictability and reversibility.

### Types of phakic intraocular lenses

Phakic IOLs can be divided into 3 sub-types which are enumerated as under-

1. Angle-supported anterior chamber PRLs - haptics are engaged in the angle of the anterior chamber, with the

optic staying in front of the pupil.

2. Iris-fixated anterior chamber PRLs - haptics are fashioned as claws which enclavate the iris-tissue on the opposite side of the pupil and position the pIOL in front of the pupil; and

3. Posterior chamber PRLs - plate haptics position the lens behind the posterior surface of iris and in front of the crystalline lens <sup>9,10</sup>

### History of phakic intraocular lenses (pIOL)

The first pIOL was placed in the anterior chamber angle by Benedetto Strampelli in 1953 for correcting high myopia in a phakic eye. Despite the refractive outcomes seeming to be quite promising, they failed to gain popularity since these lenses were plagued with complications like endothelial decompensation, iritis, pupil distortion, pupillary block and glaucoma. <sup>11</sup>

Overtime, these phakic lens types were progressively improvised by changing their designs, the notable developments amongst them being the iris fixed IOLs by Fechner and Worst.<sup>12</sup> the angle supported AC-IOLs by Baikoff <sup>13</sup> and posterior chamber IOLs with ciliary groove fixation (PC-IOLs) by Fyodorov. <sup>14</sup>

The concept of posterior chamber pIOLs emerged in the late 1980s to overcome the concerns and issues being faced by the iris claw and angle-supported pIOLs.

The initial designs were also associated with complications like anterior sub capsular cataract or pigment dispersion and raised IOP,<sup>15</sup> which were modified eventually to alleviate these concerns.

### Indications

Apart from their usage in correcting ametropia (myopia, hyperopia and astigmatism) which are beyond the range of LVC (residual stromal bed < 250µm), below mentioned conditions are some special situations where pIOLs are indicated.

## 1. Keratoconus (KCN)

**A. Stable KCN** - for correcting myopia and compound myopic astigmatism, if refraction is stable for 6 months and who haven't undergone surgery in the last 2 years.<sup>16,17,18</sup>

**B. Unstable KCN** - Combined collagen cross-linking (CXL), along with Intra-corneal ring segments (ICRS) and toric pIOL implantation is a good option for progressive KCN, wherein the CXL and ICRS offer topographical stability.<sup>18,19</sup> This is especially useful in selected contact lens intolerant cases, before considering corneal transplantation as the final resort. Also, pIOL with deep anterior lamellar keratoplasty (DALK) can be considered for any residual refractive error.<sup>20</sup>

**2. Post Laser Vision Correction (LVC)**- pIOLs can be employed as a safe alternative to laser reoperation in cases where it is contraindicated. It offers the advantage of eliminating spectacle or contact lens (CL) dependency, in addition to providing improved quality of vision with lesser aberrations and better contrast sensitivity.

**3. Post keratoplasty**- pIOLs can be considered for refractive error post-keratoplasty wherein either the patient is CL intolerant or has a contraindication for LVC.<sup>21</sup>

**4. Correction of residual power in pseudophakes**- pIOL implantation has a viable indication in the form of piggyback IOL, either as a primary or secondary surgical procedure.<sup>22,23,24</sup>

**5. Pediatric anisometropia**- High anisometropia in amblyopic children, and those having non-compliance to spectacles/CL who suffer from neurological/behavioural disorders are good candidates for pIOLs.<sup>25</sup>

### Contraindications

- Unstable Refractive Error
- Anterior chamber depth (ACD) <2.8 mm
- Compromised endothelium (ECC < 2500 cells/mm<sup>3</sup> / pre-existing corneal endothelial dysfunction)
- Pre-existing glaucoma
- Anterior chamber angle having Van Herick (VH) grade < II
- Lenticular or capsular opacification
- Iritis/synechiae/pigment dispersion
- Pseudoexfoliation
- People involved in contact sports
- Pregnant /nursing mothers
- General pre-requisites for pIOL planning
- Age > 18 years
- Stable refraction (less than 0.5D change during last 1 year)
- Clear crystalline lens
- Ametropia not suitable for LVC (residual stromal bed thickness < 250µm)
- Unsatisfactory vision with contact lenses or spectacles
- No ocular pathology such as compromised corneal endothelium, rubeosis iridis, iritis, iris atrophy, cataract, glaucoma, and retinal disorders.

## Pre-operative work up

The workup for pIOL includes manifest refraction, cycloplegic refraction, Snellen's uncorrected distance visual acuity (UDVA) and corrected distance visual acuity (CDVA), pupillometry, applanation tonometry, ultrasound anterior chamber depth (ACD) measurement, corneal topography, pachymetry, central endothelial cell count (ECC) and fundus examination.

Certain special considerations before planning pIOLs are enumerated below -

### 1. Specular Microscopy

Specular microscopy measures the endothelial cell density and is a part of routine pre-operative evaluation before planning any pIOL surgery. It identifies patients any potential endothelial dysfunction or cell loss and helps in excluding them from undergoing any refractive surgery.

Loss of corneal endothelial cells is a well documented complication of pIOLs.<sup>27</sup> Endothelial cell density (ECD) less than 2000 in > 40yrs aged people and less than 2500 in 21-40 year age group is a contraindication for pIOL implantation..

Post-operatively, serial scans should be done at each visit to document any endothelial cell loss after pIOL surgery and to address the pathology before corneal decompensation sets in. Many studies have shown decrease in endothelial cell density over time post pIOL implantation.<sup>26,27</sup> For ICL, the guidelines for ECD for a specific age group and anterior chamber depth is given by the company and depicted in the figure 1 as shown below.

Age	Minimum ECD – ACD ≥ 3.0 mm	Minimum ECD – ACD ≥ 3.2 mm	Minimum ECD – ACD ≥ 3.5 mm
21-25	3875 cells/mm <sup>2</sup>	3800 cells/mm <sup>2</sup>	3250 cells/mm <sup>2</sup>
26-30	3425 cells/mm <sup>2</sup>	3375 cells/mm <sup>2</sup>	2900 cells/mm <sup>2</sup>
31-35	3025 cells/mm <sup>2</sup>	2975 cells/mm <sup>2</sup>	2625 cells/mm <sup>2</sup>
36-40	2675 cells/mm <sup>2</sup>	2625 cells/mm <sup>2</sup>	2350 cells/mm <sup>2</sup>
41-45	2350 cells/mm <sup>2</sup>	2325 cells/mm <sup>2</sup>	2100 cells/mm <sup>2</sup>
> 45	2075 cells/mm <sup>2</sup>	2050 cells/mm <sup>2</sup>	1900 cells/mm <sup>2</sup>

### 2. Optical Biometry (Lenstar/ IOL master)

Lenstar 900 (Haag-Streit AG, Koeniz, Switzerland) which works on the principle of optical low coherence reflectometry and the IOLMaster 700 (Carl Zeiss Meditec AG, Jena, Germany) which is based on swept-source optical coherence tomography (SS-OCT) technology are the common biometers in practice today.

Biometry helps in determination of various parameters like axial length (AL), anterior chamber depth (ACD), white to white (WTW) and central corneal thickness (CCT), and also in identifying abnormalities of the anatomical structure. It is one of the mainstay for evaluating the refractive status of the eye and for calculating the IOL power. The accuracy of the pIOL calculation is dependent on the accuracy of the biometry measurements.<sup>28</sup>

### 3. Corneal topography and tomography

Topography or tomography (usually Pentacam) is an integral part of the pIOL planning since-

- it gives us the steep or flat keratometry values with their respective axes.
- it helps in ruling out progressive ectasias and suspects.
- gives internal anterior chamber depth (ACD) which is a measure of the distance between the corneal endothelium and anterior lens capsule. ACD less than 2.8mm is a contraindication for pIOL implantation.
- gives the white-to-white measurement, which is imperative to surgical planning.
- In KCN, topographical stability is to be ensured before undergoing pIOL implantation, which is indicated by stable scans between 2 visits 6 months apart, with no history of any previous surgery in the past 2 years. For post-cross linking patients, one can plan pIOL surgery if stable refraction has been attained for three consecutive visits over a period of 1 year. Additional criteria for pIOL implantation in keratoconic eyes includes a centralised cone, clear central cornea and keratometry values  $\leq 52.00$  D for optimum results.<sup>29</sup>

### 4. White to White (WTW)

WTW is needed for correct sizing of the posterior chamber pIOL. It's the horizontal corneal diameter from the nasal to temporal limbus at 0 - 180 degrees. It varies between 10mm and 13.5mm for ICL as well as IPCL. It can be measured by means of a calliper (manual or digital), corneal topographers/ tomographers (Pentacam or Orbscan) or optical biometers.

The OrbscanIIz corneal topography system (Orbscan, Inc, Salt Lake City, UT, USA) which works on the principle of scanning slit technology, gives the horizontal WTW values. These values have been found to be highly reproducible and accurate.<sup>30</sup>

Objective measurements are considered as being more reliable than subjective measurements.<sup>31</sup> The average of 3 consecutive topography scans is to be used for IOL power

calculation. A combination of manual and automated method has been shown to be the most accurate as per studies.<sup>32</sup>

It is recommended that automated measurement by one instrument and manual verification with callipers should be done for appropriate sizing. It is estimated that the ICL size should be 1.1mm higher than the WTW for ACD<3.5mm and 1.6mm more than WTW for eyes with ACD >3.5mm as per the company recommendations. (Figure 2)

### 5. Pupillometry

Measurements must be done for photopic as well as scotopic conditions. The static pupil diameter can be measured by OrbscanII topographer, Bausch & Lomb, Sirius topographer, ASOCT and other devices. Dynamic pupillometry can be done with Osiris-T and other devices.

The large size of the scotopic pupil could be responsible for symptoms like glares and halos in certain patients. There shouldn't be any iris anomaly or pupil dysfunction. Ideally mesopic pupil size of <5.0–6.0 mm is preferable since larger pupil diameter helps to reduce the incidence of glare and halos.

### 6. Ultrasound Biomicroscopy (UBM)

The circumferential depression which is bounded anteriorly by the posterior surface of iris and posteriorly by the anterior surface of ciliary processes is known as the ciliary sulcus. UBM uses a 50 MHz ultrasound probe to determine the Sulcus-to-Sulcus distance (STS), which aids in the correct sizing of the pIOL. It helps to calculate the predicted vault size post ICL implantation. Since the haptic footplates are supported in the ciliary sulcus in case of posterior chamber pIOL, the horizontal sulcus to sulcus (STS) diameter measurement has been advocated as being better for posterior chamber phakic intraocular lens (pIOL) calculations. There is a lack of general consensus as to which parameter holds more importance for appropriate sizing of pIOLs.

In a study by Pop et al, it was found that sulcus measurements with UBM had greater variation than that of WTW with calipers, concluding that UBM

may not be the best method of measuring the sulcus for ICL sizing.<sup>33</sup> On the other hand, in few studies the WTW technique was regarded as inaccurate in predicting the horizontal diameter of the ciliary sulcus and revealed the UBM to be more suitable and predictable for ICL planning.<sup>34,42</sup> The UBM also enables in diagnosing iridociliary cysts and discerning their morphology before surgery.<sup>35</sup> Analysis of several studies have shown no significant correlation between assessment of WTW and diameter of STS.<sup>33,36,37,38</sup>

### 7. Aberrometry



Along with the measurement

White to White (mm)	ACD (mm)	Recommended ICL Length
<10.5	All	Not Recommended
10.5-10.6	$\leq 3.5$	Not Recommended
10.5-10.6	>3.5	12.1
10.7-11.0	All	12.1
11.1	$\leq 3.5$	12.1
11.1	>3.5	12.6
11.2-11.4	All	12.6
11.5-11.6	$\leq 3.5$	12.6
11.5-11.6	>3.5	13.2
11.7-12.1	All	13.2
12.2	$\leq 3.5$	13.2
12.2	>3.5	13.7
12.3-12.9	All	13.7
$\geq 13$	All	Not Recommended

of the aberrations, iTrace (Tracey Technologies Corp., Houston, TX, USA) also measures the dysfunctional lens index (DLI), which is of pivotal importance in the presbyopic age group. It measures the performance of the lens objectively while taking into account the pupil size, contrast sensitivity and internal HOAs. The presence of DLI should be ruled out pre-operatively and in the presbyopic age group. The is an aberrometer that works on the principle of ray tracing to measure the total, corneal and internal aberrations. pIOL implantation is known to induce higher order aberrations (HOA) (primarily negative spherical aberrations).<sup>28</sup> These are attributable to the pIOL and the corneal incisions. the iTrace also measures the Dysfunctional lens index (DLI) which is an objective measure of the lens performance based pupil size, contrast sensitivity and internal HOAs assessment. DLI value ranges from 0 (poor) to 10 (excellent). A DLI value of <5 suggests severely impaired lens function, 5-7 implies moderate impairment and a DLI >7 is considered normal. [39] An impaired DLI warrants a refractive lens exchange surgery instead of a pIOL.

### ICL VS IPCL

Table 1- Types of posterior chamber pIOLs.

POSTERIOR CHAMBER PHAKIC IOL	Implantable Collamer lens (ICL)	Implantable Phakic Contact Lens (IPCL)
<b>MATERIAL</b>	Collamer Hydrophilic porcine collagen Hydroxyethyl methacrylate copolymer	Hydrophilic acrylic copolymer material
<b>SIZE</b>	12.1,12.6,13.2, 13.7	11mm to 14mm (increments in 0.25mm steps)
<b>COMPANY</b>	Visian ICL (StarSurgicals co.)	Care Group, Vadodara, India.
<b>REFRACTIVE CORRECTION RANGE</b>	+10D to -20DS	+15D to -30DS
<b>CYLINDER</b>	6DC	10DC
<b>HAPTIC DESIGN</b>	4 footplate haptics	6 footplate haptics
<b>OPTIC</b>	4.8 to 5.8 mm optic, (6.1 with EVO +)	6.6mm Optic customizable up to 7.5mm
<b>PECULIAR FEATURE</b>	Comes as a single lens	Comes with a backup lens.
<b>REPRESENTATIVE IMAGE</b>		

### 8. Anterior segment optical coherence tomography (ASOCT)

Anterior segment optical coherence tomography offers a rapid and non-invasive means for structural imaging of the anterior segment of the eye. It provides accurate and repeatable values of crystalline lens rise (CLR), anterior chamber depth, iris anatomy and angle to angle diameter (ATA). The ATA measurements were found to have higher reproducibility than the WTW measurements on AS-OCT, adding more value to it as a predictor of the postoperative vault.<sup>40</sup>

#### STS vs WTW

Several studies have concluded that WTW, ATA and STS do not highly correlate<sup>37</sup> but yet at the same time, some authors have found varying degrees of correlation.<sup>41</sup>

Neither clinically meaningful nor statistically significant difference in achieved vault differentiates WTW and STS based sizing methodologies. However, WTW based sizing has provided the best predictability of vault, and thus sizing based on WTW remains the most popular and best-studied technique.<sup>42</sup>




## 1. ICL

Implantable collamer lenses (ICL/Toric ICL), being the first FDA approved posterior chamber pIOL is produced by Swiss Staar company. It is the most widely used posterior chamber phakic IOL, which is made up of 60% poly-hydroxy-ethyl-methacrylate (HEMA), water (36%), benzophenone (3.8%) and (0.2%) porcine collagen. The porcine collagen is responsible for providing immune privilege, lighter weight, hydrophilicity and allowing for better exchange of gas and nutrients. It is 7.5 – 8.00 mm wide, 12.1- 13.7 mm long with an optic size ranging from 4.9 to 5.8 mm (6.1 mm with the EVO+ Visian ICL). The thickness of ICL increased with refractive dioptre and ranged from 1.19 mm to 1.09 mm according to the refractive dioptre. It has gone through 5 generations with the first one having poor predictability and lens design. With the V2 and V3, incidence of glaucoma reduced but incidence of cataract development was

up to 5%, majorly due to the inadequate vaulting. This was improved upon by the V4 design which provided more space between the ICL and the crystalline lens to prevent cataract formation. This was further improved by the V4c (EVO Visian ICL) which had a central ‘aqua port’ to allow aqueous humour flow in the anterior segment and eliminate the need for of a peripheral iridectomy though did not significantly affect the visual quality.<sup>43</sup>

The Evo+ Visian ICL is the V5 version having a larger optic size of 6.1 mm (compared to a maximum of 5.8 mm for the EVO Visian ICL) which has been developed for patients who have larger meso-scotopic pupil diameters. The 6.1mm optic size of this ICL produces an optical zone of almost 7mm at the level of cornea. This larger optic size helps in reducing glares and haloes particularly during the night time. This is especially important in young myopes as they have a larger pupil size.

Table 2 - comparison of the different designs of ICL

Feature	ICL (V4)	Visian (V4b)	Visian (V4c) with central flow technology
Storage solution	NaCl (equivalent to BSS once hydrated in the eye)	BSS	BSS
Axis alignment marks	2 diamond shaped marks	2 Straight lines	Same as V4b
Full thickness holes	None	2 peri-optic (aides in alignment and facilitate visco removal)	Same as V4b with additional <u>central optic port</u> eliminating the need for a PI
Lens orientation landmarks	2 square diagrams on footplate (distal and proximal)	Full thickness holes on foot plates (distal and proximal)	Same as V4b
Diopter range for refractive correction	ICM -3 to -23 DS VTICM -3 to -23DS with +1 to +6 DC (no mixed) ICH +3 to + 21DS VTICH- none	VICM -3 to -18 DS (0.5D steps) VICM -0.5 to -3 DS (-0.25 steps) VTICM -0.5 to -18DS with +0.5 to +6 DC(Including mixed astigmatism) VICH +3 to +10DS (0.5D steps) VICH +0.5 to +3 DS (0.25D steps) VTICH +0.5 to +10 DS with +0.5 to +6 DC (Including plano-positive toric)	VICM - Same as V4b VTICMO -0.5 to -18 DS with +0.5 to +6DC (Including mixed astigmatism) VICH - N/A VTICH – N/A
Representative image			



## 2. IPCL

The Implantable Phakic Contact Lens (IPCL, Care group Sight Solutions, India) is the other popular posterior chamber pIOL having a significant economic advantage to the ICL. It also treats higher degrees of ametropia than the ICL. It is made of reinforced hybrid hydrophilic acrylic material with 6 haptics and large central 6.6 mm optic diameter modifiable to 7.25mm as per the size of the pupil. It comes in size ranging from 11 to 14mm with 0.25mm step differences for better sizing. The V1 lacked a central hole which was corrected for in the V2.0 of the IPCL. The V2.0 has a 380µm central hole for aqueous circulation and an aspheric optic zone. Sachdev G et al. found IPCL to be a safe, effective and economically viable option to correct myopia and myopic astigmatism.<sup>44</sup> Bianchi R et al. found

IPCL V2.0 to be safe and effective after 6 months of follow up.<sup>45</sup> Positioning of the IPCL inside the eye is depicted by figure 10.

Both ICL and IPCL now also come in presbyopia correcting variants. The EVO VIVA ICL comes with an aspheric EDOF optic for improved near vision and depth of focus for patients over the age of 40 years. The IPCL V2.0 Presbyopic lens also comes with a patented aspheric refractive – diffractive optic profile with a presbyopic add up to +4D. All of these lenses are available in toric variants as well.

The lower limit of safe vault is approximately 50 to 200 µm, and the upper limit is approximately 750 to 1000 µm as long as the anterior chamber angle structure and function remains normal.<sup>46</sup>

## ORDERING AN ICL

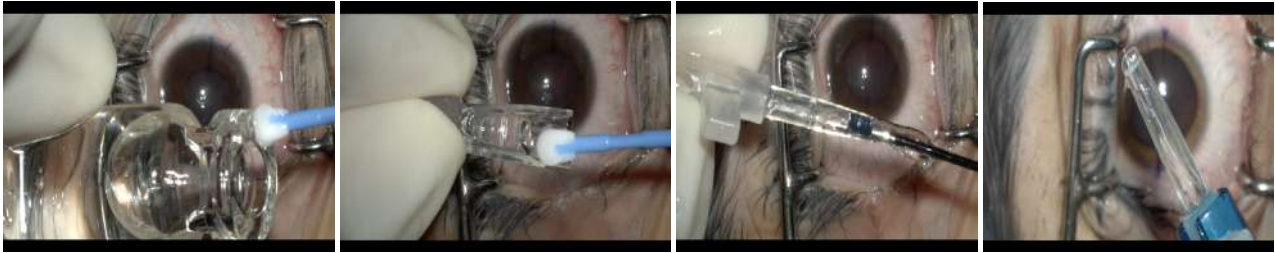
Based on the work up, ICL is ordered using the company calculators.

Figure 3 showing inputs required for ordering ICL from online STAAR SURGICAL calculator

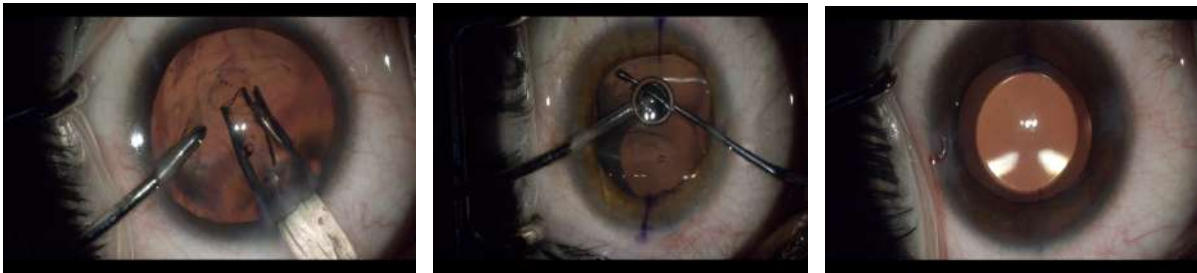
## Surgical steps of ICL

- Marking -Figure 4 showing toric marking in case of a Toric ICL (TICL)





- **ICL loading-** Figure 5 showing ICL retrieval from the glass vial in which it is stored. This is done with the help of a fully hydrated foam tip; **Figure 6** shows placement of ICL into the viscoelastic filled insertion cartridge, so that both the lateral edges are underneath the upper lip of the cartridge; **Figure 7** - Using specially designed MST ICL grasping forceps to pull the ICL into the cartridge, in a manner of pulling it in the opposite direction, so as to place the leading edge of the ICL at the cartridge tip. Meanwhile, the trailing end of the ICL is brought completely underneath the enclosed portion of the insertion cartridge.



**ICL insertion- Figure 9** - With the insertion cartridge (bevel down) placed at the main wound, ICL is gently delivered into the viscoelastic filled anterior chamber; **Figure 10** - Once the ICL is completely in the anterior chamber, the ICL haptics are placed underneath the iris with the help of an ICL manipulator. **Figure 11** - Once all the four haptics are tucked in below the iris, the ICL is rotated to align it with the final axis (in case of a TICL).

## Outcomes and complications

### 1. Effectiveness

Numerous studies in the past have shown that all three types of pIOLs have excellent results with regard to uncorrected visual acuity, distance corrected visual acuity and residual refractive error. 48

There have been multiple studies to assess the patient satisfaction in terms of spectacle independence and improvements in quality of life. While the outcomes have been reported to be excellent, there have been a few cases with bothersome side effects of night vision symptoms like glare and halos in the early post-operative period. 47,49 Several questionnaires like the Quality of life Impact of Refractive Correction (QIRC), Near Acuity Visual Questionnaire (NAVQ) (activity limitation) show slightly superior results in assessment of refractive surgery. 50

### 2. Sizing related complications

These constitute the most common cause for pIOL explantation.<sup>28</sup> Thus the importance of getting the right size cannot be over-emphasized. The issues with improper sizing are as underlined below in table 4.

Large sized PIOL	Small sized PIOL
<ul style="list-style-type: none"> <li>• High post-operative vault</li> <li>• Endothelial cell loss</li> <li>• Pigment dispersion</li> <li>• Raised IOP</li> <li>• Acute Angle closure attack</li> </ul>	<ul style="list-style-type: none"> <li>· Low Post- operative vault</li> <li>· Cataract</li> <li>· Rotation of the pIOL</li> </ul>

Table 4 - List of issues with improper sizing of pIOL

pIOL explantation shall be considered in case of high vault after confirmation of angle status by gonioscopic evaluation and due clinical correlation.<sup>46</sup>

3. Endothelial cell function-The endothelial cell count is known to decrease with aging and after any intra-ocular surgery as well. The intraocular presence of a pIOL leads to chronic endothelial cell loss.<sup>15,51,52</sup> There are various theories that have postulated the cause of this endothelial cell loss, some of which are - (i) close proximity between endothelium and pIOL (ii) pIOL-related change in aqueous humor dynamics or (iii) chronic inflammatory response at a sub-clinical level.<sup>15</sup> This mandates the need for a periodic specular microscopy examination post-surgery.

4. Intraocular pressure-Conditions like retained viscoelastic substance, pupillary block, chronic inflammation and pigment dispersion have been considered as the underlying cause of raised IOP post operatively.<sup>10</sup>

5. Cataracts-The propensity to develop cataracts is per se higher in myopes. The risk of cataract formation is present even in an uneventful surgery, owing to the presence of underlying inflammation due to the material of pIOL.<sup>53</sup> This is attributed to the lens position being in close proximity of the crystalline lens. In the presence of an pre-operative sizing discrepancy, frequent contact is induced between the pIOL and crystalline lens. This causes development of anterior sub-capsular cataract due to the underlying friction.<sup>10</sup> A change in the aqueous humor dynamics has also been highlighted by some studies as a resultant factor.<sup>54</sup>

6 Glares and Halos-Few patients can experience these in the early post-operative period which tend to gradually subside with time. The occurrence of these photopic phenomenon is dependent on size and position of the pIOL optic in relation to the pupillary size.<sup>10</sup>

7. Rotation of toric pIOLs-This depends on the sizing of the posterior chamber pIOLs. Smaller size pIOLs have the possibility of rotation due to availability of space in the ciliary sulcus.

8. Pigment Dispersion Syndrome-There can be release of iris pigments in the aqueous humor due to rubbing of the optic-haptic junction on the posterior surface of the iris.

9. Retinal complications-High myopia is frequently associated with retinal complications due to continual stretching and thinning of the retina. Posterior segment complications are rare after ICL implantation but the importance of dilated vitreoretinal assessment before and after the procedure cannot be over-emphasized.<sup>55</sup>

10. Pupillary Block/Malignant Glaucoma-pIOL implantation increases the predilection of angle closure glaucoma and raised IOP due to their position as they might push the iris forward and precipitate an acute pupillary block. This risk has been significantly reduced with the incorporation of the central hole in the newer models of pIOLs. Surgical PIs were recommended with anterior chamber, iris supported and posterior chamber pIOLs before the central hole designs were introduced.

11. Decreased amplitude of accommodation-Although there is paucity of literature for this, but there have been few cases of decreased amplitude of accommodation post pIOL implantation. This might be attributable to the ciliary muscles interaction with the pIOL in the sulcus.<sup>56</sup>

## Conclusion

- pIOLs are a safe and an effective tool for the surgical management of high refractive error.
- With the improvements in materials and designs, the rates of complications have
- significantly reduced.
- Sizing related dilemma still remain to be the only primary concern.

**Financial Disclosure and support- None**

**Conflicts of Interest- None**

---

## References

1. Naidoo K.S., Leasher J., Bourne R.R. Global vision impairment and blindness due to uncorrected refractive error, 1990–2010. *Optom Vis Sci.* 2016;93(3):227–234.
2. Kleinstejn RN, Jones LA, Hullett S, et al. . Refractive error and ethnicity in children. *Arch Ophthalmol* 2003;121:1141–7. 10.1001/archophth.121.8.1141
3. Foster PJ, Jiang Y. Epidemiology of myopia. *Eye (Lond)* 2014;28:202–8. 10.1038/eye.2013.280
4. Gilmartin B. Myopia: precedents for research in the twenty-first century. *Clin Experiment Ophthalmol* 2004;32:305–24. 10.1111/j.1442-9071.2004.00831.
5. Fricke T.R., Holden B.A., Wilson D.A. Global cost of correcting vision impairment from uncorrected refractive error. *Bull World Health Organ.* 2012;90(10):728–738
6. Smith T.S., Frick K.D., Holden B.A., Fricke T.R., Naidoo K.S. Potential lost productivity resulting from the global burden of uncorrected refractive error. *Bull World Health Organ.* 2009;87(6):431–437.
7. Guñell JL, Rodriguez-Arenas AF, Gris O, Malecaze F, Velasco F. Phacoemulsification of the crystalline lens and implantation of an intraocular lens for the correction of moderate and high myopia: four-year follow up. *J Cataract Refract Surg* 2003; 29:34–8.
8. Fernandez-Vega L, Alfonso JF, Villacampa T. Clear lens extraction for the correction of high myopia. *Ophthalmology* 2003; 110:2349–54.

9. Guell JL, Morral M, Kook D, Kohnen T. Phakic intraocular lenses part 1: Historical overview, current models, selection criteria, and surgical techniques *J Cataract Refract Surg.* 2010;36:1976–93
10. Kohnen T, Kook D, Morral M, Guell JL. Phakic intraocular lenses: Part 2: Results and complications *J Cataract Refract Surg.* 2010;36:2168–94
11. Praeger, D.L., A. Momose, and L.L. Muroff, Thirty-six month follow-up of a contemporary phakic intraocular lens for the surgical correction of myopia. *Ann Ophthalmol*, 1991. 23(1): p. 6-10.
12. Worst JG, van der Veen G, Los LI. Refractive surgery for high myopia. The Worst-Fechner biconcave iris claw lens. *Doc Ophthalmol.* 1990 Oct;75(3-4):335-41.
13. Baikoff G, Arne JL, Bokobza Y, Colin J, George JL, Lagoutte F, Lesure P, Montard M, Saragoussi JJ, Secheyron P. Angle-fixated anterior chamber phakic intraocular lens for myopia of -7 to -19 diopters. *J Refract Surg.* 1998 May-Jun;14(3):282-93.
14. Shen Y, Zhou TA, DU CX, Wang Y, Xia JH. [Posterior chamber phakic intraocular lens for correction of extreme myopia]. *Zhonghua Yan Ke Za Zhi.* 2007 Nov;43(11):1000-4.
15. Jonker SMR, Berendschot TTJM, Ronden AE, Saelens IEY, Bauer NJC, Nuijts RMMA. Long- Term Endothelial Cell Loss in Patients with Artisan Myopia and Artisan Toric Phakic Intraocular Lenses: 5- and 10-Year Results. *Ophthalmology* 2018;125(4):486–94.
16. Alio JL, Sanz-Diez P. Phakic Intraocular lenses in Keratoconus. *Int J Kerat Ect Cor Dis.* 2015;4:103–106.
17. Kamiya K, Shimizu K, Kobashi H, Igarashi A, Komatsu M, Nakamura A, et al. Three-year follow-up of posterior chamber toric phakic intraocular lens implantation for the correction of high myopic astigmatism in eyes with keratoconus. *Br J Ophthalmol.* 2015;99:2:177–183.
18. Naoko Kato, MD, Ikuko Toda, MD, Yoshiko Hori-Komai, MD, Chikako Sakai, BS, Hiroyuki Arai, MD, Kazuo Tsubota., MD Phakic Intraocular Lens for Keratoconus; *AJO.* 2011 Mar;118(3):605–605-e2
19. Izquierdo L, Jr, Henriquez MA, McCarthy M. Artiflex phakic intraocular lens implantation after corneal collagen cross-linking in keratoconic eyes. *J Refract Surg.* 2011;27:482–487.
20. Hashem AN, El Danasoury AM, Anwar HM. Axis alignment and rotational stability after implantation of the toric implantable collamer lens for myopic astigmatism. *J Refract Surg.* 2009;25:S939–S943
21. Alfonso JF, Lisa C, Abdelhamid A, Montés-Micó R, Poo-López A, Ferrer-Blasco T. Posterior chamber phakic intraocular lenses after penetrating keratoplasty. *J Cataract Refract Surg.* 2009;35:1166–73. doi: 10.1016/j.jcrs.2009.02.027
22. Chiou AG, Bovet J, de Courten C. Pseudophakic ametropia managed with a phakic posterior chamber intraocular lens. *J Cataract Refract Surg.* 2001;27:1516–1518.
23. Falzon K, Stewart OG. Correction of undesirable pseudophakic refractive error with the Sulcoflex intraocular lens. *J Refract Surg.* 2012;28:619.
24. Kahraman G, Amon M. New supplementary intraocular lens for refractive enhancement in pseudophakic patients. *J Cataract Refract Surg.* 2010;36:1090–1094.
25. Tychsen L, Hoekel J, Ghasia F, Yoon-Huang G. Phakic intraocular lens correction of high ametropia in children with neurobehavioral disorders.
26. Edelhauser HF, Sanders DR, Azar R, Lamielle H. Corneal endothelial assessment after ICL implantation. *J Cataract Refract Surg* 2004;30(3):576–83
27. Shaaban YM, Badran TAF. Three-Year Effect of Phakic Intraocular Lenses on the Corneal Endothelial Cell Density. *Clin Ophthalmol.* 2020;14:149-155. Published 2020 Jan 20. doi:10.2147/OPHTH.S236041
28. Deshpande, Kalyani; Shroff, Rushad; Biswas, Partha; Kapur, Kamal; Shetty, Naren; Koshy, Ann Sarah; Khamar, Pooja. Phakic intraocular lens Getting the right size. *Indian J Ophthalmol* 68(12):2880–7.
29. Kummelil MK, Hemamalini MS, Bhagali R, Sargod K, Nagappa S, Shetty R, et al. Toric implantable collamer lens for keratoconus. *Indian J Ophthalmol* 2013;61(8):456–60.
30. Martín R, Izquierdo M, De Juan V, Rodríguez G, Fernández I. Repeatability and reproducibility of Orbscan II. *Optom Reports* 2012;2(1):1.
31. Baumeister M, Terzi E, Ekici Y, Kohnen T. Comparison of manual and automated methods to determine horizontal corneal diameter. *J Cataract Refract Surg* 2004;30(2):374–80.
32. Naguib MA, Azab H, Ali NH. A Study to Reach the Proper Measurement of the White to White Diameter Using both the Caliper and IOL Master for ICL Suitable Size. 2017;41–9.
33. Pop M, Payette Y, Mansour M. Predicting sulcus size using ocular measurements. *J Cataract Refract Surg.* 2001;27(7):1033–1038.
34. Oh J, Shin HH, Kim JH, Kim HM, Song JS. Direct measurement of the ciliary sulcus diameter by 35-megahertz ultrasound biomicroscopy. *Ophthalmology.* 2007;114(9):1685–1688.

35. Pujari A, Swamy DR Iridociliary epithelial cyst Case Reports 2017;2017:bcr-2017-222126.
36. Reinstein DZ, Archer TJ, Silverman RH, Rondeau MJ, Coleman DJ. Correlation of anterior chamber angle and ciliary sulcus diameters with white-to-white corneal diameter in high myopes using artemis VHF digital ultrasound J Refract Surg. 2009;25:185–94
37. Werner L, Izak AM, Pandey SK, Apple DJ, Trivedi RH, Schmidbauer JM. Correlation between different measurements within the eye relative to phakic intraocular lens implantation J Cataract Refract Surg. 2004;30:1982–8
38. Fea AM, Annetta F, Cirillo S, Campanella D, De Giuseppe M, Regge D, et al Magnetic resonance imaging and Orbscan assessment of the anterior chamber J Cataract Refract Surg. 2005;31:1713–8
39. Kaweri, Luci; Wavikar, Chandrashekar<sup>1</sup>; James, Edwin<sup>2</sup>; Pandit, Payal; Bhuta N. Review of current status of refractive lens exchange and role of dysfunctional lens index as its new indication. Indian J Ophthalmol 2020;68(12):2797–803
40. Igarashi A, Shimizu K, Kato S, Kamiya K. Predictability of the vault after posterior chamber phakic intraocular lens implantation using anterior segment optical coherence tomography. J Cataract Refract Surg 2019;45(8):1099–104.
41. David P Piñero, Ana Belén Plaza Puche JLA. Ciliary sulcus diameter and two anterior chamber parameters measured by optical coherence tomography and VHF ultrasound. J Refract Surg 11(11):1017–25.
42. Packer M. The implantable collamer lens with a central port: Review of the literature. Clin. Ophthalmol.2018;12(12):2427–38.
43. Tian Y, Jiang HB, Jiang J, Wen D, Xia XB, Song WT, et al. Comparison of Implantable Collamer Lens Visian ICL V4 and ICL V4c for high myopia: A cohort study. Med (United States) 2017;96(25):1–5.
44. Sachdev G, Ramamurthy D. Long-term safety of posterior chamber implantable phakic contact lens for the correction of myopia. Clin Ophthalmol 2019;13:137–42.
45. Bianchi GR. Initial Results From a New Model of Posterior Chamber Implantable Phakic Contact Lens: IPCL V2.0. Med hypothesis, Discov Innov Ophthalmol J 2019;8(2):57–63.
46. Packer M. Meta-analysis and review: effectiveness, safety, and central port design of the intraocular collamer lens. Clin Ophthalmol. 2016 Jun 9;10:1059-77. doi:10.2147/OPHTH.S111620.
47. Kobashi H, Kamiya K, Igarashi A, Matsumura K, Komatsu M, Shimizu K. Long-term quality of life after posterior chamber phakic intraocular lens implantation and after wavefront-guided laser in situ keratomileusis for myopia. J Cataract Refract Surg 2014;40(12):2019–24.
48. Jonker SMR, Berendschot TTJM, Saelens IEY, Bauer NJC, Nuijts RMMA. Phakic intraocular lenses: An overview. Indian J Ophthalmol. 2020;68(12):2779-2796. doi:10.4103/ijo.IJO\_2995\_20
49. Jeong A, Hau SCH, Rubin GS, Allan BDS. Quality of life in high myopia before and after implantable Collamer lens implantation. Ophthalmology 2010;117(12):2295–300.
50. Kandel H, Khadka J, Lundström M, Goggin M, Pesudovs K. Questionnaires for measuring refractive surgery outcomes. J Refract Surg 2017;33(6):416–24.
51. Shaaban YM, Badran TAF. Three-Year Effect of Phakic Intraocular Lenses on the Corneal Endothelial Cell Density. Clin Ophthalmol. 2020 Jan 20;14:149-155. doi: 10.2147/OPHTH.S236041. PMID: 32021080; PMCID: PMC6980859.
52. Ostovic M, Hofmann C, Klaproth OK, Kohnen T. Corneal decompensation and angle-closure glaucoma after upside-down implantation of an angle-supported anterior chamber phakic intraocular lens. J Cataract Refract Surg. 2013 May;39(5):806-9. doi: 10.1016/j.jcrs.2013.02.005. Epub 2013 Mar 26. PMID: 23540572.
53. Pérez-Santonja JJ, Iradier MT, Benítez del Castillo JM, Serrano JM, Zato MA. Chronic subclinical inflammation in phakic eyes with intraocular lenses to correct myopia. J Cataract Refract Surg. 1996 Mar;22(2):183-7. doi: 10.1016/s0886-3350(96)80216-1. PMID: 8656382.
54. Fernández-Vigo JI, Marcos AC, Agujetas R, Montanero JM, Sánchez-Guillén I, García-Feijóo J, et al. Computational simulation of aqueous humour dynamics in the presence of a posterior-chamber versus iris-fixed phakic intraocular lens. PLoS One 2018;13(8):1–16.
55. Bamashmus MA, Al-Salahim SA, Tarish NA, et al. Posterior vitreous detachment and retinal detachment after implantation of the Visian phakic implantable collamer lens. Middle East Afr J Ophthalmol. 2013;20(4):327-331. doi:10.4103/0974-9233.120019
56. Hernández-Rodríguez CJ, Piñero DP. A systematic review about the impact of phakic intraocular lenses on accommodation. J Optom 2020;13(3):139–45.

## Original article

# Safety and efficacy of Intracameral Mydriatics: Lignocaine and Epinephrine in manual small Incision cataract surgery and their effect on blood pressure and heart rate

Dr Suresha Rajappa<sup>1</sup>, Dr Gunashree KN<sup>2</sup>

<sup>1,2</sup>Department of Ophthalmology, JJM Medical College, Davangere

### Abstract

**Purpose:** To evaluate efficiency of induction and maintenance of mydriasis by intracameral mydriatic solution (lignocaine1%+epinephrine0.1%) and their effect on heart rate and blood pressure, postoperative complications in manual small incision cataract surgery (MSICS). **Settings and Design:** This prospective interventional study included 60 subjects posted for MSICS for age related cataract. **Methods and Material:** Mydriasis was achieved intra-operatively using intracameral mydriatic solution. Pupillary diameter, blood pressure, heart rate were measured at different stages of surgery. Postoperative corneal edema, AC inflammation, visual acuity, endothelial cell count was noted. **Results:** Average preoperative pupillary diameter was  $3.0 \pm 0.689$ mm. Pupillary diameter 30seconds post-intracameral mydriatic solution was  $7.35 \pm 1.2$ mm and by the end of surgery was  $5.53 \pm 1.171$ mm. Preoperative and post intracameral mydriatics systolic blood pressure/Diastolic blood pressure were  $131.43 \pm 15.873/79.47 \pm 11.909$ mmhg and  $133.40 \pm 17.595/78.33 \pm 10.730$ mmhg respectively. Preoperative and post-intracameral mydriatic solution heart rate were  $77.27 \pm 10.499$ bpm and  $75.53 \pm 13.760$ bpm respectively. 89.4% cases achieved adequate dilatation with intracameral mydriatics. 11.6% cases did not achieve adequate dilatation. The postoperative AC inflammation, corneal oedema, visual acuity outcome and endothelial cell loss were similar to standard MSICS with topical mydriatics. **Conclusions:** Intracameral lignocaine1% + epinephrine 0.1% can induce adequate and sustained mydriasis required for safe MSICS. They do not affect systemic haemodynamics.

**Key-words:** Intracameral mydriatics, Lignocaine, Epinephrine, Haemodynamics.

### Introduction

Manual small incision cataract surgery (MSICS), is widely practised form of cataract surgery as it requires minimal infrastructure and is also cost effective. Adequate pupillary dilation is an essential pre-requisite for a surgeon to successfully carry out cataract surgery without complications. Poor bioavailability of topical mydriatics leads to delay in the onset of mydriasis due to their low corneal permeability.<sup>1</sup> Longer preparation time and repeated eye drops instillation needed to make up for the low permeability of topical mydriatics, are likely to cause ocular surface toxicity. Cardiovascular side effects like significant increase in both systolic and diastolic blood pressure and reflex bradycardia occur, due to systemic absorption via the nasal mucosa and conjunctival vessels.<sup>2</sup> The waiting time for pupillary dilation is sometimes longer than the surgical procedure. As newer methods to reduce the operative time for the patient are gaining importance, there is a need to adapt newer, faster, safer modalities of pupillary dilation like intracameral mydriatics. Multiple studies have proven induction and sustained mydriasis with intracameral mydriatics in phacoemulsification.<sup>3,4</sup> Limited studies have been done on the safety and efficacy of intracameral mydriatics in manual SICS. Hence in this study, we have assessed the induction and sustainability of pupillary mydriasis by intracameral mydriatics (lignocaine 1% and epinephrine 0.1%) in MSICS and their effect on blood pressure and heart rate.

**Methods;** This prospective, cross sectional interventional study was done in a tertiary eye care centre in South India after approval by the institutional ethical committee and as per Helsinki declaration. A total of 60 patients of both sexes with age related cataract, posted for MSICS were included in the study after obtaining written informed consent from the patient and as per the inclusion and exclusion criteria mentioned below. Inclusion criteria are patients with age >50yrs, with age related cataract whose pupillary dilatation >6mm with topical mydriatics during preoperative evaluation, one day prior to the surgery. Exclusion criteria include patients with pupillary disorders, intraocular pathologies that affect the outcome of surgery, h/o use of alpha blockers/non-steroidal anti-inflammatory drugs/prostaglandins/miotics, h/o previous intraocular surgery in the same eye, blood pressure >140/90mmhg during preoperative evaluation with or without Ischaemic heart diseases.

On the pre-operative day, all patients underwent thorough ocular examination. Pupillary dilation achieved using topical mydriatics was measured with Castroviejo surgical calliper under slit lamp. Cataract grading was done by observing the colour of nucleus on slit-lamp examination and was graded as NS1 for greenish yellow, NS2 for yellow, NS3 for amber, and NS4 for brown, reddish and black brown. Mature cataract cases were also included in the study. Endothelial count was analysed by specular microscopy using Tomey EM-300 specular microscope. All surgeries were performed by a single experienced surgeon using the same technique of MSICS. On the day of surgery, topical mydriatic was not instilled to the operating eye and was kept undilated. Preoperative pupillary diameter was measured under slit lamp and recorded. Blood pressure (BP), Pulse rate (PR) were recorded at 4 stages using a digital sphygmomanometer as explained below. Preoperative blood pressure (BP1) and pulse rate (PR1) were recorded. Under all aseptic precautions, peribulbar anaesthesia was achieved with a solution of 2% lidocaine and 0.5% bupivacaine, with hyaluronidase added at 7.5 turbidity units/ml to the solution. Intraoperative pupil diameter (P) was measured with Castroviejo surgical calipers under fixed microscope illumination and magnification at different stages of surgery. After block, P1, BP2, PR2 were measured. Following superior rectus bridge suture, superior conjunctival peritomy was done, sclerocorneal tunnel was made. Side port entry was made at 9 O'clock. 0.2ml of mixture of 2ml preservative free lignocaine hydrochloride 1% (Oculan, Sunways Pvt Ltd., India) + 1ml intracameral adrenaline 1:1000 (Epitrate, Sunways Pvt Ltd., India) was injected into AC through the side-port and left for 30secs. After 30secs, P2, BP3, PR3 were measured and trypan blue dye was injected into AC. Dye was washed off with saline and OVD (hydroxypropyl methyl cellulose 2%) was injected. Continuous curvilinear capsulorhexis was made using 26G cystitome. After hydrodissection, nucleus was prolapsed into AC and delivered using sandwich technique with wire vectis and dialer. Cortical wash was given using Simcoe irrigation aspiration cannula. P3 was measured. IOL was placed into the capsular bag/sulcus depending on the situation. P4 was measured. OVD was washed off AC. AC was formed with saline and hydration of main port and side ports was done. Subconjunctival dexamethasone and gentamicin was injected. P5, BP4, PR4 was measured. Speculum was removed. Eye was patched. If, the pupil dilation was inadequate intraoperatively, the surgeon decided either to re-inject intracameral mydriatic solution or to apply other methods of pupil dilation whenever required. On the first post-operative day, patients were examined for visual acuity using Snellens visual acuity chart. Corneal oedema was graded as per OCTET grading as transient corneal oedema (1+ mild), transient corneal oedema with descemet membrane folds of <10 (2+ moderate), and transient corneal oedema with descemet membrane folds of >10 (3+ severe).<sup>[7]</sup> AC inflammation was evaluated by using Standardized Uveitis Nomenclature and was graded from 0 to 4 as 0 (no cells seen), 0.5 (1–5 cells), +1 (6–15 cells), +2 (16–25 cells), +3 (26–50 cells), +4 (>50 cells). Endothelial cell count was analysed using specular microscopy. Statistical analysis was performed by the commercial software SPSS Inc., Chicago, IL, version 22.0 for windows. Continuous variables were explained with mean  $\pm$  SD and categorical variables as frequencies or percentages. Repeated measures ANOVA with Greenhouse-Geisser correction was used to compare continuous variables with a baseline data. P-value <0.005 was considered statistically significant. Data is presented in the form of tables, figures, graphs, diagrams wherever necessary.

**Results;** The sample of 60 patients recruited for study had 33 males (55%) and 27 females (45%). Mean age of the study sample is  $66 \pm 4$  yrs. (Table 1). An increase of  $0.7 \pm 0.283$  mm from baseline pupillary diameter of  $3.7 \pm 0.962$  mm was noted following peribulbar block and the peak value of  $7.35 \pm 1.205$  mm was attained following intracameral injection of mydriatic solution, which gradually reduced to  $6.03 \pm 1.327$  mm after cortical wash and  $5.7 \pm 1.212$  mm after IOL implantation to reach  $5.53 \pm 1.171$  mm by the end of the surgery. (Table 2) 89.4% cases achieved adequate mydriasis (>6mm). Remaining seven cases (11.6%) did not achieve adequate mydriasis and needed reinjection of the mydriatic solution. All surgeries were uneventful. Five cases where mydriasis was <6mm even after re-injection of mydriatic solution were managed without use of any other alternate methods of dilation.

**Table1: Demographic profile of subjects included in the study.**

Gender	Frequency(n)	Percentage (%)	Mean age(yrs)
Male	33	55	66.02 $\pm$ 4.50yrs
Female	27	45	
Total	60	100	

**Table2: Pupillary diameter measured during different stages of surgery.**

Pupillary diameter (P)	Mean $\pm$ SD (in mm)	P Value
PRE-OP	3.0 $\pm$ 0.689	-
P1 (after peribulbar block)	3.70 $\pm$ 0.962	<0.001
P2 (30secs after intracameral injection)	7.35 $\pm$ 1.205	<0.001
P3 (after cortical wash)	6.03 $\pm$ 1.327	<0.001
P4 (after IOL implantation)	5.70 $\pm$ 1.212	<0.001
P5 (before removing lid speculum)	5.53 $\pm$ 1.171	<0.001

Intracameral injection of mydriatic solution of lignocaine and epinephrine did not cause any significant spike in systolic and diastolic blood pressure, pulse rate throughout the surgery. However a significant rise of 10mmhg was noted in the systolic blood pressure following peribulbar block which was transient and seen to return to baseline values within few minutes. (Table 3) On postoperative day1, corneal oedema was absent in 30 subjects (50%), mild (1+) in 24 subjects (20%), moderate (2+) in 15 subjects (25%), severe (3+) in 3 subjects (5%). AC inflammation scores were grade0.5 in 25 subjects (42%), grade1 in 20 subjects (33%), grade2 in 9 subjects (15%), grade3 in 5 subjects (8%), grade4 in 1 subjects (2%).83% of the subjects had unaided visual acuity better than 6/12 and the remaining had visual acuity between 6/24 to 6/60 (Table 4).

**Table 3: BP and Heart rate measured at different stages of surgery.**

Systolic blood pressure	Mean ± Std. Deviation	P value
SBP1 (Before shifting to OT)	131.43±15.873	
SBP2 (After peribulbar block)	140.20±19.281	<0.001
SBP3 (30secs after intracameral injection)	133.40±17.595	0.343
SBP4 (Before shifting patient to recovery)	131.13±19.050	1.000
Diastolic blood pressure		
DBP1 (Before shifting to OT)	79.47±11.909	-
DBP2 (After peribulbar block)	80.03±14.363	1.000
DBP3 (30 secs after intracameral injection)	78.33±10.730	1.000
DBP4 (Before shifting patient to recovery)	79.30±11.259	1.000
Pulse Rate		
PR1 (Before shifting to OT)	77.27±10.499	-
PR2 (After peribulbar block)	77.43±13.474	1.000
PR3 (30secs after intracameral injection)	75.53±13.760	0.293
PR4 (Before shifting patient to recovery)	75.87±12.234	0.082

**Table 4- visual acuity outcome**

Visual acuity	Frequency (n)	Percentage (%)
6/9	30	50
6/12	20	33
6/18	7	12
6/24	2	3
6/60	1	2

**Table 5- Endothelial cell count**

Endothelial cell count (n=42)	
Pre-operative	Post-operative Day1
2422 ± 207 cells/mm <sup>3</sup>	2170 ± 226 cells/mm <sup>3</sup>

Mean preoperative endothelial cell count in 60 subjects was 2342.26±216.97cells/mm<sup>3</sup>. On postoperative day1, specular microscopy could be recorded in 42 subjects and remaining could not be recorded due to striate keratopathy. Mean preoperative endothelial cell count of only those 42 subjects (i.e 2422 ± 207 cells/mm<sup>3</sup>) was taken for comparison with the mean postoperative endothelial count. Mean Loss of endothelial cells on post-operative day1 in these 42 patients was 10.4% (Table5).

### Discussion

Topical mydriatics have the disadvantage of having Benzalkonium chloride as preservative which can cause punctate epithelial erosions. Repeated instillation of topical mydriatics may lead to conjunctival irritation, increased bacterial contamination and also systemic absorption leading to cardiovascular side-effects. So, in this study we have evaluated the efficacy of induction and maintenance of mydriasis by intracameral Lignocaine (1%) and Epinephrine (0.1%) in MSICS and their effects on systemic haemodynamics.



Lincoff et al (1985) have shown that lignocaine, blocks the parasympathetic tone to sphincter pupillae thus causing pupillary dilation.<sup>6</sup> Epinephrine, acts on the  $\alpha_1$  receptors of the dilator pupillae causing its contraction, as well as  $\beta$ -receptors of sphincter pupillae causing its relaxation, thus leading to pupillary dilation. K Ajay et al, have showed the effect of the intracameral solution of lignocaine 0.5% and epinephrine 0.001% prepared by dilution method, to produce sustained pupil dilation throughout the surgery for a safe MSICS.<sup>8</sup> The reason behind dilution of epinephrine is to reduce the concentration and toxic effect of sodium metabisulfite on corneal endothelium. But the degree of toxicity of sodium metabisulfite on corneal endothelium depends not only on its concentration, but also on the exposure time. Hull et al, have shown the toxic effects of sodium metabisulfite on corneal endothelium with exposure time >2min.<sup>9</sup> We have used epinephrine 1:1000 containing 0.1% sodium metabisulfite which is diluted with preservative free lignocaine to 1:2times and 0.2ml of this mixture is left in the AC for only 30secs and is then washed off, thereby allowing very minimal exposure of corneal endothelium to metabisulphite.

We noted an increase in pupillary diameter from baseline value of  $3\pm 0.6$ mm following peribulbar block. After the injection of intracameral mydriatic solution, we noted pupil dilation to  $7.3\pm 1.2$ mm. Similar dilation in MSICS with intracameral mydriatics is seen in study by K Ajay et al.<sup>[8]</sup> This dilation was sufficient to make an adequate sized capsulorrhexis and nucleus delivery in to the AC. With the delivery of nucleus and cortical wash we noted reduction in mydriasis to  $6.03 \pm 1.3$ mm. This might be due to the technique of nucleus prolapse and phacosandwich technique of nucleus delivery, which lead to manipulations of iris. Before closure we noted a pupil diameter of  $5.53 \pm 1.1$ mm. Our results were similar to the study by K Ajay et al where pupil diameter at closure was  $5.5\pm 1$ mm with both topical and intracameral mydriatics. Adequate Pupil dilation was maintained till the end of the surgery in 89.4% of the cases which was adequate for a safe MSICS. Remaining 11.6%cases needed reinjection of mydriatic solution. The pupillary fatigue caused due to repeated dilation of pupil with topical mydriatics on the previous day for preoperative evaluation might be one of the causes for poor dilation in few of our cases. Thirty seconds after intracameral mydriatic injection the SBP ( $133.40\pm 17.59$ mmhg) and DBP ( $78.33\pm 10.73$ mmhg) noted was not statistically different from baseline value ( $131.43\pm 15.873$ mmhg). SBP and DBP were maintained at the baseline thereafter till closure. Our results are comparable to study by El Hadad OH et al, Bhallil S et al, who also reported intraoperative and postoperative BP after intracameral injection of epinephrine remained constant in phacoemulsification.<sup>3,10</sup> However we noted a spike in SBP of 10mmhg after peribulbar block ( $140.20\pm 19.281$ mmhg) from baseline value. This rise in SBP was transient and returned back to the baseline value in few minutes. Similar results are seen in the study by Yu AY et al, wherein the rise in SBP following block is attributed to surgically induced neurogenic hypertension.<sup>[11]</sup> We noted that the pulse rate remained statistically close to the baseline value of  $77.27\pm 10.4$ bpm and did not vary significantly after intracameral mydriatic injection and remained the same throughout the surgery. Our results are comparable to study by N. Saraiya et al, who also reported no variation of pulse rate after intracameral epinephrine.<sup>12</sup>

On postoperative day1, we noted corneal oedema with striate keratopathy (Descemets folds >10) in 5% of the subjects. This is comparable with the results shown by Venkatesh R et al, in which striate keratopathy in MSICS was 6%.<sup>13</sup> The results of AC inflammation scores and visual acuity is comparable to results of study done by K Ajay et al, and other MSICS studies with topical mydriatics.<sup>[8]</sup> Endothelial cell loss(10%) seen in our study on 42 subjects on postoperative day1 is comparable to study by Thakur SK et al, who showed endothelial cell loss of 15.83% in MSICS with topical mydriatics.<sup>14</sup> Our results of corneal oedema and specular microscopy indicate that endothelial cell loss caused by the intracameral mydriatic solution used is comparable to standard MSICS with topical mydriatics. However long-term follow up on endothelial count is needed to substantiate the endothelial safety. The limitations of our study are, 1.Small sample size, 2.long term follow up may be required to analyse delayed endothelial changes.

In Conclusion, Intracameral mydriatics lignocaine 1% and epinephrine 0.1% are safe and effective alternatives to achieve adequate and sustained pupillary dilation for MSICS. They do not alter blood pressure and Heart rate. Additional methods of pupil dilation need to be kept standby in the small percentage (<10%) of patients who do not achieve adequate mydriasis.

#### Financial Disclosure -None

#### CoIntroduction



## References

1. Prausnitz MR, Noonan JS. Permeability of cornea , sclera and conjunctiva : a literature analysis for drug delivery to the eye. *J Pharm Sci.*1998 Dec;87(12):1479-88
2. Samantaray S, Thomas A (1975). Systemic effects of topical phenylephrine. *Indian J Ophthalmol* 1975;23:16-17
3. Bhallil S, Andalloussi IB, El Abdouni O, Mahjoubi I , Tahri H (2010). Is there a perioperative side effect of intracameral epinephrine in hypertensive patients undergoing phacoemulsification?. *Oman J Ophthalmol* 2010;3:161-162
4. Lundberg B, Behndig A (2003). Intracameral mydriatics in phacoemulsification cataract surgery. *J Cataract Refract Surg.* 2003; 29(12):2366–2371. doi:10.1016/s0886-3350(03)00522-4
5. Cakmak HB, Cagil N, Dal D, Simavli H, Arifoglu HB, Simsek S. Effects of intracameral use of adrenalin solution with preservative on corneal endothelium. *Cutan Ocul Toxicol.* 2010; 29(1): 41–49. doi:10.3109/15569520903433517
6. Lincoff H, Zweifach P, Brodie S, et al (1985). Intraocular injection of lidocaine. *Ophthalmology.* 1985;92:1587-1591. doi:10.1016/s0161-6420(85)33820-4
7. Long-term corneal endothelial cell loss after cataract surgery. Results of a randomised controlled trial. Oxford Cataract Treatment and Evaluation Team(OCTET). *Arch Ophthalmol.*1986;104(8):1170-1175.
8. Ajay K, Saranya S, Sundaresh DD, Hithashree HR, Hemalatha BC, Krishnaswamy M, et al (2018). Efficacy and safety of intraoperative intracameral mydriasis in manual small incision cataract surgery - A randomized controlled trial. *Indian J Ophthalmol.* 2017;65(7):584-588. doi:10.4103/ijo.IJO\_262\_17
9. Hull D.S., Chemotti MT, Edelhauser HF, Van Horn DL, Hyndiuk RA (1975). Effect of epinephrine on the corneal endothelium. *Am. J. Ophthalmol.* 1975; 79(2):245-250. doi:10.1016/0002-9394(75)90078-1
10. El Haddad OH, Hafez Ta, Helaly HA, El-Morsy NY (2016). Comparison between intracameral adrenaline injection in addition to topical mydriatics and topical mydriatics only in phacoemulsification surgery. *Egypt J Cataract Refract Surg.* 2016;22:15-20
11. Yu AY, Guo H, Wang QM, Huang JH (2016). Pupil Dilation with Intracameral Epinephrine Hydrochloride during Phacoemulsification and Intraocular Lens Implantation. *J Ophthalmol.* 2016;2016:4917659. doi:10.1155/2016/4917659
12. N. Saraiya, C. Bouchard, A. Khanna (2010). Effects of intracameral epinephrine on heart rate and blood pressure during cataract surgery. *Invest. Ophthalm. Vis. Sci.* 2010;51(13):5403
13. Venkatesh R, Das M, Prashanth S, Muralikrishnan R. Manual small incision cataract surgery in eyes with white cataracts. *Indian J Ophthalmol.* 2005;53(3):173-176. Doi:10.4103/0301-4738.16675
14. Thakur, S.K, Dan, A., Singh, M., Banerjee, A., Ghosh, A., & Bhaduri, G. (2011). Endothelial cell loss after small incision cataract surgery. *NEPJOPH*, 3(2), 177-180.

# Modified classification of Indirect Choroidal rupture (ICR) based on morphological pattern by Optical coherence Tomography and its relation to choroidal neovascularization

Dr Unnikrishnan Nair,<sup>1</sup> Dr Manoj Soman<sup>2</sup>

<sup>1,2</sup>Chaithanya Eye Institute and Reseach center, Thiruvananthapuram, Kerala

## Abstract

**Purpose:** To evaluate the morphological types of indirect choroidal rupture (ICR) using spectral domain optical coherence tomography (SD-OCT) and their relation to the risk of choroidal neovascularization. **Methods:** A prospective interventional study of 24 eyes of 24 patients who presented with a history of blunt ocular trauma causing choroidal rupture. All patients underwent detailed ophthalmic evaluation and SD-OCT examination. **Results:** Mean age of the patients was 34±7.6 years. Based on Morphology three types of choroidal ruptures were seen on SD-OCT. The first type (Type 1 ICR) is a forward protrusion of the retinal pigment epithelium-choriocapillaris (RPE-CC) layer with an acutely angled pyramidal or dome shape and is associated with a small loss of continuity of the RPE layer or the elevated RPE- CC projection, accompanied by a significant quantity of sub-retinal hemorrhage. The second type described (Type 2 ICR) is a larger area of disruption of the RPE-CC, photoreceptor inner segment-outer segment (ISOS) junction and external limiting membrane with a posteriorly directed concave contour depression at that area and downward sliding of overlying tissues into the defect. Type 3 ICR is the combination of type 1 and type 2. Ten eyes were observed to have type 1 ICR, 8 eyes had type 2 ICR at presentation and 6 eyes had type 3 ICR. Of these eyes, 5 developed choroidal neovascularization (20.8%) of which one eye belonged to type 1 ICR, two eyes belonged to type 2 ICR and two eyes in type 3 ICR. **Conclusion-** Three distinct tomographic patterns of choroidal ruptures have been identified on SD-OCT which may allow a classification of ruptures into three morphological types. There are differences in the clinical and morphometric appearances, type 2 and 3 carry increased risk of CNVM.

**Key words-** SD-OCT, Choroidal rupture, Blunt ocular trauma

## Introduction

Blunt ocular trauma can cause a spectrum of dramatic ocular pathologies ranging from mild to grave. Approximately 5-10% of patients with such injury develop a choroidal rupture.<sup>1</sup> Indirect choroidal ruptures (ICR) are a result of transmitted concussional force<sup>2</sup> through the wall of the globe and are discontinuities in the choroid, the Bruch's membrane, and the retinal pigment epithelium (RPE). Blunt trauma to the globe momentarily deforms it and while the tensile strength of the sclera and the elasticity of the retina aids resistance to injury, the Bruch's membrane is breached because it is fragile and cannot withstand such a force. Concomitantly, the small capillaries of the choriocapillaris are damaged, leading to subretinal or sub-RPE hemorrhage while the deep choroidal vessels are usually spared. Ruptures occurring secondary to punch injuries are usually situated in the peripapillary region while projectile injury commonly produced ruptures in the posterior pole.<sup>3</sup> Those involving the macula are predictably associated with a poor visual prognosis and are more predisposed to form choroidal neovascular membranes (CNVM).<sup>4</sup> This is an important cause for visual loss although there are also other reasons for a poor visual outcome.<sup>5</sup> While acute visual loss in eyes with ICR may be due to ruptures passing through the fovea or a rupture associated subretinal hemorrhage extending to lie under the fovea, delayed defective vision occurs because of scar formation or later onset of a CNVM. It is of note that multiple choroidal ruptures are not necessarily associated with a bad visual outcome.<sup>6</sup> Choroidal neovascularization (CNV) is a part of the normal healing process after choroidal trauma. Studies show that there can be a spontaneous involution of the CNV within weeks following injury,<sup>7</sup> but unfortunately in some eyes, the CNV is aggressive or gets reactivated, subsequently leading to visual loss in about 5% of ruptures.<sup>8</sup> Risk factors for development of CNV include ICR involving the macula, longer length of ruptures, ruptures closer to the center of the fovea and those occurring in older age group.<sup>4,9</sup> While the clinical and angiographic appearance of ICR have been well described,<sup>10</sup> the patho-anatomy of choroidal rupture using spectral domain optical coherence tomography (SD-OCT) hasn't yet been fully explored. SD-OCT has revolutionized the approach to and understanding of several retinal conditions. Visual

reconstruction of retinal pathology is possible due to the high resolution and volumetric scan modalities available in the latest generation OCT machines. The aim of our study was to analyze the different morphological appearances of ICR on SD-OCT imaging and to classify them based on presenting morphology. We also studied the association of clinical features causative injury, dimensions, locations and complications, like sub-retinal hemorrhage and CNV formation, with each type of ICR in these eyes.

## Material and Methods

This study was a prospective interventional study of 24 eyes of 24 patients attending the retina clinic in our tertiary care hospital, who had sustained blunt ocular trauma believed to be the cause of a choroidal rupture, between March 2016 and March 2019. The study was approved by the Institutional review board and ethics committee. Written informed consent was taken from all the patients included in the study. Patients who presented within a week of the trauma were included in the study, so that the ICR morphology could be studied in the acute stage. All patients went through a thorough clinical history and ophthalmological examination. The nature of injury and the approximate size of the object causing trauma, whether smaller or larger than the size of the anterior orbit, were noted. The visual acuity was assessed using Snellen's chart and converted to logMAR values for analysis. Anterior segment examination was done using slit lamp biomicroscopy and Goldmann applanation tonometry was performed on all eyes. Posterior segment evaluation included fundus examination with slit lamp biomicroscopy using a Volk 78D lens and indirect ophthalmoscopy using Volk 20D lens. Patients were excluded if there was significant media haze due to vitreous hemorrhage or corneal involvement, precluding morphometric measurements and SD-OCT imaging at presentation or at any time during follow-up. Any patient presenting later than a week, or requiring surgical management, or with less than 6 months follow-up was also not included in analysis. A choroidal rupture was classified as macular, foveal or peripheral according to the criteria described by Ament et al.<sup>4</sup> Other coexistent ocular injuries were also noted. SD-OCT was performed for the involved eyes using Cirrus<sup>®</sup> (Carl Zeiss Meditec, Germany). Cube and raster scans were done through the entire length of the ICR with image signal strength being in excess of 5/10. Each cube scan consisted of 512 vertical sections and 128 horizontal sections at 5 micron cuts. The morphological appearance of the choroidal rupture, changes in the outer retinal layers and choriocapillary complex, and presence of sub retinal hemorrhage were noted. Care was taken to keep the lateral borders of the choroidal ruptures within the scan area through their entire length. All patients had a fundus photograph taken to document the choroidal rupture (VISUPAC FF450 IR Plus, CarlZeiss, Germany). The length of the rupture and the shortest distance between the rupture and the foveal centre was measured using the caliper tool of the SD-OCT by a single observer (UN). In case of multiple ruptures, the length of the longest rupture was recorded. In curvilinear ruptures, the free-hand tool was used to measure the linear length. If the rupture passed through the fovea then the proximity from fovea measurement was taken as zero. FFA was done at the point of clinical suspicion of CNVM development. Six patients with follow up less than 12 months were excluded from the analysis of CNVM formation. Statistical analysis was done using SPSS version 16.0 software package (SPSS Chicago, IL). The unpaired 't' test was used to compare the means of values between the two groups of ICR. Fisher's test was used to determine the statistical significance of the size of the projectiles and the number of ruptures in these eyes between the 3 groups.

## Results

Of the 24 patients included in our study, there were 18 males and 6 female patients. The mean age was  $34 \pm 7.6$  years (range 12-56 years). Best corrected visual acuity ranged from counting fingers to Snellen acuity 6/6 (logMAR vision equivalent 0). Mean logMAR vision was  $0.720 (\pm SD 0.51)$ . The average duration of follow up for these patients was  $18.86 \pm 6.4$  months. Demographic details and anterior segment examination features are described in table 1. The choroidal ruptures were clinically apparent as irregular curvilinear breaks in the choroid with associated subretinal hemorrhage (Fig 1 A,C,E). Fundus evaluation revealed choroidal rupture involving the fovea in 11 of the 24 eyes. All eyes had ruptures posterior to the equator. Multiple sites of choroidal rupture were seen in 7 eyes. One patient who developed a peripheral traumatic cataract was included in analysis as the view and imaging of the retina was not hampered.

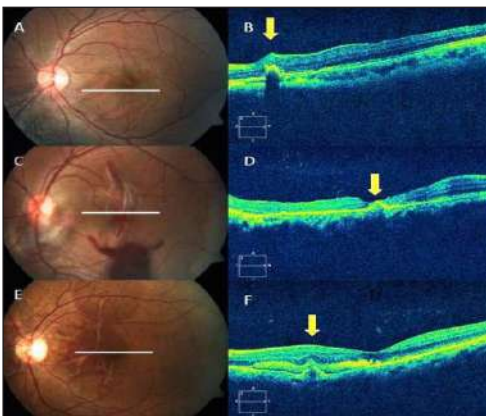
### SD-OCT Features:

Three patterns of choroidal rupture were identified on SD-OCT. The first pattern (Type 1) was a forward protrusion of Retinal pigment epithelium-choriocapillaris (RPE-CC) layer with an acute pyramidal or dome shape and was associated with a small loss of continuity of the RPE layer or a break in the wall of the elevated RPE-CC herniation along with a variable quantity of sub-retinal hemorrhage (Fig 1B,D,F). The reflectivity under the dome seemed to be variable.

The second type (Type 2) of ICR comprises a posteriorly concave area of disruption of the RPE-CC (Figure 2A-D). This was associated with loss of photoreceptor inner segment-outer segment (ISOS) and the external limiting membrane (ELM) reflectivity. There was apparent sliding down of overlying retinal layers into the defect. The third type (type 3) of ICR was combination of type 1 and type 2 (Figure 3).

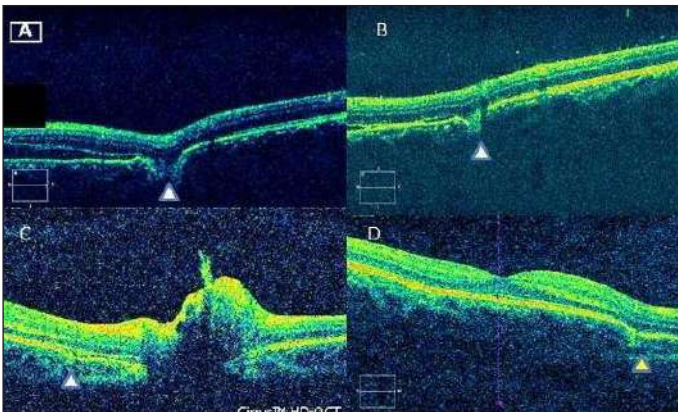
**Table 1. Patient demography and anterior segment features of 18 eyes with indirect choroidal rupture.**

	Number	Percentage
Males	18	75.0
Females	6	25.0
Mean Age	34±7.6 years	
Number of eyes with large projectile injury	8	33.33
Number of eyes with small projectile injury	16	66.66
<b>Clinical Anterior segment features</b>		
Bulbar conjunctival congestion	18	75.0
Subconjunctival hemorrhage	3	12.5
Corneal abrasion	3	12.5
Anterior uveitis	12	50.0
Hyphema	2	8.33
Traumatic cataract	1	4.16

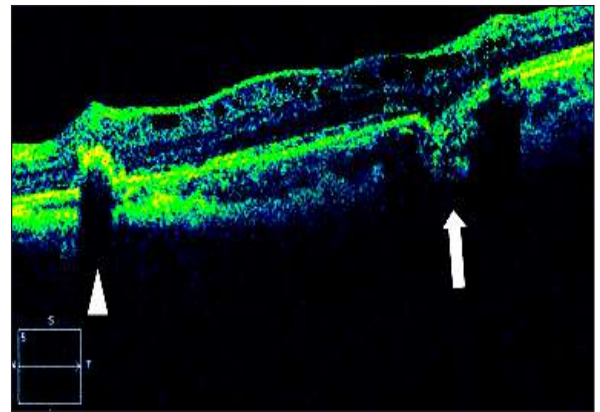


**Figure 1:** Type 1 ICR. A: Extrafoveal ICR nasal to the fovea. B: Dome shape elevation with loss of continuity at the base of dome; C: Multiple ICRs at the macula involving fovea. D: Subfoveal Rupture with apparently intact RPE-CC. E: Multiple ruptures just sparing the fovea with subretinal hemorrhage. F: Extrafoveal pyramidal shape elevation with break in the tip and subfoveal hemorrhage

**Figure 2:** Type 2 ICR . A: Loss of continuity of RPE-CC, IS-OS layer and ELM with downward sliding of inner retinal layers; B: Focal loss of continuity with no change in contour of overlying retinal layers ; C: Peripapillary choroidal rupture with subretinal bleed ; D: 2 months after healing and persistence of depression and change in retinal contour (yellow arrowhead)



**Figure 3 -Type 3 ICR ;**Combination of Type 1 and Type 2: Arrow Indicates type 1 and arrow head indicates type 2 rupture in the same patient



In our study, 10 eyes belonged to the type 1 pattern of choroidal rupture, 8 eyes were of type 2 and 6 eyes were type 3 and the eyes were categorized into each type based on their SD-OCT feature at presentation. When perused through the length of the rupture, each ICR maintained its integral feature throughout and there was no change over the follow-up period from one type to the other. The morphometric and SD-OCT features of each type are summarized in table 2. Based on the morphology, the three types of ICR were analyzed for associations with mode of injury, number and location of ruptures and SRH involvement of fovea. Table 3 illustrates the frequency of various characteristics in these three categories.

**Table 2:** Morphometric and SD-OCT characteristics of the 24 eyes according to SD-OCT classification of the indirect choroidal ruptures.

Characteristic	Type 1 (n=10)	Type 2 (n=8)	Type 3 (n=6)	P Value
Mean length of ICR* (mm)	6.86±2.5	9.18±5.1	9.08±4.7	0.22 95%CI-6.2 to 1.5
Mean proximity to fovea* (mm)	5.11±3.27	2.59±1.67	2.89±1.86	0.06 95% CI -0.18 to 5.2

\*- measured using fundus photograph caliper in VISUPAC FF450 Plus, Carl Zeiss, Germany.

Five eyes (20.08%) developed CNVM secondary to choroidal rupture, 2 of these patients had type 2 pattern and 2 eyes had type 3 choroidal rupture on SD-OCT. Out of the 5 eyes with CNVM, three patients had subfoveal and two had juxtafoveal location of CNV. All the five patients had type 2 CNV and 4 eyes were treated with intravitreal Bevacizumab (IVB) and one patient was treated with intravitreal Ranibizumab. Length of the choroidal ruptures in all the 5 patients was more than 4mm and within 1-2 DD from center of the fovea. Associated features, Five eyes had optic disc pallor along with choroidal rupture could be secondary to blunt trauma. Four eyes had vitreous hemorrhage, one had a vitreous base avulsion and one patient had a peripheral retinal tear.

**Table 3:** Clinical characteristics of the 24 eyes with ICR.

	Type1 (n=10)	Type2 (n=8)	Type 3 (n=6)	P value
Number of eyes with large projectile material injury	5(50)	1(12.5)	1(16.6%)	0.15
Number of eyes with small projectile material injury	5(50)	7(87.5)	5(83.3%)	
Single ICR	7 (70)	6 (75)	4 (66.6%)	1.0
Multiple ICRs	3(30)	2(25)	2 (33.33%)	
ICR located within arcades	4(40)	8(100)	5(83.33%)	0.012
ICR located outside arcades	6 (60)	0	1(16.66%)	
ICR around optic disc	2(20)	1 (12.5)	1(16.66%)	1.0
Foveal involvement of Sub Retinal Hemorrhage	5(50)	8(100)	6(100%)	0.012
Foveal involvement of rupture	4(40)	3 (37.5)	4(66.66%)	1.0

**Table 4-** CNVM with treatment details

Parameter	Patient 1	Patient 2	Patient 3	Patient 4	Patient 5
Location of CNVM	Subfoveal	Subfoveal	Juxtafoveal	subfoveal	Juxtafoveal
Length of ICR (mm)	4.67	5.11	4.98	5.68	5.23
Distance of ICR from foveal centre (mm)	0	0.47	0.97	0.67	0.58
Choroidal rupture type on SD- OCT	2	1	2	3	3
Treatment	IVB	IVB	IVB	IVR	IVB

## Discussion

Our study revealed that the morphological appearances of ICR on SD-OCT were classifiable into three main types. We noted a predominance of male patients which was consistent with previous work.<sup>3,10</sup> In these studies the main mode of injury was a projectile object not bigger than the diameter of the orbit. A variety of culpable scenarios ranging from injuries in road traffic accidents to falling fruit<sup>[11]</sup> have been noted, similar to that in our patients. Of the 7 patients who reported injury with a larger projectile, 5 (71.4 %) had type 1 ICR while 7 of the 17 (41.17%) patients with smaller projectile injury had type 2 ICR and 5 of the 17(29.41%) had type 3 ICR. Conversely 87.5% and 83.3% of the patients had type 2 and type 3 ICRs reported of injury with smaller projectiles. However the influence of the velocity of the projectile and the force of the trauma were not analyzed as these parameters were expected to be highly subjective.

Previous studies have described two distinct clinical patterns of ruptures which give rise to CNVM.<sup>3,11,12,13</sup> These clinical patterns correspond to partial thickness ruptures situated temporal to the optic nerve head and curving through the fovea or those situated superiorly or inferiorly around the optic disc, nearly impinging onto the fovea.<sup>3</sup> This curvilinear configuration is probably a result of maximal stress at these areas.<sup>315</sup> The authors also stress that the location of the rupture is important to note since the development of a CNVM is likely to be perifoveal,<sup>3</sup> as the RPE is unable to inhibit neovascularization effectively around the fovea.<sup>14</sup>

Our data shows that the type 2 and type 3 ICRs were more likely to be longer in length although this did not reach statistical significance when compared to the lengths of the type 1 ICRs. But the proximity of type 2 and type 3 ruptures to the fovea and the likelihood of being located within the vascular arcades were significantly higher than the type 1. As is expected, the involvement of the fovea by subretinal blood was also significantly higher in type 2 and type 3 ruptures. However, we could not conclusively prove that foveal ruptures were commoner in type 2 and type 3 ICRs. This might have been due to the inadequate numbers of eyes in each group. Yet we may speculate that type 2 and type 3 ruptures are more likely to involve the fovea in view of being preferentially located within the arcades and can logically be more often associated with poorer vision and CNVM formation as discussed previously.<sup>3,14</sup> In our study, we noted that 17 out of 24 patients had ICRs within the arcades. Of these, the 5 patients who developed a CNVM had ruptures situated within 1mm from the foveal centre, in accordance with the previously stated reference. Among the 5 patients who did develop a CNVM only one patient had a type 1 ICR and there was no significant difference between the groups. The statistical analysis may be hampered by the small numbers of CNVM development. Still, it would not be wrong to ponder if type 2 and type 3 ICRs were more inclined to develop CNV because the amount of tissue disruption that occurs in type 2 and type 3 ICR is much more extensive than in type 1.

We illustrate SD-OCT features pertinent to the morphological appearance of these ruptures which none of the previous investigators have described. The peak and trough configurations are likely to be a result of the varying stress release patterns during blunt ocular trauma. Based on our observation that type 1 ICR is more likely to occur in ocular trauma by large projectiles, while the type 2 and type 3 is more associated with projectiles smaller than the anterior diameter of the orbit, we can assume that there is perhaps an association between the nature and amount of force to ocular tissues and the type of ICR, although in our analysis this did not reach statistical significance. The exact reason for this peculiar configuration of the breaks is largely speculative, but we can hypothesize that perhaps some of the velocity of the larger projectiles was deflected by the anterior orbital rim causing less of a compressive force, and more of a shock wave effect, and therefore less direct trauma to the ocular structures. This translates into a generalized increase in intra-orbital pressure with a restricted re-expansion of the globe due to the tamponading effect of the large surface projectile at the orbital rim. The resultant implosion type effect leads to a peaked rupture configuration directed internally. On the other hand, the large concave depressions seen in type 2 and 3 ruptures may have resulted from the more direct compressive effect and unhindered re-expansion of the globe following compressive trauma with projectiles having a smaller surface with no capacity to restrict such tissue deformation, thereby causing more extensive tissue damage and splitting of ocular coats.

Numerically the occurrence of CNVM was more likely in type 2 and type 3 ruptures it did not reach statistical significance due to the small number of ICR cases and CNVM development. This is possibly because the greater area of RPE and Bruch's damage that occurs in type 2 and type 3 ICRs is more conducive to the formation of CNV. It has already been established that CNVM is associated with a poor visual outcome,<sup>5</sup> with the prognosis further deteriorating if there is foveal involvement. The practical application of this SD-OCT classification may therefore be of a prognostic value. We would recommend that eyes having a type 2 and type 3 ICR need close monitoring with serial SD-OCT for early detection of CNV. Although deemed benign,<sup>3</sup> these neovascular membranes can pose a risk of hemorrhage and edema, which was the cause of acute defective vision in 3 out of 5 of our patients who developed a CNVM sub-foveally. Our study of 24 eyes allowed us to closely scrutinize the morphology of the ICR non-invasively over time. However, our small sample size did not permit us to comment on the statistical significance of our findings. A prospective study with a larger number of eyes and longer follow up may further substantiate our positive findings. Longer follow-up of the patients will determine if the type of ICR based on our discussion had a bearing on long term visual outcome. All patients with ICR should undergo serial SD-OCT examination for detection of type of ICR to help prognosticate vision in eyes with blunt ocular trauma.

**Financial support and sponsorship-None**

**Conflicts of Interest- None**

## References

1. Bellows JG. Observations on 300 cases of ocular war injuries. *Am J Ophthalmol* 1947; 30: 309-23.
2. Aguilar JP, Green RW. Choroidal rupture. A histopathological study of 47 cases. *Retina* 1984; 4: 269-75.
3. Wood C M, Richardson J. Indirect choroidal ruptures: aetiological factors, patterns of ocular damage, and final visual outcome. *Br J Ophthalmol* 1990;74:208-11.
4. Ament CS, Zacks DN, Lane AM, Krzystolik M, D'Amico DJ, Mukai S, et al. Predictors of visual outcome and choroidal neovascular membrane formation after traumatic choroidal rupture. *Arch Ophthalmol*. 2006 Jul;124(7):957-66.
5. Archer DB, Canavan YM. Contusional eye injuries: retinal and choroidal lesions. *Aust J Ophthalmol* 1983; 11: 251-64.
6. Raman SV, Desai UR, Anderson S, Samuel MA. Visual prognosis in patients with traumatic choroidal rupture. *Can J Ophthalmol*. 2004 Apr;39(3):260-6.
7. Aguilar JP, Green RW. Choroidal rupture: a histopathological study of 47 cases. *Retina* 1984; 4: 269-75.
8. Dean Hart JC, Raistrick ER. Indirect choroidal tears and late onset serosanguinous maculopathies. *Graefes Arch Clin Exp Ophthalmol* 1982; 218: 206-10.
9. Secrétan M, Sickenberg M, Zografos L, Piguet B. Morphometric characteristics of traumatic choroidal ruptures associated with neovascularization. *Retina*. 1998;18(1):62-6.
10. Hart JCD, Natsikos VE, Raistrick ER, Doran RML. Indirect choroidal tears at the posterior pole: a fluorescein angiographic and perimetric study. *Br J Ophthalmol* 1980; 64: 59-67.
11. Smith RE, Kelley JS, Harbin TS. Late macular complications of choroidal ruptures. *Am J Ophthalmol* 1974; 77: 650-8.
12. Hilton GF. Late serosanguinous detachment of the macula after choroidal rupture. *Am J Ophthalmol* 1975; 79: 997-1000.
13. Pearlstone AD. Delayed loss of central vision following multiple posterior segment trauma. *Ann Ophthalmol* 1980;12: 409-11.
14. Bressler NM, Bressler SB, Gragoudas ES. Clinical characteristics of choroidal neovascular membranes. *Arch Ophthalmol* 1987; 105: 209-13.
15. Schepens CL. In: Freeman HM, ed. *Ocular trauma*. New York: Appleton Century Crofts, 1979; chapter 29: 273-84.



# Anterior capsule sparing parsplana lensectomy in cataract with severely compromised corneal endothelium

Dr Sunil Ganekal<sup>1</sup>, Dr Nirmal Prasad<sup>2</sup>

<sup>1,2</sup>Department of Ophthalmology, Davangere Netralaya, Davangere

**Purpose:** To evaluate the results of parsplana lensectomy in the management of cataract with severely compromised or abnormal corneal endothelium. **Methods:** Retrospective interventional case study comprised 22 patients (9 women, 13 men; 22 eyes) with severely abnormal corneal endothelium but still transparent cornea. Of which 14 had history of penetrating keratoplasty, 6 had history of trabeculectomy and 2 were diagnosed as Fuch's endothelial dystrophy. Postoperative best corrected visual acuity (BCVA), mean density of corneal endothelial cells, postoperative complications were analyzed. **Results:** Mean follow-up was 17.2 months (range 6 to 31 months). Postoperative BCVA was 6/60 or below in 2 patients, 6/60-6/18 in 7 patients and 6/18 - 6/12 in 7 patients and 6/12 or better in 6 patients. BCVA improved in all patients after surgery, but in one patient with Fuch's endothelial dystrophy BCVA turned worse again about five months after surgery and eventually bullous keratopathy occurred. The mean density of corneal endothelial cells was  $1018 \pm 84 / \text{mm}^2$  (range  $844 / \text{mm}^2$  to  $1176 / \text{mm}^2$ ) before operation and  $981 \pm 93 / \text{mm}^2$  (range 853 to  $1211 / \text{mm}^2$ ) after operation. No significant difference in the density of corneal endothelial cells was found among the patients before and after operation ( $P=0.43$ ). **Conclusions:** Pars plana lensectomy is able to decrease surgically-induced corneal endothelial damage and is safe in the management of cataract with severely compromised corneal endothelium.

**Keywords-** Parsplana lensectomy, cataract, compromised cornea

## Introduction

Corneal endothelium plays a crucial role in the maintenance of corneal transparency. Abnormality of corneal endothelium in quantity or quality might lead to bullous keratopathy, or decompensation of corneal endothelium. It is well known that traditional cataract surgery, either phacoemulsification or extracapsular extraction, causes damage to the corneal endothelium due to the manipulations in the anterior chamber<sup>1-4</sup> and it was believed by many surgeons that severely abnormal corneal endothelium was a relative contraindication to cataract surgery.

Pars plana lensectomy (PPL) is another technique of cataract surgery which extracts the cataractous lens

from the vitreous cavity. This technique is able to avoid the manipulations in the anterior chamber, thus may decrease surgically-induced damage to the corneal endothelium. PPL is often performed to extract dislocated lens,<sup>5</sup> or as a procedure during combined cataract and vitreo-retinal surgery,<sup>6</sup> or on pediatric cataract patients.<sup>7</sup> Encouraged by the good results, we introduced PPL to manage cataract with severely abnormal corneal endothelium from October 2018. This study comprised 22 patients with severely abnormal corneal endothelium but still transparent cornea, who underwent PPL as the technique of cataract extraction.

## Methods

A retrospective analysis of 22 consecutive patients

who had cataract with severely compromised corneal endothelium but still transparent cornea and received PPL as the technique of cataract extraction was conducted. Of the 22 cases, 14 had history of penetrating keratoplasty, 6 had history of trabeculectomy and 2 were diagnosed as Fuch's endothelial dystrophy before surgery. Preoperative examination included best corrected visual acuity (BCVA), anterior segment evaluation by slitlamp biomicroscopy, posterior segment evaluation by slitlamp biomicroscopy using a Super Vitreo-fundus lens when fundus could be viewed, or by B-scan ultrasonography when media opacity blocked viewing of fundus. Preoperative cell count of their corneal endothelium was between 844/ mm<sup>2</sup> to 1176/ mm<sup>2</sup>, with certain morphological abnormality. To prevent postoperative retinal detachment, the peripheral fundus was paid special attention to and laser photocoagulation was conducted if there were any retinal breaks or lattice degeneration. The density and morphology of corneal endothelial cells were evaluated by Topcon SP-3000 specular biomicroscope. All the patients received pars plana vitrectomy (PPV) and PPL, combined with phacoemulsification in 6 eyes because of hard nucleus, retinal photocoagulation in 7 eyes and C<sub>3</sub>F<sub>8</sub> tamponade in 8 eyes to prevent retinal complications, primary intraocular lens (IOL) implantation in 1 eye and secondary IOL implantation in 4 eyes.

### Surgical Technique

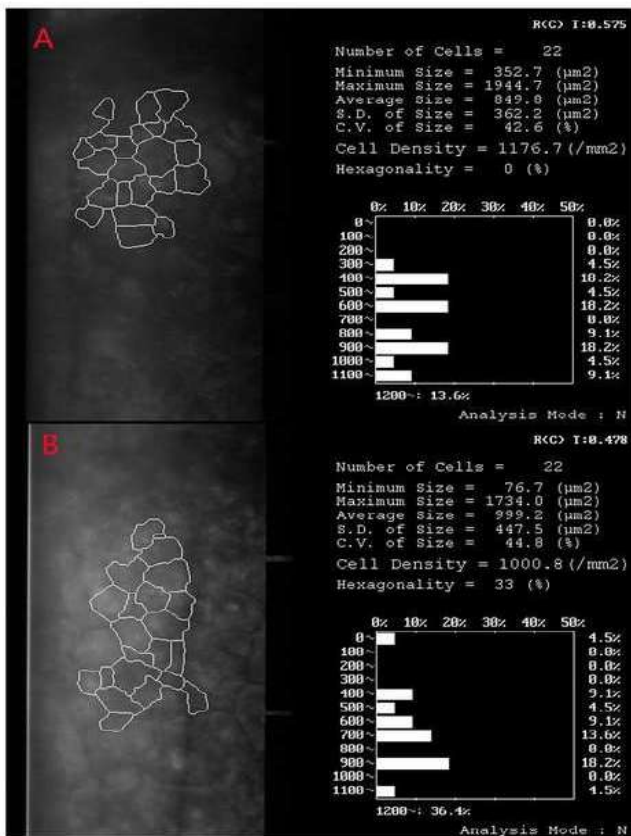
The procedure of PPL was performed with PPV with retrobulbar or peribulbar anesthesia and maximal mydriasis. Three small conjunctival flaps and accordingly three 20G scleral ports were made 3.5 mm behind the limbus at the position of 2 and 10 o'clock and inferotemporally. The inferotemporal port was connected with irrigation, the 2 o'clock port was used for illumination, and the 10 o'clock port for vitrectomy, lensectomy, photocoagulation, etc. Anterior vitrectomy was performed to remove the nearby vitreous. With the vitreous cutter, a 5 mm×5mm opening of posterior capsule was made. If the nucleus was soft, a deep groove of nucleus was made from behind. The nucleus was then pushed down into the vitreous cavity, usually turned into two halves at this time. The remaining cortex behind the anterior capsule was aspirated and the epithelial cells on the posterior surface of the capsule were removed with the cutter by means of low-vacuum polishing. A plano-concave lens was placed on the cornea for better viewing of the posterior vitreous cavity. The nucleus was then removed half by half using the vitreous cutter. If the nucleus was hard, a phacoemulsifier was used to remove the hard nucleus in the vitreous cavity by means of phacoemulsification. A thorough fundus examination was conducted, with particular attention paid to the peripheral retina. Retinal photocoagulation, C<sub>3</sub>F<sub>8</sub> tamponade was performed whenever there might be any risks for retinal detachment. Finally, the three scleral ports were closed by one stitch respectively using 6-0 absorbable suture. IOL implantation, either primary or

secondary, was performed using a 3.0 mm corneo-scleral tunnel incision. Viscoelastic agent was injected into the anterior chamber and between the iris and the capsule. IOL was injected in with a projector and was sulcus fixed. Viscoelastic agents were then carefully washed out by a cannula tip to avoid damaging the corneal endothelium. Main Outcome Measures-The follow-up examination also included BCVA, slitlamp biomicroscopy, slitlamp biomicroscopy with a Super Vitreo-fundus lens, and corneal endothelial cells evaluation by Topcon SP-3000 specular biomicroscope. Postoperative complications were also recorded.

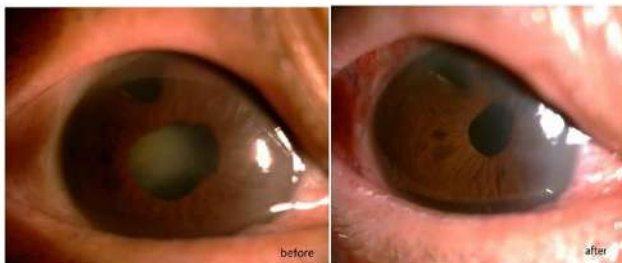**Statistical Analysis** -Statistical analyses were made using paired t-test by SPSS 17.0 software (SPSS Inc., Chicago, IL, USA). P<0.05 was considered statistically significant. Unless otherwise indicated, the results are expressed as the mean±SD.

**Results**-Between October 2018 and September 2020, 22 consecutive patients of cataract with severely abnormal/compromised corneal endothelium but still transparent cornea received PPL as the technique of cataract extraction. Twenty two eyes of 22 patients were enrolled in the study. The mean age of the 9 women and 13 men was 50.8 years±12.5 (SD) (range 21 to 72 years). Mean follow-up was 17.2±6.4 months (ranged 6 to 31 months). Preoperatively, BCVA was LP in 3 patients, FC in 4 patients, all below 6/60. Postoperative BCVA was 6/60 or below in 2 patients, 6/60-6/18 in 7 patients, 6/18 - 6/12 in 7 patients and 6/12 or better in 6 patients. BCVA improved in all patients after surgery, but in one patient with Fuch's endothelial dystrophy BCVA turned worse again about five months after surgery and eventually bullous keratopathy occurred. She was then transferred to cornea specialist and received penetrating keratoplasty. The mean density of corneal endothelial cells was 1018± 84/ mm<sup>2</sup>(range 844/ mm<sup>2</sup> to 1176/ mm<sup>2</sup>) before operation and 981±93/ mm<sup>2</sup> (range 853 to 1211/ mm<sup>2</sup>) after operation (Fig 1). No significant difference in the density of corneal endothelial cells was found among the patients before and after operation (P=0.43). Postoperative complications are shown in Table 1. Anterior capsule opacification developed in 10 patients, of which 8 had Nd:YAG laser capsulotomy and 2 had surgical capsulotomy at the time of secondary IOL implantation. BCVA improved and cornea remained transparent after capsulotomy in all patients. Bullous keratopathy occurred in one female patient with Fuch's endothelial dystrophy. Her BCVA remained 6/6 for approximately five months after PPL and then turned worse because of corneal edema. She therefore received penetrating keratoplasty and regained BCVA of 6/12. No patient had obvious uveitis on slitlamp examination, and none had retinal detachment (Fig 2).

**Figure 1.** Density of corneal endothelial cells before (A) and 5 days after surgery (B) in a patient who had the history of trabeculectomy and received PPL as the technique of cataract extraction



**Figure 2.** Slitlamp examination before(A) and 5 days after surgery (B) in the same patient who had the history of trabeculectomy and received PPL as the technique of cataract extraction.



**Table 1.** Postoperative complications

Complications	Number of cases
Capsule opacification	10
Bullous keratopathy	1
Uveitis	0
Retinal detachment	0

**Discussion**

Corneal endothelium is a hexagonal non-replicating monolayer of neural crest-derived tissue that regulates the hydration state of corneal stroma. It's a tissue that contains large quantities of membrane-bound Na<sup>+</sup>, K<sup>+</sup>-ATPase with specialized intercellular junctions that establish a pump-leak process in the maintenance of corneal deturgescence, and thus plays a crucial role in keeping the cornea transparent. Certain density and proper morphology of endothelial cells are important to

maintain this function. This delicate tissue is, however, subject to alteration from age, trauma, systemic or ocular diseases, surgery and some dystrophic conditions. Because of the non-replicating propriety, repair of the damaged areas takes place via the process of cell migration from adjacent undamaged areas. Thus a permanent reduction in cell density occurs, and individual cell size is increased. When the cell density drops beneath a threshold, the endothelium would no longer be able to work properly, and permanent cornea edema or bullous keratopathy occurs. We usually take corneal endothelial cell density of 1200 cells/mm as the threshold. Beneath the threshold, traditional cataract surgery should be carefully considered. The fast development of PPV has promoted PPL, which extracts the cataractous lens from the vitreous cavity, as a technique of cataract surgery. This technique is able to avoid the manipulations in the anterior chamber, and may decrease surgically-induced damage to the corneal endothelium. Although it is not a routine cataract surgery at present because of some severe complications such as retinal detachment and macular interference, PPL is often performed to extract dislocated lens,<sup>5</sup> or as a procedure during combined cataract and vitreo-retinal surgery,<sup>6</sup> or on pediatric cataract patients.<sup>7</sup> It was based on two points that we introduced PPL into the management of cataract with severely abnormal corneal endothelium. Firstly, although few studies had reported the influence of PPL on corneal endothelium in the literature, theoretically however, this influence would be much less than that of phacoemulsification or extracapsular cataract surgery. Secondly, modern PPV had decreased the complications of PPL into a receivable level. Excellent visualization, high-speed cutting and prophylactic photocoagulation had greatly reduced the retinal and macular complications. Our present study showed this technique is promising. Of the 22 cataract patients who had received PPL because of severely abnormal corneal endothelium, only one had bullous keratopathy. Because the complication occurred five months after surgery, we would rather think that this represent the natural course of gradual deterioration of Fuch's endothelial dystrophy. This study, however, was based on a small sample. More patients should be observed to further determine the influence of PPL on the corneal endothelium. The prominent complication of PPV in our study was anterior capsule opacification, with a prevalence rate of 47.6%. Compared with the posterior capsule, the anterior capsule possesses a monolayer of epithelial cells on its inner surface. This might account for the high prevalence of anterior capsule opacification. Capsule opacification can be managed by one of two methods: prophylactic capsulotomy intraoperatively or Nd:YAG laser capsulotomy postopeatively. To further reduce anterior chamber interference, the latter was selected in our study. No patient had developed bullous keratopathy after Nd:YAG laser capsulotomy.

**Financial support and sponsorship-None**

**Conflicts of Interest- None**

## References

1. Richard J, Hoffart L, Chavane F, Ridings B, Conrath J. Corneal endothelial cell loss after cataract extraction by using ultrasound phacoemulsification versus a fluid-based system. *Cornea* 2008; 27(1): 17-21.
2. Baradaran-Rafii A, Rahmati-Kamel M, Eslani M, Kiavash V, Karimian F. Effect of hydrodynamic parameters on corneal endothelial cell loss after phacoemulsification. *J Cataract Refract Surg* 2009; 35(4): 732-737.
3. Wilczynski M, Supady E, Loba P, Synder A, Palenga-Pydyn D, Omulecki W. Comparison of early corneal endothelial cell loss after coaxial phacoemulsification through 1.8 mm microincision and bimanual phacoemulsification through 1.7 mm microincision. *J Cataract Refract Surg* 2009; 35(9): 1570-1574.
4. Matheu A, Castilla M, Duch F, Martí M, Lillo J, Gil M. Manual nucleofragmentation and endothelial cell loss. *J Cataract Refract Surg* 1997; 23(7): 995-999.
5. Oh J, Smiddy WE. Pars plana lensectomy combined with pars plana vitrectomy for dislocated cataract. *J Cataract Refract Surg* 2010; 36(7): 1189-1194.
6. Romero P, Salvat M, Almena M, Baget M, Méndez I. Combined surgery for lens extraction, vitrectomy, and implantation in the diabetic patient using phacoemulsification versus phacofragmentation. *J Fr Ophtalmol* 2006; 29(5):533-541.16
7. Onol M, Ozdek S, Aktas Z, Hasanreisoglu B. Long-term results of pars plana lensectomy with double-capsule-supported intraocular lens implantation in children. *Can J Ophthalmol* 2008; 43(6): 673-677.

# Refractive and Keratometric outcomes of supervised novicesurgeon-performed limbal relaxing incisions (LRI'S)

Dr Satyamurthy KV<sup>1</sup>, Dr Mahantesh P shetty<sup>2</sup>

<sup>1,2</sup>Department of Ophthalmology, MM joshi Eye Institute, Hubli/Dharwad

## Abstract

**Purpose-** To study the outcome following LRI during phacoemulsification **Methods-** Prospective interventional study OF 200 eyes of 200 patients. All patients with pre-existing astigmatism of  $\geq 1$  D undergoing an elective phacoemulsification were included. The preoperative evaluation consisted of detailed clinical history, ophthalmic examination, uncorrected visual acuity (UCVA), best-corrected visual acuity (BCVA), cycloplegic refraction, measurement of intraocular pressure, manual keratometry (Bausch & Lomb, USA), and Automated keratometer. Corneal topography (Orbscan) was performed preoperatively to screen for keratoconus. In addition, tear film evaluation was done using the Schirmer's test and tear break up time. Ultrasound pachymetry was performed in cases with suspected peripheral corneal thinning. Limbal relaxing incisions were made at the onset of surgery using the the Louis D. "Skip" Nichamin nomogram. **Results-** Mean age of  $58.075 \pm 11.581$  years (range: 30-89 years). Pre operatively all the patients had BCVA  $\leq 6/9$ . Preoperatively 98.5% patients had BCVA of  $\leq 20/60$  and 54% had BCVA of  $\leq 20/200$ . Of the 200 patients, 154 (77%) had against the rule astigmatism and 46 (23%) had with the rule astigmatism. The mean preoperative astigmatism was  $1.58545D \pm 0.55D$ . All the patients completed 6 months follow up postoperatively. The mean postoperative astigmatism was  $0.509D \pm 0.29$  D at 1 week and  $0.479D \pm 0.26$  D at the end of 6 weeks after surgery. The mean astigmatism was further reduced to  $0.448 \pm 0.25D$  6 months postoperatively. The change in the amount of astigmatism was statistically significant at all time points when compared to the preoperative values ( $p < 0.001$ ). However, the reduction in astigmatism was not significant between these follow-up periods ( $p = 0.09$ ). Intraoperative extensions of the LRI incisions towards the sclera ( $n = 1, 0.5\%$ ) and cornea ( $n = 3, 1.5\%$ ) occurred in 4 (2%) cases. **Conclusion-** LRI is an easy, safe, and efficient method for the concurrent management of astigmatism at the time of cataract surgery

## Introduction

When assessing recent changes in modern cataract and intraocular implant (IOL) surgery, arguably, the single most pressing challenge facing today's phacoemulsification surgeon is the need to achieve predictable and accurate refractive outcomes. Surgeons and patients alike have come to largely measure the success of their surgery by the refractive outcome, and one of the leading causes for litigation in this field is the "refractive surprise."<sup>1</sup> Recent progress in cataract surgery has heightened the patient expectations and having a good post operative uncorrected visual acuity has become a standard.<sup>2</sup> Improved refractive results have come about by way of improvements in both surgical technique as well as advances in technology.

Spherical results have become more predictable because of increased attention to biometry technique as well as breakthrough technology such as partial coherence interferometry.<sup>3</sup> As the technology has evolved to smaller, suture less wounds, the attention has shifted to minimize the amount of surgically induced as well as pre-existing astigmatism. Estimates of the incidence of significant naturally occurring astigmatism vary widely from 7.5% to 75%.<sup>5</sup> Pre-existing astigmatism is present in over 60% of all patients scheduled for cataract surgery<sup>6</sup>. It is thought that 3% to 15% of eyes may have 2 or more dioptres (D) of astigmatism,<sup>7</sup> and 15% to 25% of cataract patients undergoing surgery have more than 1.5 D of astigmatism.<sup>8</sup> There are several methods to correct pre-

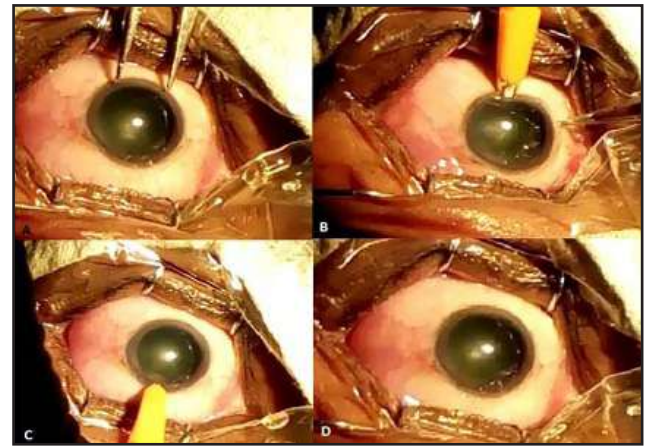
existing astigmatism during cataract surgery. They include astigmatic keratotomy (AK), limbal relaxing incisions (LRI's), corneal relaxing incisions (CRI's), toric intraocular lenses and axis alignment of phacoemulsification. Limbal relaxing incision is one of the most commonly perform additional procedures during phacoemulsification mainly due to the ease of the technique and a safe and predictable surgical profile. The present study was designed to evaluate the effect of LRI in reducing the pre-existing astigmatism at the time of phacoemulsification with intraocular lens implant surgery and its stability over a period of time.

## Methods

This was a prospective interventional study. All patients with pre-existing astigmatism of  $\geq 1$  D undergoing an elective phacoemulsification were included. The study was approved by the ethics committee of the hospital and followed the tenets of the Declaration of Helsinki. An informed consent was obtained from all the participants. Patients with keratoconus, irregular astigmatism, other associated corneal disorders, thin corneas, dry eyes, history of previous ocular surgery or trauma, peripheral corneal thinning, posterior segment pathologies or collagen vascular diseases, were excluded. The preoperative evaluation consisted of detailed clinical history, ophthalmic examination, uncorrected visual acuity (UCVA), best-corrected visual acuity (BCVA), cycloplegic refraction, measurement of intraocular pressure, manual keratometry (Bausch & Lomb, USA), automated keratometer. Corneal topography (Orbscan) was performed preoperatively to screen for keratoconus. In addition, tear film evaluation was done using the Schirmer's test and tear break up time. Ultrasound pachymetry was performed in cases with suspected peripheral corneal thinning.

**Surgical technique-** In all cases orientation marks were placed at 6 and 12 'o' clock positions preoperatively on a slit lamp. All surgeries were performed using topical or subtenon's anesthesia. We used the Louis D. "Skip" Nichamin nomogram for LRI in order to determine the extent of arc to be incised. Limbal relaxing incisions were made at the onset of surgery. Steep meridian was identified by aligning the Mendez ring with previously placed orientation mark. Empirical blade setting of 600 microns was used in a diamond blade. Limbal relaxing incisions were made at the most peripheral extent of clear corneal tissue, just inside the true surgical limbus after achieving good fixation of the globe. Subsequently, a temporal incision phacoemulsification was performed using the standard phaco-chop technique. A foldable intraocular lens (Acrysof, Alcon Labs, Fort Worth, Texas,

US) was implanted in the capsular bag. All surgeries were performed by a single surgeon. Postoperative antibiotics and corticosteroid eye drops were continued for four weeks. Cycloplegic and anti-glaucoma eye drops were used whenever deemed necessary. Cases that required suturing of the wound or enlargement of the incisions were excluded from the final analysis. The main outcomes measures included UCVA, BCVA and astigmatism at the last follow-up. Data was collected and statistical analysis was done using  $\chi^2$  test, Student t test, and probability tests. A p-value of  $<0.05$  was considered to be significant.



## Results

A total of 200 eyes of 200 patients were included during the study period. Overall, 115(57.50%) males and 85(42.50%) females with a mean age of  $58.075 \pm 11.581$  years (range: 30-89 years) were operated. Majority of the patients (n=161, 80.55%) had immature cataract, 20 (10%) patients had a mature cataract, 18 (9%) patients had posterior subcapsular cataract and 1 (0.5%) patient had posterior polar cataract. Pre operatively all the patients had BCVA  $\leq 6/9$ . Preoperatively 98.5% patients had BCVA of  $\leq 20/60$  and 54% had BCVA of  $\leq 20/200$ . Of the 200 patients, 154 (77%) had against the rule astigmatism and 46 (23%) had with the rule astigmatism. The mean preoperative astigmatism was  $1.58545D \pm 0.55D$ . All the patients completed 6 months follow up postoperatively. The mean postoperative astigmatism was  $0.509D \pm 0.29$  D at 1 week and  $0.479D \pm 0.26$  D at the end of 6 weeks after surgery. The mean astigmatism was further reduced to  $0.448 \pm 0.25D$  6 months postoperatively. The change in the amount of astigmatism was statistically significant at all time points when compared to the preoperative values ( $p < 0.001$ ). However, the reduction in astigmatism was not significant between these follow-up periods ( $p = 0.09$ ) (Table 1).

Astigmatism	Preop (Mean $\pm$ SD)	1 week (Mean $\pm$ SD)	6 weeks (Mean $\pm$ SD)	6 months (Mean $\pm$ SD)
Total (dioptres)	1.585D $\pm$ 0.55	0.5094D $\pm$ 0.29	0.479D $\pm$ 0.26	0.448D $\pm$ 0.25
WTR (dioptres)	1.578D $\pm$ 0.48	0.5154D $\pm$ 0.25	0.493D $\pm$ 0.25	0.456D $\pm$ 0.22
ATR (dioptres)	1.587D $\pm$ 0.57	0.5141D $\pm$ 0.3	0.475D $\pm$ 0.2	0.446D $\pm$ 0.26

We also compared the reduction in astigmatism after surgery in different age groups. Mean astigmatism was lower in older age group (70-90 years) as compared to younger patients ( $p=0.2461$ ). There was no statistically significant difference between the amount of reduction over the follow-up period of 6 months amongst different age groups ( $p=0.062$ ) (Table 2).

Age group (years)	N	Preoperative astigmatism (dioptres)	Postoperative astigmatism (dioptres)		
			1 week	6 weeks	6 months
30- 49	59	1.477 ± 0.38	0.490 ± 0.22	0.482 ± 0.21	0.436 ± 0.22
50- 69	107	1.594 ± 0.56	0.495 ± 0.26	0.472 ± 0.26	0.458 ± 0.26
70- 90	34	1.745 ± 0.69	0.584 ± 0.46	0.501 ± 0.35	0.438 ± 0.29

Patients were divided into 3 groups (1-2 D, 2.1-3 D and 3.1-4 D) based on the amount of preoperative astigmatism for further analysis. We did not find any statistically significant difference in the postoperative outcomes amongst patients with in these groups ( $p>0.05$ ) (Table 3).

Astigmatism (dioptres)	Preoperative astigmatism (dioptres) Mean ± SD	Postoperative astigmatism (dioptres)		
		1 week	6 weeks	6 months
		Mean ± SD	Mean ± SD	Mean ± SD
1 – 2 (n=169)	1.402± 0.324	0.436 ± 0.243	0.414 ± 0.223	0.393 ± 0.221
2.1 – 3 (n=27)	2.462 ± 0.266	0.865 ± 0.180	0.812 ± 0.184	0.726 ± 0.181
3.1 – 4 (n=4)	3.437± 0.239	1.187 ± 0.314	1.037 ± 0.149	0.917 ± 0.117

At the end of 6 months after surgery, 69 (34.5%) patients <0.25 D, 117 (58.5%) had 0.26-0.75 D, and 14 (7%) patients > 0.76 D astigmatism. There was no significant difference seen in correction of astigmatism between males and females (Table 4).

Sex	N	Preoperative astigmatism (dioptres) Mean ±SD	Postoperative astigmatism (dioptres) Mean ± SD		
			1 week	6 weeks	6 months
Males	115	1.554± 0.56	0.491± 0.26	0.471± 0.25	0.435± 0.25
Females	85	1.627± 0.53	0.533±0.32	0.492± 0.28	0.466± 0.25

### Post operative visual acuity

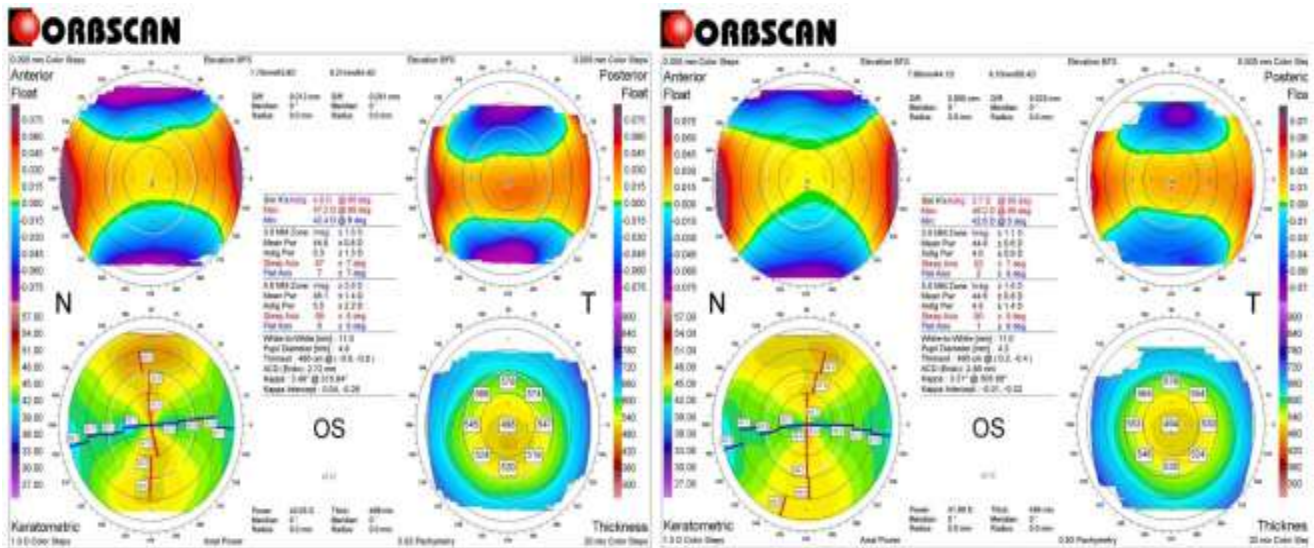
Postoperatively at 1 week the UCVA was  $\geq 6/6$  in 34.5% patients and  $\geq 6/12$  in 91% of patients. At the end of 6 weeks, UCVA was  $\geq 6/12$  in 94.5% patients. At the last follow-up (6 months) 94.5% cases had UCVA and 99.5% cases had BCVA of  $\geq 6/12$  respectively (Table 5). Both uncorrected ( $p=0.0004$ ) and best-corrected visual acuity ( $p=0.0006$ ) showed statistically significant improvement when compared with preoperative levels.

	Uncorrected visual acuity			Best-corrected visual acuity		
	1 week (N)	6 weeks (N)	6 months (N)	1 week (N)	6 weeks (N)	6 months (N)
$\geq 6/6$	69	83	74	195	197	197
6/9	87	72	79	3	1	1
6/12	26	34	36	1	1	1
6/18	11	9	8	0	1	1
6/24	6	2	3	1	0	0
6/36	1	0	0	0	0	0

### Change in the post operative axis

Postoperatively change in the axis was analyzed shows shift of axis of less than 15 degrees compared to the preoperative value in 188 (94%) patients at 6 months follow-up. None of the patients had induced irregular astigmatism.

Shift in astigmatism axis (degrees)	Number of eyes		
	1 week	6 weeks	6 months
< 15	195	194	188
15-30	5	6	12



Preoperative and postoperative (1 month) Topography of a single limbal relaxing incision with clear corneal incision.

Complications-Intraoperative extensions of the LRI incisions towards the sclera (n=1, 0.5%) and cornea (n=3, 1.5%) occurred in 4 (2%) cases. Immediate postoperative foreign body sensation possibly due to wound edge gaping was noted in 21 patients (10.5%) who were managed by patching and preservative-free artificial tear drops. Among the late postoperative complications mild dry eyes and foreign body sensation was noted in 36 (18%) patients who were treated with artificial tears. Two cases (1%) had an epithelial defect and required bandage contact lens application. Wound site infiltration was noted in 1 case (0.5%) which was successfully treated with fortified antibiotics.

### Discussion

Astigmatism is one of the most common causes of suboptimal vision after an otherwise uneventful cataract surgery. There are several approaches to correcting astigmatism at the time of cataract surgery. They include incision placement on the steep axis of the cornea, opposite clear corneal incisions, single or paired peripheral limbal relaxing incisions and toric IOL implantation. These can be used alone or in combination. LRIs seem to be a viable option for reducing pre-existing astigmatism at the time of cataract surgery. LRIs flatten the meridian of the cornea in which they are placed and there is a coupling effect due to which the meridian 90° away steepens. In a prospective single center study, Kaufmann et al compared the efficacy of on-axis incisions (n=33) and LRIs (n=38) during temporal phacoemulsification.<sup>11</sup> After 6 months, the flattening effect was 0.35 D and 1.10 D in both groups respectively. In another study Arraes et al studied the effect of LRIs using Gills nomogram in 16 patients undergoing cataract surgery by phacoemulsification through an incision of 5.5 mm scleral tunnel.<sup>12</sup> Two limbal relaxing incisions of 8 and 6 mm aiming to correct preoperative astigmatism of 2 to 3D and

1 to 2D, respectively, were found to be safe and effective with a stable effect in the first postoperative follow-up year. Budak et al evaluated the effectiveness of LRIs for correcting astigmatism in 22 eyes of 13 patients using a modified Gills nomogram.<sup>13</sup> An absolute decrease of 0.91 D in mean astigmatism was achieved after 6 months in all eyes. In our study, the use of limbal relaxing incisions during phacoemulsification significantly reduced preoperative astigmatism. Additionally, the refraction remained stable in the eyes treated with LRIs in the postoperative period. The astigmatic correction with LRIs stabilised early and remained stable over a period of 6 months (p > 0.05) with no regression noted during the follow-up. There was a trend towards increased amount of correction with increasing age (p > 0.05). It is well known that the corrective effect of incisional keratotomies increases with age. Furthermore, the amount of correction did not depend on the amount of preoperative astigmatism. In the present study both UCVA and BCVA improved significantly after the surgery. Best-corrected visual acuity of  $\geq 6/9$  was achieved in 100% of cases at the last follow up. Most complications encountered in our study after LRIs were mild and visually non-significant except for dry eyes and foreign body sensation that was manageable with artificial tear drops. In a large-scale epidemiologic study, the prevalence of dry-eye syndrome was up to 33% and in another study 14.4% of patients aged reported dry eye symptoms.<sup>14</sup> Wound infection occurred in one case and was treated successfully with topical antibiotics. The major limitation of the present study is the absence of a comparison group. However, our study demonstrates that LRI is an easy, safe, and efficient method for the concurrent management of astigmatism at the time of cataract surgery.

**Financial support and sponsorship-None**

**Conflicts of Interest- None**



## References

1. Carvalho M, Suzuki S, Freitas L, Branco B, Schor P, Lima A. Limbal Relaxing Incisions to Correct Corneal Astigmatism During Phacoemulsification. *J Refract Surg.* 2007; 23: 499-504.
2. Müller-Jensen K, Fischer P, Siepe U. Limbal relaxing incisions to correct astigmatism in clear corneal cataract surgery. *J Refract Surg.* 1999 Sep-Oct;15(5):586-9.
3. Bayramlar H, Dağlioğlu MC, Borazan M. Limbal relaxing incisions for primary mixed astigmatism and mixed astigmatism after cataract surgery. *J Cataract Refract Surg.* 2003 Apr;29(4):723-8.
4. Chylack LT Jr, Leske MC, McCarthy D, Khu P, Kashiwagi T, Sperduto R. Lens opacities classification system II (LOCS II) *Arch Ophthalmol.* 1989 Jul;107(7):991-7.
5. Kaufmann C, Peter J, Ooi K, Phipps S, Cooper P, Goggin M; Queen Elizabeth Astigmatism Study Group. Limbal relaxing incisions versus on-axis incisions to reduce corneal astigmatism at the time of cataract surgery. *J Cataract Refract Surg.* 2005 Dec;31(12):2261-5.
6. Ferrer-Blasco T, Montés-Micó R, Peixoto-de-Matos SC, González-Méijome JM, Cerviño A. Prevalence of corneal astigmatism before cataract surgery. *J Cataract Refract Surg.* 2009 Jan;35(1):70-5.
7. Eliwa TF, Abdellatif MK, Hamza II. Effect of Limbal Relaxing Incisions on Corneal Aberrations. *J Refract Surg.* 2016 Mar;32(3):156-62.
8. Gibbons A. Use of a Toric Intraocular Lens and a Limbal-Relaxing Incision for the Management of Astigmatism in Combined Glaucoma and Cataract Surgery. *Case Reports in Ophthalmology.* 2016 Feb 23;7(1):96-102.
9. Hashemi H, Khabazkhoob M, Soroush S, Shariati R, Miraftab M, Yekta A. The location of incision in cataract surgery and its impact on induced astigmatism. *Curr Opin Ophthalmol.* 2016 Jan;27(1):58-64.
10. Mohammad-Rabei H, Mohammad-Rabei E, Espandar G, Javadi MA, Jafarinasab MR, Hashemian SJ, Feizi S. Three methods for correction of astigmatism during phacoemulsification. *Journal of Ophthalmic & Vision Research.* 2016 Apr;11(2):162.
11. Kaufmann C, Peter J, Ooi K, Phipps S, Cooper P, Goggin M; Queen Elizabeth Astigmatism Study Group. Limbal relaxing incisions versus on-axis incisions to reduce corneal astigmatism at the time of cataract surgery. *J Cataract Refract Surg.* 2005 Dec;31(12):2261-5.
12. ARRAES, João Carlos et al. Limbal relaxing incisions during cataract surgery: one-year follow-up. *Arq. Bras. Oftalmol.* [online]. 2006, vol.69, n.3, pp.361-364. ISSN 0004-2749.
13. Koray Budak, Neil J. Friedman, Douglas D. Koch, Limbal relaxing incisions with cataract surgery, *Journal of Cataract & Refractive Surgery*, Volume 24, Issue 4, 1998, Pages 503-508,
14. Lee AJ, Lee J, Saw SM, et al. Prevalence and risk factors associated with dry eye symptoms: a population based study in Indonesia. *Br J Ophthalmol.* 2002;86(12):1347-1351. doi:10.1136/bjo.86.12.1347

## Case report

# Ocular pemphigus masquerading as Ocular Surface Squamous neoplasia (OSSN)

Dr Shylaja Shivashankarappa<sup>1</sup>

<sup>1</sup> Department of Cornea, Narayana Netralaya, Bengaluru

### Introduction

Pemphigus Vulgaris (PV) is an autoimmune disease that affects mucocutaneous surfaces. The most common presenting sign is oral mucosal ulceration, but all stratified squamous epithelial mucosal surfaces can be involved. In PV, autoantibodies bind to the keratinocyte desmosomal proteins (desmogleins 1 and 3) and to desmosome-free areas of the keratinocyte cell membrane resulting in acantholysis.<sup>1</sup> PV diagnosed by histopathology and immunofluorescence of the conjunctiva. The ocular signs in PV patients can vary greatly, most common ocular presentation is non-cicatricial conjunctivitis and rarely erosions on the eyelids and conjunctiva.<sup>1,2</sup> Atypical presentation characterized by conjunctival scarring and corneal perforation have also been reported.<sup>3,4</sup> Progressive scarring & blindness is not seen in PV unlike cicatricial pemphigoid. We report a gelatinous conjunctival lesion involving palpebral and bulbar conjunctiva in immunopathologically proven pemphigus vulgaris which mimicked like OSSN.

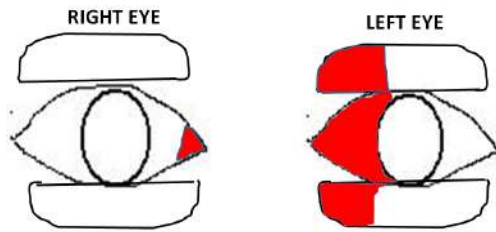
### Case Description

A 27-year-old male patient complained of redness & mucoid discharge in both eyes associated with growth in left eye since one year. Four years back he was diagnosed with systemic pemphigus vulgaris (PV) by the dermatologist and was on treatment with tapering dose of oral steroids (prednisolone 1mg/kg) and Cyclophosphamide 50 mg tablet once in 3 days. Dermatological evaluation showed facial scars and oral cavity showed gingival ulcers. Mucosal and cutaneous lesions healed with postinflammatory hyperpigmentation. Gingival ulcer was treated with local application of chlorhexidine gel and of Triamcinolone acetonide buckle paste three times daily for 1 week. Ophthalmic examination showed BCVA of 6/9p in the Right eye and 6/12 in the left eye. Right eye examination showed diffuse gelatinous lesion involving caruncle (white arrow) & plica semilunaris (black arrow)[Figure 1A & Figure 2] Faint punctate corneal epithelial scar mimicking EKC scar (black thin circle) and sub epithelial fibrosis in lower tarsal conjunctiva in RE (purple thick arrow)[Figure 1B]. Symblepharon formation in lower fornix (red arrow)[Figure 1C]. Left eye examination showed, bald/ featureless upper tarsal conjunctiva with mild mucoid discharge (white arrow)[Figure 1D]. Symblepharon formation in the lower fornix (white arrow)[Figure 1E]. Diffuse gelatinous lesion involving caruncle (white arrow), Plica Semilunaris (blue arrow) & nasal bulbar conjunctiva till limbus [Figure 1F]. Diffuse gelatinous lesion with abnormal vascularity extended horizontally from nasal limbus to caruncle & vertically from nasal 1/3<sup>rd</sup> of upper palpebral conjunctiva to lower 1/3<sup>rd</sup> of palpebral conjunctiva including

the punctum, clinically mimicking OSSN (white dotted line) [Figure 1G & Figure 2]. Multiple conjunctival & limbal vesicles – (black arrow)[Figure 1G]. Elevated gelatinous lesion extended (white dotted lines) along the nasal limbus from 7 ° clock -11° clock [Figure 1H]. Fluorescein staining due to non-uniform distribution of tear film (because of elevated limbal lesion)[Figure 1I]. Lissamine staining was negative. Faint punctate corneal epithelial scar mimicking EKC scar and sub epithelial fibrosis of lower tarsal conjunctiva noted. Provisional diagnosis of OSSN with Discoid scars on cornea (BE) with Systemic PV was made. Both eyes were treated with Topical prednisolone acetate 4 times daily, topical artificial tears eye drops (QID), Tacrolimus Ointment 0.03% at bedtime, lubricating gel at bedtime. ELISA for Desmoglein 1 & 3 was done to know the disease progression & to monitor the dosage of systemic cyclophosphamide.

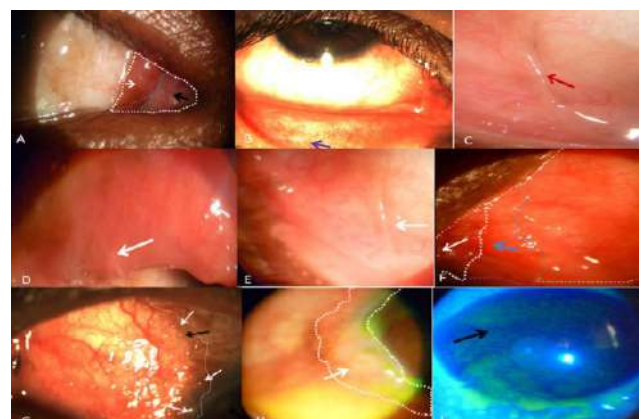

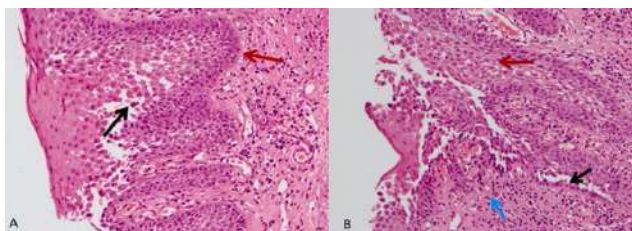
Figure 1-(1A-1I)- Showing ocular features seen in both eyes;



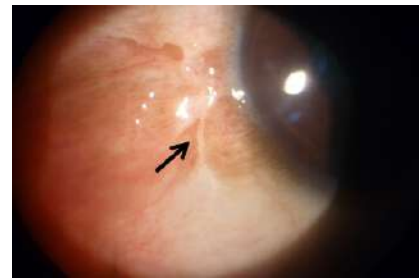
**Figure 2-** Pictorial representation of extent of gelatinous lesions

Investigations included; Immunofluorescence showed intercellular fluorescence for IgG (2+) & C3 (1+) in surface epithelium suggestive of pemphigus vulgaris and negative for IgA& IgM ruling out pemphigoid. Based on the understanding of the current diagnosis and atypical presentation, an excisional biopsy was performed. Excision biopsy specimen of left eye on histopathology showed acantholysis, intact BM, moderate superficial nonspecific acute on chronic stromal inflammation and no evidence of dysplasia / paraneoplastic pemphigus. Conjunctival epithelium showed acantholysis resulting in vesicle formation (black arrow) [Figure 3A]. Acantholytic cells are rounded, nucleated keratinocytes formed due to antibody mediated damage to cell adhesion protein: Desmoglein]. Intact basement membrane (red arrow)[Figure 3A] and absent dysplastic cells rules out invasive OSSN. Epithelium was hyperplastic & papillomatosis (red arrow) [Figure 3B]. Basal keratinocytes still attached to the basement membrane leading to the “Tombstone” appearance (black arrow)[Figure 3B]. Stroma showed moderate superficial nonspecific acute on chronic inflammation (blue arrow) [Figure 3B]. At 6 months follow-up, patient continues to be asymptomatic with no signs of recurrence. Post treatment sub epithelial scarring in nasal bulbar conjunctiva with no recurrence [Figure 4].

**Figure 3-(A&B)** - Histopathology of conjunctival specimen of the left eye



**Figure 4-** Post treatment sub epithelial scarring in nasal bulbar conjunctiva with no recurrence



## Discussion

Pemphigus vulgaris has varied presentations. ELISA and immunofluorescence techniques may be used to confirm definitive diagnosis.<sup>5</sup> Severity of ocular involvement does not necessarily indicate severity of systemic disease.<sup>6</sup> Mild ocular cases can be controlled with topical corticosteroid therapy, severe cases, especially those with an erosive form may require further treatment options, including systemic corticosteroids or systemic immunosuppressants or immunomodulators and intravenous immunoglobulins.<sup>7,8</sup> Ocular PV is limited to the conjunctiva and eyelids and has no effect on visual acuity. But our case had corneal opacities secondary to corneal erosions. Usually histopathology is not needed in classical ocular PV. However, mass lesion on conjunctiva (with or without corneal involvement) warrants histopathologic confirmation<sup>1</sup> Our patient had ocular findings masquerading as OSSN, with histopathology & direct immunofluorescence study definitive diagnosis of ocular PV was made & OSSN was ruled out. Systemic cyclophosphamide was monitored by the physician and topical lubricating eye drops were continued in both eyes.

Conclusion-Any ocular surface lesion with systemic mucocutaneous disorder should raise suspicion of its varied presentation and warrant biopsy with further histopathologic and immunofluorescence evaluation can facilitate early diagnosis and treatment. Topical steroid therapy with systemic immunosuppression seems to be satisfactory in the treatment of ocular PV associated with conjunctival inflammatory mass lesion masquerading as OSSN.

**Financial disclosure and sponsorship- None**

**Conflicts of Interest- None**

## References

1. Daoud YJ, Cervantes R, Foster CS, Ahmed AR. Ocular pemphigus. *J Am Acad Dermatol.* 2005; 53: 585–590.
2. Palleschi GM, Giomi B, Fabbriet P. Ocular involvement in pemphigus. *Am J Ophthalmol.* 2007; 144: 149–152
3. Lifshitz T, Levy J, Cagnano E, Halevy S. Severe conjunctival and eyelid involvement in pemphigus vulgaris. *Int Ophthalmol.* 2004; 25:73–74.
4. Baykal HE, Pleyer U, Sonnichsen K, Thiel HJ, Zierhut M. Severe eye involvement in pemphigus vulgaris. *Ophthalmologe.* 1995; 92:854–857
5. Elchahal S, Kavosh ER, Chu DS. Ocular manifestations of blistering diseases. *Immunol Allergy Clin North Am.* 2008; 28:119–136
6. Palleschi GM, Giomi B, Fabbri P. Ocular involvement in pemphigus. *Am J Ophthalmol.* 2007; 144:149–152.
7. Olszewska M, Komor M, Mazur M, et al. Response of ocular pemphigus vulgaris to therapy. Case report and review of literature. *J Dermatol Case Rep.* 2008;29:1–3.
8. Kozeis N, Tyradellis S, Dragiotis E, et al. Triamcinolone acetonide for rare ocular manifestations of pemphigus vulgaris: a case report. *Clin Ophthalmol.* 2010;26:365–368

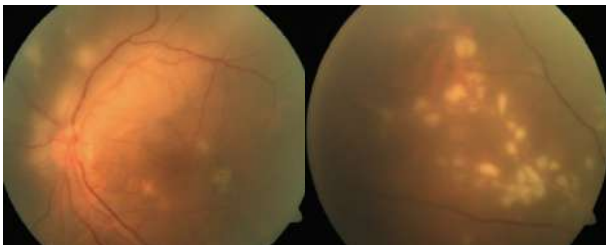
## Case report

# Vitreoretinal Lymphoma masquerading as posterior Uveitis

Dr Prakash VS<sup>1</sup>

<sup>1</sup>Comtrust charitable Trust Eye Hospital, Kozhikode, Kerala

65 year old gentleman, with history of 2 renal transplants -1999 and 2010. Was on treatment with Wysolone, Azoran, and Cyclosporine. He had Bone tuberculosis in 2012. came with history of sudden diminution of vision in left eye for the past 4 days. BCVA in RE was 6/9 and in left eye it was CF. Anterior segment showed Cells 1+, no KPS, no synechiae, and Vitreous Grade 2 cells. Fundus examination of left eye showed mild vitreous haze with multiple subretinal infiltration.



### Differential Diagnosis

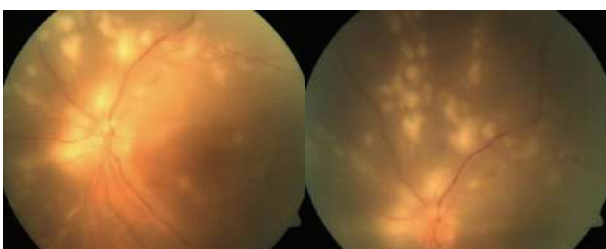
- Endogenous Endophthalmitis
- Toxoplasmosis
- CMV retinitis
- Ocular tuberculosis

### Plan of Management

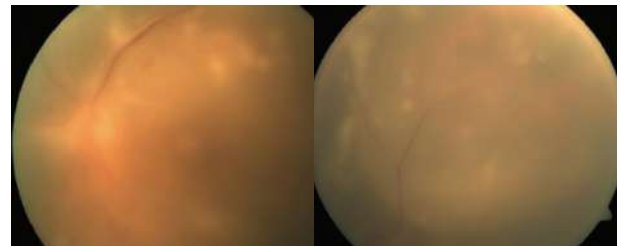
- Vitreous tap + intravitreal vancomycin
  - Routine microbiology
  - Excyton study for Viral (HSV1&2, VZV CMV) TB and Toxoplasma
- Routine blood Investigations were normal
- Good renal function
- Toxoplasma Ig G +ve but Ig M negative- Started Anti toxoplasma treatment

### Patient was reviewed after 5 days-Vision dropped in left eye to HM

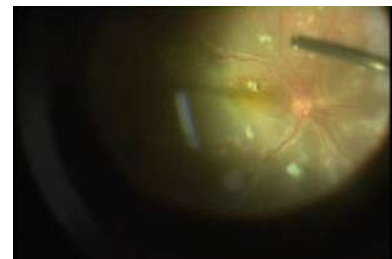
- Excyton study results were negative
- Empirically started on Valganciclovir



Reviewed after one week of valganciclovir treatment- Vitritis increased, PVD developing, Lesions increased in size & more confluent

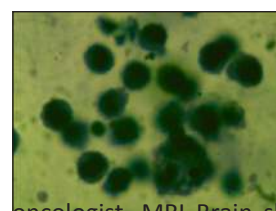
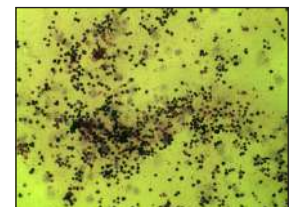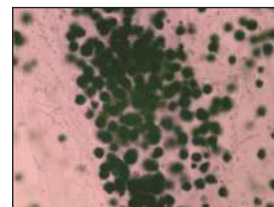


- Posted for Vitreous biopsy -On table shallow Superior RD, Entire vitreous specimen, SRF, and fragments of retina from the edge of break taken, Fluid Air Exchange +Endo laser + Silicon oil injection was done. Specimen Sent for Excyton – Bacterial, fungal, Toxoplasma, CMV and TB as well as for routine microbiology



One sample was sent for Cytopathology to R/O LYMPHOMA -PATHOLOGIST INFORMED AND SAMPLE PROCESSED IMMEDIATELY AND WAS ASKED TO LOOK FOR LYMPHOMA/ CMV INCLUSION BODIES

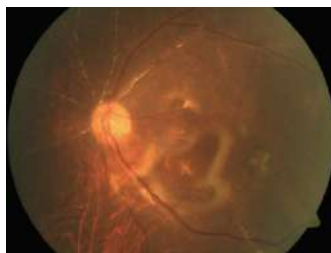
CYTOPATHOLOGY REPORT SHOWED NON HODGKINS LYMPHOMA, IL 10/1L6 RATIO WAS GREATER THAN 1



Was evaluated by medical oncologist. MRI Brain showed – few nonspecific white

matter lesions and Optic nerve thinning Left side, CSF study, Bone marrow biopsy and PET scan were normal

Treatment-Monthly Intravitreal Methotrexate 400 µg was given till complete resolution of lesions. Retina well attached with BCVA in LE 3/60.



Patient was put on reduced dose of immunosuppressives. Patient underwent SOR after 6 months. Fluid was sent for cytology - Negative for malignant cells. Renal

function started worsening and was put back on immunosuppressant by nephrologist. Develops cognitive disturbances with rapid deterioration to coma and died probably due to CNS lymphoma.

### Treatment recommendations Primary Intra Ocular Lymphoma (PIOL)

#### 1. Intraocular Lymphoma alone

XRT to eyes only, Systemic Chemotherapy

#### 2. Intraocular and CNS Lymphoma

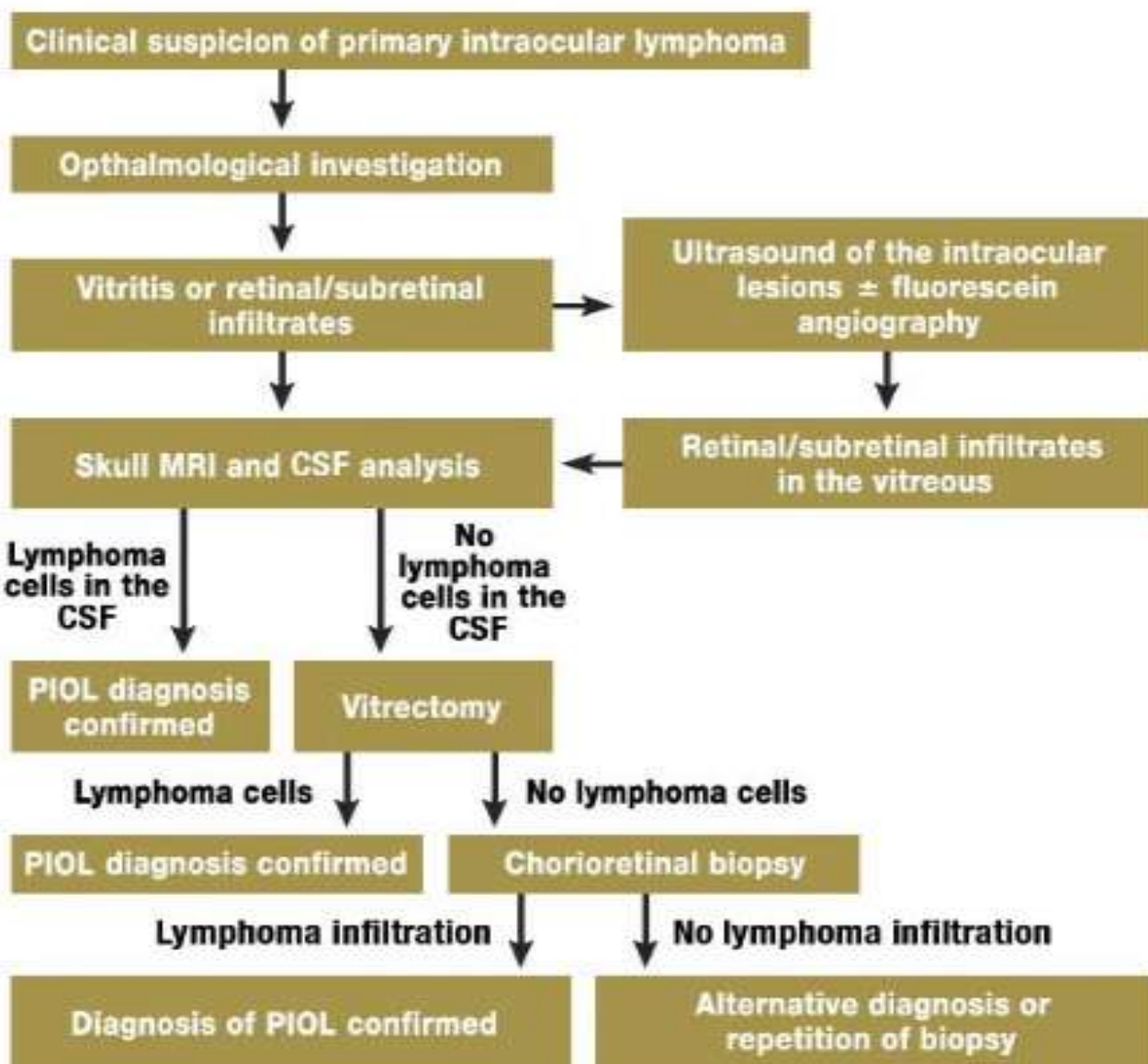
XRT to eyes + / - BRAIN

Systemic Chemotherapy

#### 3. Recurrent Intraocular Lymphoma

Intravitreal salvage chemotherapy with Methotrexate, Rituximab, and Anti CD-20 Monoclonal antibody. Requires multiple intravitreal injections

### Flow chart- how to approach a case of Primary Intraocular Lymphoma



## Case report

# Bilateral combined Central retinal artery & vein occlusion (CCRAVO) in a COVID-19 patient

Dr Sunil Ganekal,<sup>1</sup> Dr Nirmal Prasad <sup>2</sup>

<sup>1,2</sup> Davangere Netralaya, Davangere, Karnataka

### Abstract

To report a case of a male patient who gave history of fever, dry cough, dyspnea and he was tested positive for COVID-19 by Reverse Transcriptase-PCR from the nasopharynx. Presented with bilateral sudden onset of decreased vision due to combined central retinal artery and vein occlusion (CCRAVO), patient was treated with systemic medication including anticoagulant treatment and Intravitreal bevacizumab, visual recovery was limited in spite of treatment.

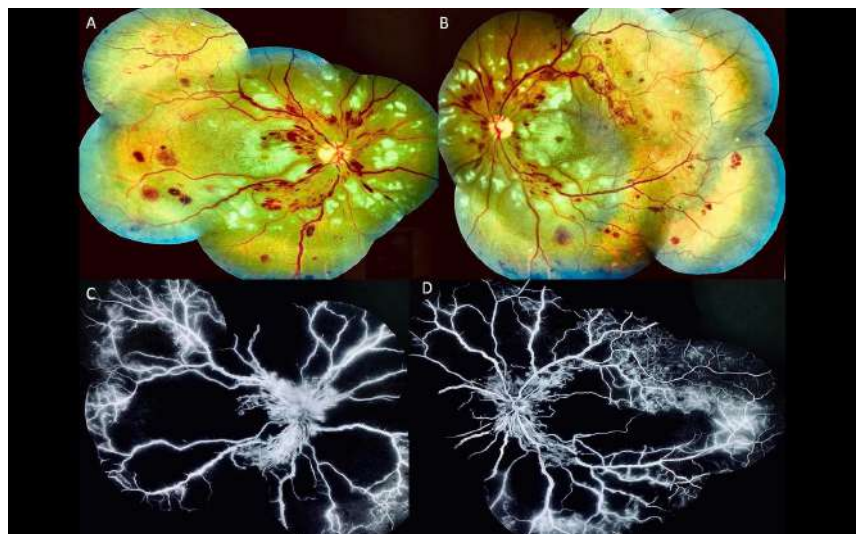
**Keywords-** Combined central retinal artery and vein occlusion, COVID-19

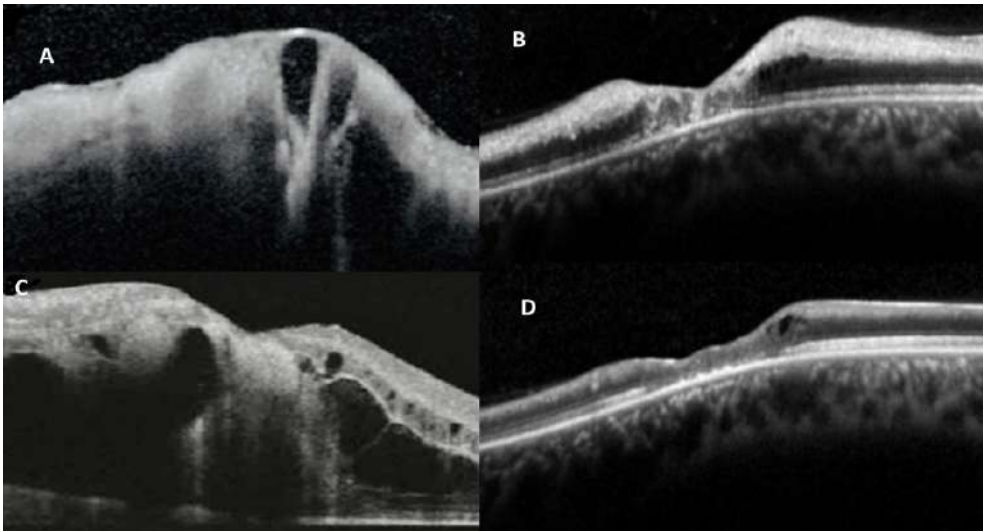
### Introduction

The incidence of thrombotic complications in patients with COVID-19 infection is elevated due to multiple factors and is associated with poorer outcomes.<sup>1, 2</sup> Hypercoagulability associated with COVID-19 has been described as a “sepsis-induced coagulopathy”.<sup>3</sup> Such thrombotic events lead to retinal vascular occlusion. We report a rare case of combined retinal artery and vein occlusion in COVID 19 patient which has not been reported before.

### Case Description

A 36 year-old man without any preexisting systemic co morbidities presented with fever, cough, and progressive dyspnea (SpO2-88%). RNA Reverse Transcriptase-PCR from the nasopharynx was positive for COVID-19. After 2 days of initial symptoms patient developed severe breathlessness and the CT Scan showed bilateral patchy middle and lower field pulmonary infiltrates. He was shifted to ICU for acute hypoxemic respiratory distress and received COVID-19-directed therapy including azithromycin, tocilizumab, remdesivir and pulse steroid therapy. He remained in the intensive care for total seven days and on stabilization he was shifted from ICU to medical ward for further management, on the thirteenth day since the onset of COVID-19 symptoms patient complained of sudden onset of painless profound loss of vision in both eyes. On examination both eyes had visual acuity of perception of light, pupillary reaction was ill sustained in both eyes. Anterior segment examination and ocular motility were normal. Dilated fundus examination of both eyes showed mild disc edema, attenuated arteries and dilated veins with scattered peripapillary hemorrhages, cotton wool spots and retinal hemorrhages in all the quadrants. Area of retinal edema with whitening noted over the posterior pole, with this diagnosis of combined retinal artery and vein occlusion was made (Figure 1A &1B). For further confirmation of diagnosis and management patient underwent OCT and fundus fluorescein angiography (FFA). FFA showed (Figure 1C&1D) absence





of flow in both retinal artery and retinal veins with associated large area of capillary non perfusion over the posterior pole and retinal periphery. Vessel wall staining noted in few quadrants. OCT examination (Figure 2A&2C) showed increased reflectivity in the inner retinal layers and diffuse macular edema (CMT RE-985 $\mu$  and LE-916  $\mu$ ). Choroidal details could not be appreciated. Patient underwent work up for hypercoagulable

state (hereditary or acquired thrombophilia factors), vasculitic syndromes, blood hyperviscosity, and other recognized systemic vascular inflammatory disorders. Laboratory work-up after the onset of visual symptoms revealed no pathological findings in blood analysis comprising Blood sugar, lipid profile, homocysteinemia, anti-cardiolipin IgM and IgG antibodies, and screening for genetic thrombophilia (Factor V Leiden and prothrombin mutations, antithrombin III and proteins C and S deficiencies), ANA, C-ANCA, P-ANCA, ds DNA, but showed elevated Inflammatory markers; D-Dimer (>1050 ng/ml; normal range <255ng/ml), serum ferritin (615.30 ng/ml; normal range 22-274ng/ml), CRP (13mg/L; Normal range <10mg/L), pro-calcitonin (0.16 ng/ml; normal  $\leq$  0.07 ng/ml). Coagulation profile showed; fibrinogen (546 mg/dl; normal range 200–400 mg/dl), prothrombin time (17.6 s; normal range 11.9–14.4 s), international normalized ratio (1.5; reference range 0.8–1.3), partial thromboplastin time (36 s; normal range 22–37 s). Haemogram showed mild lymphopenia ( $0.66 \times 1000 \mu\text{l}$ ) and thrombocytosis ( $412 \times 1000 \mu\text{l}$ ). MRI of the brain and orbits and CT angiogram head and neck were normal. Transthoracic echocardiogram was unremarkable. Considering thrombotic microangiopathy as the cause for combined retinal vascular occlusion, patient was started on anticoagulant enoxaparin 1 mg/kg twice daily therapy along with standard COVID-19 treatment protocol. Patient was treated with Intravitreal anti VEGF (Bevacizumab, 1.25 mg/0.05 ml) and then second intravitreal dose was given after 4 weeks and was asked to continue systemic medications including tapering oral steroids as advised by the physician. Patient was followed up at 1 week, 1 month and 2 months. There was partial improvement in best corrected visual acuity in both eyes (1/60 both eyes) at the end of 2 months. At the last follow up of 2 months, OCT of both eyes showed resolution of macular edema but associated retinal thinning (Figure 2B&2D).

## Discussion

There are no published reports of combined bilateral retinal artery and vein occlusion in COVID-19 patients and these patients are at risk of presenting venous and arterial thrombotic events. COVID-19 infection is associated with coagulation activation and a disproportionate systemic inflammatory response.<sup>4,5</sup> Whether the coagulation cascade is directly activated by the virus or whether this is the result of local or systemic inflammation is not completely understood. The three main factors involved in the pathogenesis of coagulopathy in patients with COVID-19 are: 1) Endotheliitis, which causes vasoconstriction, 2) hyper-inflammation and cytokine storm which activates clotting factors, 3) stasis and hypoxia activates coagulation mechanisms.<sup>6</sup> Ocular manifestations such as anterior uveitis, retinitis, and optic neuritis have been only documented in animal models.<sup>7</sup> Previous studies have reported CRAO, papillophlebitis and isolated CRVO secondary to COVID-19.<sup>3,8</sup> In COVID-19 due to venous or arterial thromboembolic complications an evaluation for hypercoagulable disorders must be considered. In our patient, an interdisciplinary exploration process and a complete thrombophilia study was performed and the only findings were consistent with a hypercoagulable state induced by the COVID-19 infection and treated accordingly with anticoagulant (enoxaparin) and intravitreal bevacizumab but with limited post treatment visual recovery.

## Conclusion and clinical significance

Ophthalmologists must be prepared to treat vision threatening retinal vascular occlusions in the intermediate stages of COVID-19. Evidence of venous and arterial thromboembolic events in these patients suggest that pharmacologic anticoagulation prophylaxis may benefit hospitalized patients with confirmed or highly suspected COVID-19.

**Financial Disclosure- None**

**Conflicts of Interest- None**

## References

1. Tang N, Li D, Wang X, Sun Z. Abnormal coagulation parameters are associated with poor prognosis in patients with novel coronavirus pneumonia. *J Thromb Haemost.* 2020; 18(4):844-847.
2. Llitjos J.F, Leclerc M, Chochois C. High incidence of venous thromboembolic events in anticoagulated severe COVID-19 patients. *J Thromb Haemost.* 2020; 18(7):1743-1746.
3. Acharya S, Diamond M, Anwar S, Glaser A, Tyagi P. Unique case of central retinal artery occlusion secondary to COVID-19 disease. *IDCases.* 2020;21:e00867. doi: 10.1016/j.idcr.2020.e00867. Epub 2020 Jun 18. PMID: 32572363; PMCID: PMC7301806.
4. Wu Z, McGoogan JM. Characteristics of and important lessons from the coronavirus disease 2019 (COVID-19) outbreak in China: summary of a report of 72,314 cases from the Chinese Center for Disease Control and Prevention. *JAMA* 2020; 323(13): 1239–1242.
5. Marietta M, Ageno W, Artoni A, De Candia E, Gresele P, Marchetti M, et al. COVID-19 and haemostasis: a position paper from Italian Society on Thrombosis and Haemostasis (SISET). *Blood Transfus* 2020; 18(3): 167–169
6. Oxley T.J, Mocco J, Majidi S. Large-vessel stroke as a presenting feature of Covid-19 in the young. *N Engl J Med.* 2020; 20(3): 382.
7. Seah I, Agrawal R. Can the coronavirus disease 2019 (COVID-19) affect the eyes? A review of coronaviruses and ocular implications in humans and animals. *Ocul Immunol Inflamm* 2020; 28(3): 391–395.
8. Insausti-García A, Reche-Sainz JA, Ruiz-Arranz C, López Vázquez Á, Ferro-Osuna M. Papillophlebitis in a COVID-19 patient: Inflammation and hypercoagulable state. *Eur J Ophthalmol.* 2020 Jul 30:1120672120947591. doi: 10.1177/1120672120947591. Epub ahead of print. PMID: 32735134; PMCID: PMC7399568.



## Case report

# Absorbable gelatin sponge plug for posterior scleral perforation secondary to impacted metallic intraocular foreignbody (IOFB)

Dr Rajesh Ramanjulu<sup>1</sup>

<sup>1</sup> Sanakar Eye Hospital, Bengaluru, Karnataka

### Abstract

Twenty six year old male patient with posterior ocular perforation secondary to impacted intraocular foreign body underwent vitrectomy with IOFB removal. Sealing of posterior scleral perforation at the site of IOFB was attempted with PFCL, high density viscoelastic and fibrin without much success. A piece of absorbable gelatin sponge was used as a plug to seal the posterior scleral perforation. The intraoperative hypotony and leak was successfully managed with this unique technique which has not been reported in literature earlier.

**Key words-** Intraocular foreign body, Posterior scleral perforation, Gelatin sponge

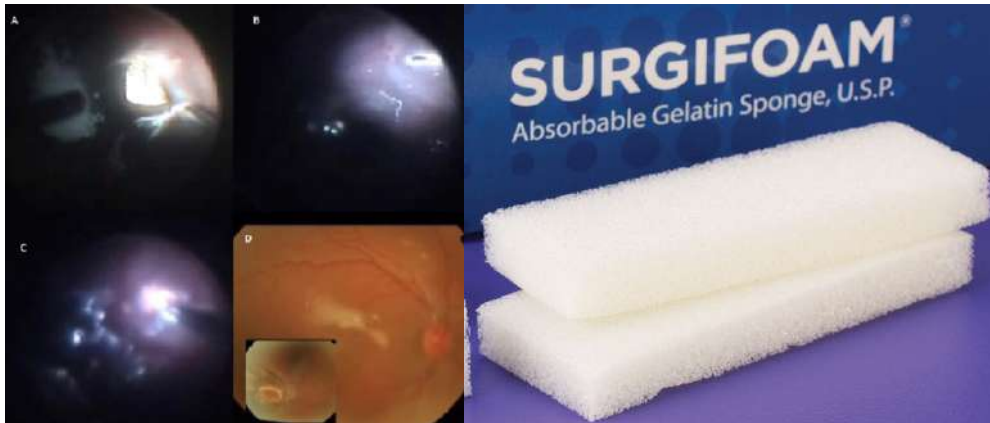### Introduction

Intraocular foreign bodies (IOFBs) are a leading cause of visual morbidity and blindness, especially in the working population. [1] IOFB with posterior scleral perforation poses a challenging situation due to hypotony induced by scleral dehiscence and surgical steps like fluid air injection can be hazardous at this stage of vitrectomy unless the surgeon seals the posterior scleral perforation. One can use autologous sclera, amniotic membrane, fibrin and high density perfluorocarbon or visco elastic in this scenario to seal posterior scleral perforation but with limited success.

### Case Description

Twenty six year old male patient with history decreased vision following penetrating injury to the right eye. On examination he had best corrected visual acuity of perception of light in the right eye and 6/6 in the left eye. On examination of the right eye he had conjunctival congestion, subconjunctival hemorrhage and a paralimbal scleral tear in the inferotemporal quadrant. Anterior chamber showed 1+ cell with no evidence of hypopyon or any other sign of intraocular infection. Lens was clear. Fundus examination of the right eye was hazy due to dispersed vitreous hemorrhage. Left eye examination was normal. In the view of suspected intraocular foreign body patient underwent CT scan of the orbit, which showed metallic intraocular foreign body in the right eye piercing the posterior ocular coat. Patient underwent pars plana vitrectomy for intraocular foreign body removal after suturing of scleral tear with 8-0 vicryl suture. During vitrectomy after clearing of vitreous hemorrhage, triamcinolone acetonide was used for complete PVD induction. During vitrectomy it was found that intraocular foreign body was found to be impacted in the ocular coat (Figure 1A), after teasing it out from the ocular coat with careful dissection IOFB was removed through parsplana after enlarging the sclerotomy. Intra operatively after removal of posteriorly impacted intraocular foreign body gross hypotony was noted resulting in retinochoroidal folds. Full thickness scleral perforation/dehiscence (Figure 1B) caused severe hypotony. In spite of using perfluorocarbon and high density viscoelastic hypotony induced by posterior ocular perforation persisted. At this stage surgical completion was difficult due to gross hypotony. So to overcome hypotony and to tackle posterior perforation, tagging of the lateral and inferior recti was done after dissecting conjunctiva, a piece of absorbable gelatin sponge was used to tamponade the posterior scleral perforation by inserting it posteriorly through the subconjunctival space (external approach), but perforation could not be sealed and there was a persistent hypotony. Hence we decided to introduce the same small piece of absorbable gelatin sponge transvitreally and plugged the piece into posterior scleral perforation (Figure 1C). After plugging the scleral perforation, globe volume returned to normal with recession of retinochoroidal folds. Fluid air exchange was done and endolaser was applied around the site of posterior scleral perforation which was plugged with gelatin sponge. Silicone oil was injected as tamponade. Post operatively at 1 month patient had best corrected visual acuity of 6/12 in the right eye with well attached retina and posterior site of foreign body impact was secure (Figure D).

Figure 1- A- Impacted metallic foreign body within ocular coat ,B- Full thickness scleral dehiscence after Foreign body removal ,C- piece of gelatin sponge plugged into posterior scleral dehiscence /perforation, D- post operative fundus photo showing well attached retina under silicone oil ,site of gelatin sponge was secure. Figure 2- Absorbable gelatin sponge (SURGIFOAM)



### Discussion

Recent advances in vitreoretinal surgical techniques, has suggested to improve the outcome of PPV in the management of posterior segment IOFBs.<sup>[2,3]</sup> But still there is a high rate of complications related to removal of impacted IOFBs.<sup>[4]</sup> Posterior scleral perforation due to IOFB creates a challenging intraoperative scenario due to hypotony with gross chorioretinal folds, choroidal bleed and retinal incarceration. Posterior scleral perforations are not amenable for suturing. Various autologous and heterologous tissues as well as fibrin glue have been tried to seal the posterior scleral perforation with limited success. In literature there is no definitive treatment for the management of posterior scleral perforation. We successfully managed posterior scleral perforation secondary to impacted IOFB using absorbable gelatin sponge.

### Conclusion

Absorbable gelatin sponge (Figure 2) is cost effective and biocompatible for intraocular use. So in ocular trauma with posterior scleral perforation or dehiscence, one should consider the option of using absorbable gelatin sponge piece as a plug to prevent leak and hypotony.

**Financial Disclosure- None**

**Conflicts of Interest- None**

---

### References

1. S. D. Nicoara, I. Irimescu, T. Calinici, and C. Cristian, "Intraocular foreign bodies extracted by pars plana vitrectomy: clinical characteristics, management, outcomes and prognostic factors," *BMC Ophthalmology* 2015;15:151
2. Jonas JB, Knorr HL, Budde WM. Prognostic factors in ocular injuries caused by intraocular or retrobulbar foreign bodies. *Ophthalmology* 2000; 107:823-8.
3. Wani VB, Al-ajmi M, Thalib L. Vitrectomy for posterior segment intraocular foreign bodies, visual results and prognostic factors. *Retina* 2003; 23:654-60.
4. Ahmadi H, Sajjadi H, Azarmina M, Soheilian M, Baharivand N. Surgical management of intraretinal foreign bodies. *Retina*. 1994;14(5):397-403

## Case report

# A Fungating mass in Anterior chamber secondary to adenocarcinoma of Lung

Dr Suresha AR<sup>1</sup>, Dr Fayiza Musthafa<sup>2</sup>

<sup>1,2</sup>Department Ophthalmology JJM Medical College, Davanagere

### Abstract

To report an unusual case of adenocarcinoma lung with choroidal metastasis presenting as fungating mass in the anterior chamber. The incidence of ocular metastases from lung cancer is reported to be 0.2–6.7% of which choroidal metastasis is the most frequent type. A 61-year-old man, k/c/o lung carcinoma on chemotherapy for 1 year with past medical history of HTN and asthma, presented with complaints of painful red eye. On presentation, he was on treatment for neovascular glaucoma. When examined, a fungating golden yellow-brown vascularized mass projecting through the pupillary area was noted. The swelling rapidly progressed in size over 2 weeks and involved whole of the anterior chamber. Visual acuity was PL+, PR inaccurate. IOP (OS)-32 mmHg. Imaging modalities were suggestive of metastatic growth. Due to intractable severe pain, the eye had to be enucleated and histopathology features were suggestive of adenocarcinoma, consistent with the lung biopsy finding. He was continued on chemotherapy and palliative radiotherapy. Choroidal metastatic mass with neovascularization can masquerade as neovascular glaucoma and delay the diagnosis. To the best of our knowledge, this is the first case being reported with fungating growth as the presentation of choroidal metastasis.

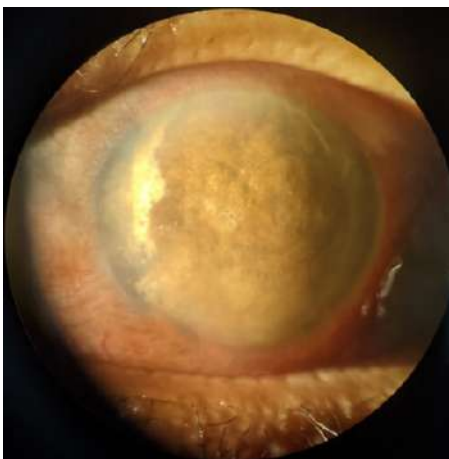**Key-words:** choroidal metastasis, fungating growth, lung adenocarcinoma, neovascular glaucoma

### Introduction

The incidence of ocular metastasis from lung cancer is reported to be 2–7%. Metastatic choroidal tumors are the most common intraocular malignancies<sup>1,2</sup>. Perls reported the first case of choroidal metastasis in 1872<sup>3</sup>. Choroidal metastasis is the most frequent type, whereas metastases in iris, ciliary body, retina, vitreous and optic disc are comparatively rare<sup>4-6</sup>. Because of nonspecific symptoms and limited number of studies in literature, diagnosis and management of ocular metastasis in lung carcinoma can pose enormous challenge for ophthalmologists. To the best of our knowledge, this is the first case being reported with fungating growth as the presentation of choroidal metastasis.

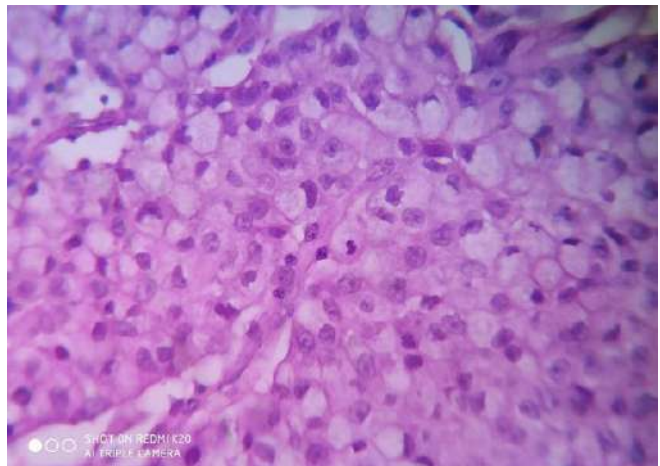
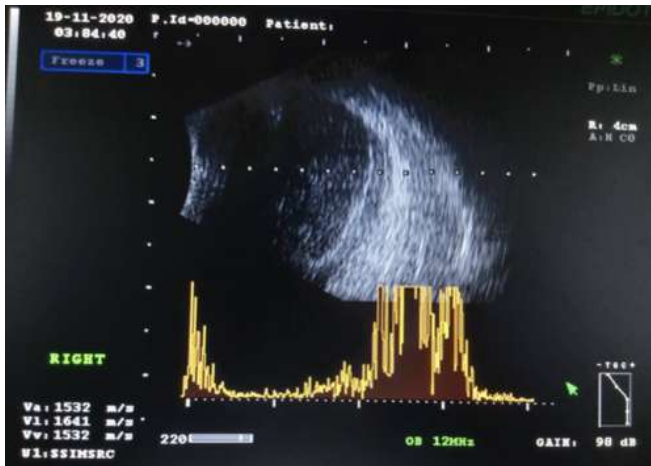
### Case History:

A 61-year-old man, with 40 pack history of smoking, known case of lung carcinoma on chemotherapy for 1 year with past medical history of hypertension and bronchial asthma, presented with complaints of diminished vision and painful red eye in left eye. On presentation, left eye was being treated as neovascular glaucoma. On examination: Visual acuity. RE: BCVA-6/9. LE-PL positive, PR inaccurate. Intraocular pressure (IOP) measured by a Goldmann Applanation Tonometer was 12mmHg (OD) and 34 mmHg (OS). Slit lamp examination Conjunctiva-Circumciliary congestion and sentinel blood vessel temporally. Cornea-Diffuse endothelial dusting, Anterior Chamber-fungating golden yellow-brown mass projecting through the pupillary area encroaching upto the corneal endothelium. Vascularization noted over the mass inferiorly. Rest of structural details and funduscopy could not be done due to pupillary occlusion by the fungating mass. After 2 weeks, the mass was observed to have rapidly enlarged to occupy the whole of anterior chamber, sparing only a peripheral area nasally. Left eye examination showed normal findings.



### Imaging modalities:

B Scan- Diffuse opacities of medium reflectivity in vitreous suggestive of growth arising from choroid. Tumour seedings causing retinal detachment were noted. CE MRI brain with orbit: Iso-hyperintense irregular thickening with enhancement along the posterolateral wall of globe suggestive of metastatic growth, with no evidence of optic nerve involvement. Management-Due to



intractable severe pain, the eye had to be enucleated. Enucleated specimen showed irregular thickening of eyeball with scleral extension. A thin white membrane arising from the choroid extending to the posterior aspect of the lens was noted. Histopathology examination showed tumor cells with vacuolated cytoplasm and signet ring like nucleus consistent with features of adenocarcinoma. He was continued on chemotherapy (paclitaxel and carboplatin) and palliative radiotherapy but was lost to follow up during the COVID-19 pandemic. He succumbed to death after 6 months of his initial presentation with ocular metastasis.

### Discussion

The major categories of lung cancer include small cell and non-small cell types. Small cell type includes oat cell carcinoma, intermediate cell carcinoma, and mixed small cell carcinoma. Non-small cell type includes adenocarcinoma, squamous cell carcinoma, and large cell carcinoma. Small cell type exhibits more rapid progression, earlier metastasis, and a distinct profile of treatment response compared with the non-small cell type<sup>9</sup>. Common sites of lung cancer metastasis are brain, pleural cavity, bone, liver, adrenal glands, contralateral lung, skin and eye. The incidence of ocular metastasis from lung cancer is reported to be 2–7%. On the basis of an analysis of 520 eyes with uveal metastasis, Shields et al found the most common primary site to be breast cancer (68%) in women and lung cancer (40%) in men.<sup>2</sup>

Presentation of ocular metastasis: Choroid - golden yellow to yellowish-white round/oval lesion with plateau configuration with overlying orange-brown pigment (lipofuscin pigment)<sup>10</sup>. Optic disc shows swollen disk without a distinct mass or as a dis cohesive cellular infiltration, Iris can have solid and amelanotic mass, Ciliary body -diffuse/ multinodular mass, associated with extensive retinal detachment. Others- infiltrative lesions of the neural retina, dispersed cells in the vitreous. The choroid is supplied by the larger posterior ciliary artery and there is extensive anastomotic communication between the choroidal vessels, hence it is susceptible to metastases. The choroidal metastases are generally located on the posterior part of the equator. On B scan, it is usually seen as an echogenic sub retinal mass with diffuse, ill-defined borders. But in our case, retinal detachment by infiltrating tumour deposits was observed on B scan, which was further confirmed on histopathological examination. The management of choroidal metastasis varies depending on the patients' presentation. If patient has advanced systemic metastasis and the affected eye is relatively asymptomatic, no treatment is necessary. They can be benefit from concurrent chemotherapy in terms of local control. Local treatment of the eye is palliative, and the purpose of treatment is to maintain visual function and improve quality of life .In recalcitrant cases, external beam irradiation is considered. Other treatment modalities include plaque radiotherapy, surgical excision or enucleation in cases of poor vision and eye pain. Intravitreal bevacizumab has been shown effective in patients presenting with neovascular glaucoma<sup>11</sup>. Prompt treatment with chemotherapy with or without radiotherapy helps achieve better prognosis. However the systemic prognosis in choroidal metastasis is poor with poor median survival time of 6- 13 months<sup>8</sup>. Our patient was continued on chemotherapy and radiotherapy but was lost to follow up during the COVID-19 pandemic. He succumbed to death after 6 months of his initial presentation with ocular metastasis.

**Conclusion:** Choroidal metastasis presenting as fungating mass through the pupillary area is a rare manifestation of metastatic lung cancer. Neovascularization of the lesion can masquerade as neovascular glaucoma and delay the diagnosis. A painful red eye with atypical mass in anterior chamber should be considered as a possible manifestation of an underlying malignancy. To the best of our knowledge, this is the first case being reported with fungating growth as the presentation of choroidal metastasis. Further improvement in the understanding of lung cancer, eye metastasis, improving the diagnostic rate, and developing new targeted treatment strategies and systemic anti-cancer treatment strategies are needed.

**Financial Disclosure- None**

**Conflicts of Interest- None**

## References

1. A.P. Ferry, R.L. Font, Carcinoma metastatic to the eye and orbit. I. A clinicopathologic study of 227 cases, *Arch. Ophthalmol.* 92 (4) (1974) 276–286.
2. C.L. Shields, J.A. Shields, N.E. Gross, G.P. Schwartz, S.E. Lally, Survey of 520 eyes with uveal metastases, *Ophthalmology* 104 (8) (1997) 1265–1276
3. Perls M. Contributions to pathology of tumors. *Virchows Arch Pathol Anat.* 1872;56:437
4. S. Shamim, S. Vidya, S. Kabir, B. Ghosh, Choroidal metastases as the initial presentation of lung cancer: a rare scenario, *Niger. J. Clin. Pract.* 20 (7) (2017) 905–909.
5. T. Simsek, Y. Ozdamar, N. Berker, Choroidal mass as an initial presentation of lung cancer, *Med. Oncol.* 25 (4) (2008) 400–402.
6. Niu FY, Zhou Q, Yang JJ, Zhong WZ, Chen ZH, Deng W, He YY, Chen HJ, Zeng Z, Ke EE, et al. Distribution and prognosis of uncommon metastases from non-small cell lung cancer. *BMC Cancer* 2016; 16: 149
8. Shah SU, Mashayekhi A, Shields CL, et al. Uveal metastasis from lung cancer: clinical features, treatment, and outcome in 194 patients. *Ophthalmology.* 2014;121(1):352-357.
9. Hoffman PC, Mauer AM, Vokes EE. Lung cancer. *Lancet* 2000;355:479–85.
10. Kreusel KM, Bechrakis NE, Wiegel T, et al. Incidence and clinical characteristics of symptomatic choroidal metastasis from lung cancer. *Acta Ophthalmol* 2008;86:515–9.
11. de la Barquera Cordero AS, Hidalgo RA. Intravitreal bevacizumab for choroidal metastasis of lung carcinoma; a case report. *J Ophthalmic Vis Res.* 2010;5(4):265-268.

## Case report

# Loop Myopexy in the management of Myopic Strabismus Fixus

Dr Sunayana Bhat,<sup>1</sup> Dr Shachi Shetty<sup>2</sup>

<sup>1,2</sup> Department of Ophthalmology, Father Muller Medical college hospital, Mangalore, Karnataka

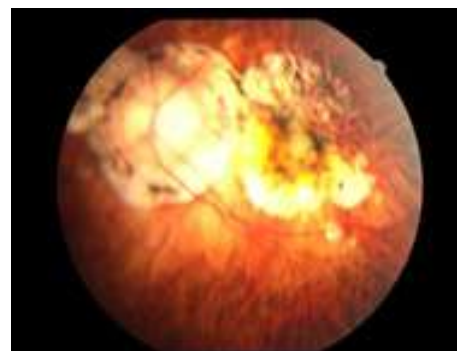
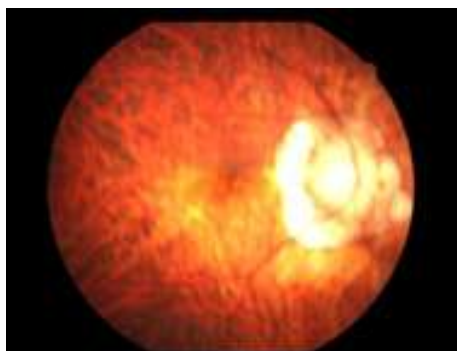
### Introduction

Myopic strabismus fixus is an ocular motor abnormality in high myopic eyes where both eyes are anchored in an extreme adduction with varying degrees of hypotropia. The pathogenesis, confirmed by orbital imaging, is due to the muscle pulleys of superior and lateral recti being displaced outwards as a result of posterior enlargement of the globe.

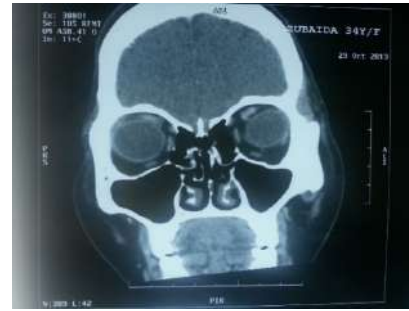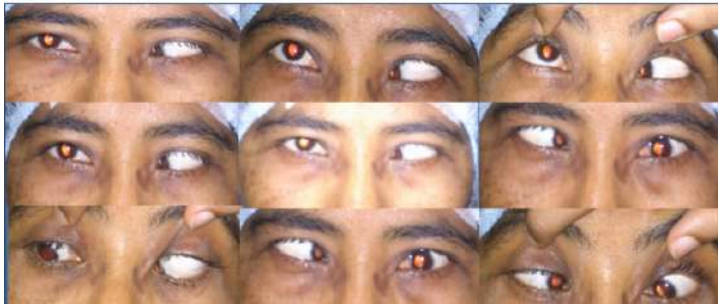### Case History

35 year old female patient with acute onset of deviation, progressively increasing, noted in both eyes three months following delivery of her third child, associated with h/o diplopia. Known case of high myopia

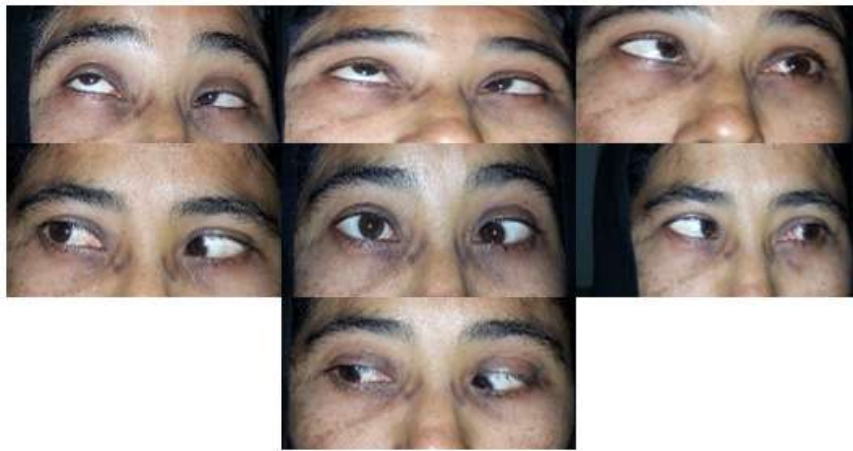
	OD	OS
BCVA	6/24	CF 1m
Refraction	-18.0DS/-3.0 DC 180 deg	-20.0 DS/-3.0 DC 180 deg
Conjunctiva	conjunctival growth on medial side	conjunctival growth on medial side OS> OD
Anterior segment ,lid and adnexa	Within normal limits	Within normal limits
Pupil	3mm , round reactive to light	3mm , round reactive to light
Fundus picture	High myopic picture Peri papillary Chorioretinal atrophy	Peri papillary Chorioretinal atrophy CNVM – scarred involving macula
IOP	18 mm of hg	18 mm of hg
A SCAN	26.3 mm	27.8 mm



Orthoptic evaluation revealed OS - Large esotropia > 60 PD , EOM : limited abduction in BE-LE>RE, limited elevation in both eyes.

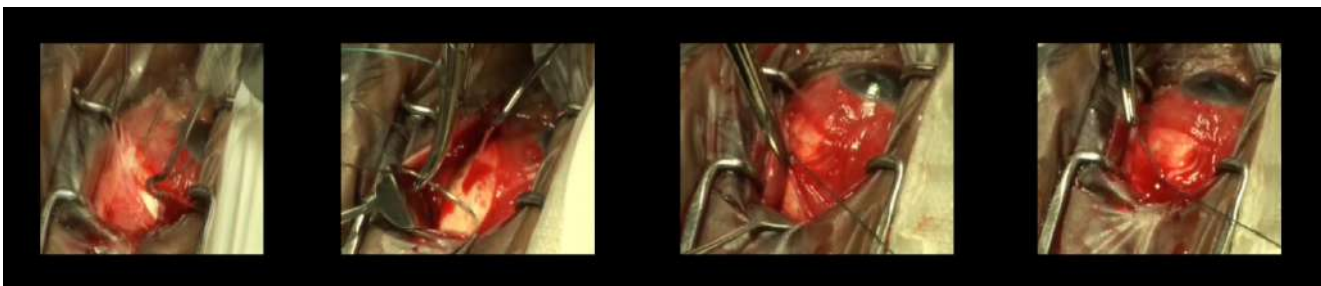


FDT done under general anaesthesia -Severe restriction on medial rectus in LE and Moderate restriction of medial rectus of RE. CT scan : orbits-coronal cuts 2 mm -Medial displacement of superior rectus and inferolateral displacement of the lateral rectus muscle with an enlarged globe herniating superotemporally through the muscle cone. Both eyes medial rectus 8 mm recession with conjunctival recession was done. Improved ocular movements were noted in both eyes, Residual esotropia of 35 PD .

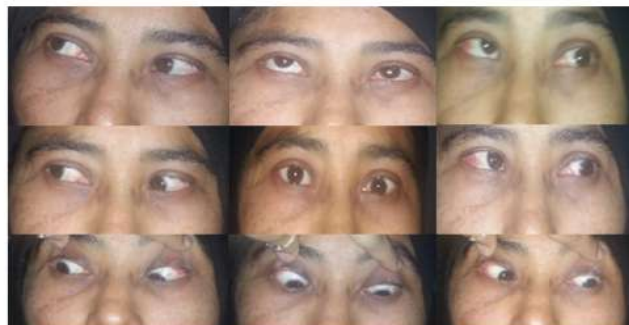

At 3 months follow up residual esotropia, both eyes loop myopexy (approximating the muscle bellies of superior rectus and lateral rectus to close the hernial opening) was planned

Surgical procedure-Under general anaesthesia,A fornix based conjunctival incision was placed in the supero- temporal quadrant approximately 10–12 mm from the limbus. The LR and SR were hooked and isolated using muscle hooks and tenon capsule reflected. The paths of both LR and SR were examined intraoperatively. The bellies of SR and LR were brought together and fastened with ETHIBOND suture material. The conjunctiva was closed with interrupted sutures using an 8–0 absorbable suture.



Post op 3 weeks-Residual esotropia 5-10 PD, Improved abduction and elevation in both eyes



Surgical treatment of myopic strabismus fixus is challenging. Treatment options include conventional recess resect procedures and disinsertion of medial rectus muscle. Loop myopexy works by restoring the normal Extraocular muscle anatomy in the enlarged high myopic globe with good cosmetic results. In conclusion, Suture loop myopexy with or without scleral fixation (Foster's modification) with or without MR recession is the procedure of choice for myopic strabismus fixus and its effectiveness is well established.

**Financial Disclosure- None**

**Conflicts of Interest- None**



## References

1. Yamaguchi M, Yokoyama T, Shiraki K. Surgical procedure for correcting globe dislocation in highly myopic strabismus. *Am J Ophthalmol* 2010;149:341–6.
2. Krzizok TH, Schroeder BU. Measurement of recti eye muscle paths by magnetic resonance imaging in highly myopic and normal subjects. *Invest Ophthalmol Vis Sci*. 1999;40:2554-2560.
3. Yokoyama T, Tabuchi H, Ataka S, et al. The mechanism of development in progressive esotropia with high myopia. In: de Faber J-T, ed. *Transactions: 26th Meeting, European Strabismological Association, Barcelona, Spain, 2000*. Lisse (Netherlands): Swets & Zeitlinger, 2001:218–22
4. Krzizok TH, Kaufmann H, Traupe H. New approach in strabismus surgery in high myopia. *Br J Ophthalmol* 1997;81:625–30.





## Case report

# Seborrheic Keratosis masquerading as basal cell carcinoma

DR Chinmayee J T,<sup>1</sup> DR Anjali Hiroli<sup>1</sup>

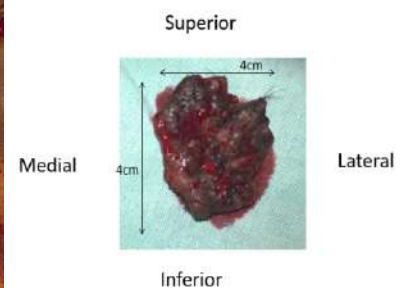
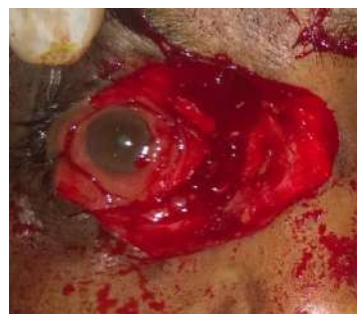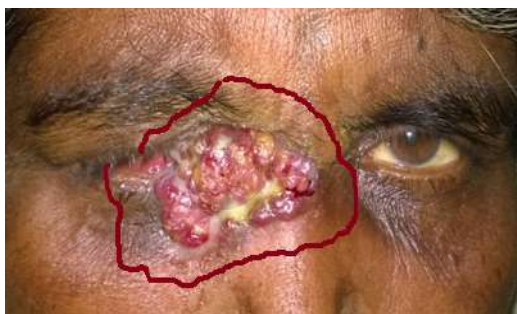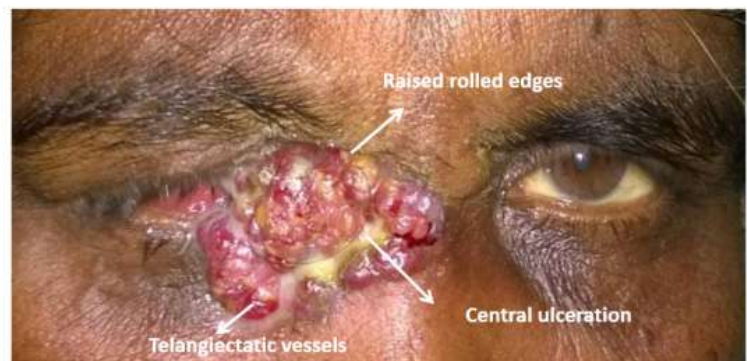
<sup>1</sup>Minto ophthalmic Hospital, Bengaluru, Karnataka

Seborrheic keratosis (SK) is one of the most common benign epidermal skin tumors. On the other hand, basal cell carcinoma (BCC) is the most common malignancy of the skin. Clinically irritated type of seborrheic keratosis closely resembles noduloulcerative type of basal cell carcinoma.

Seborrheic keratosis types	Basal cell carcinoma types
<ul style="list-style-type: none"> <li>Irritated type .</li> <li>Inverted follicular type</li> <li>Adenoid or Reticulated type</li> <li>Acanthotic type</li> <li>Hyperkeratotic type</li> <li>Basaloid cell type</li> <li>Clonal type</li> </ul>	<ul style="list-style-type: none"> <li>Nodular</li> <li>Noduloulcerative</li> <li>Sclerosing (morphoiec)</li> <li>Cystic ,adenoid, pigmented, multiple superficial</li> </ul>

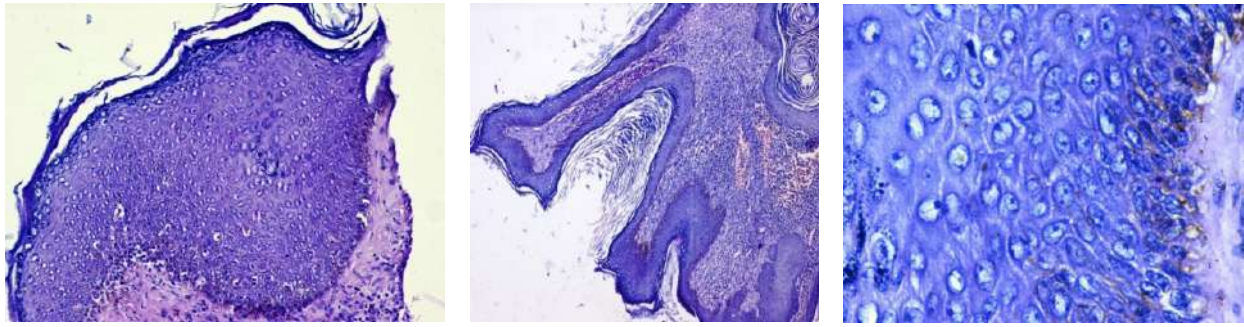
### Case history

60 year old female presented with progressive swelling near the medial side of the right eye since 1 year which progressed to present size. It was associated pain, watering, discharge and redness of the right eye. No complaints of diminution of vision or trauma. She had shown elsewhere, where it was managed conservatively. There was no relief of symptoms after treatment. General physical examination was normal. No lymphadenopathy, pallor. Ocular examination was within normal limit as per her age.



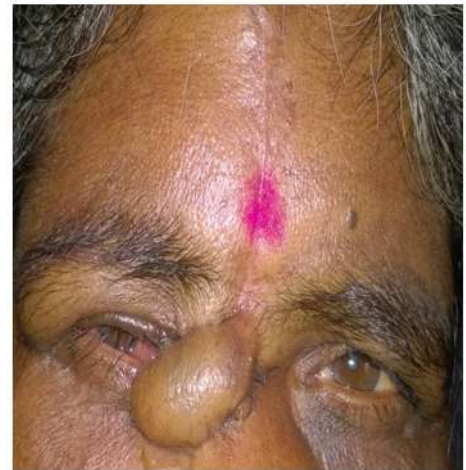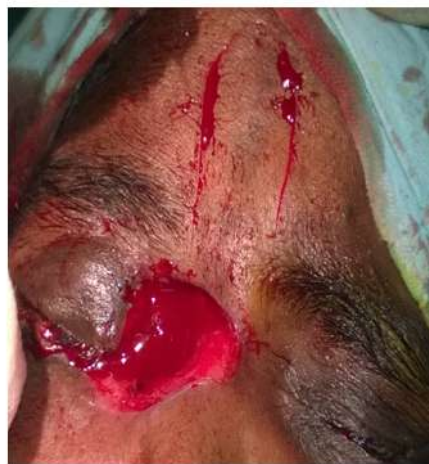Solitary noduloulcerative lesion in the medial side of the right eye involving 1/3<sup>rd</sup> of upper lid and 2/3<sup>rd</sup> of lower lid with central ulceration, and telangiectatic vessels over it. Surrounding tissue was indurated. Lesion was fixed to skin and underlying structures.

Clinical features were suggestive of either squamous cell or basal cell carcinoma. Routine blood investigations were within normal limits. Lacrimal syringing from upper punctum showed regurgitation of mucoid fluid from lower punctum. Patient was planned for Wide excision with margin clearance and Reconstruction



Histopathology showed-Skin acanthosis with two type of cells, squamous cells and basaloid cells, invagination of keratin material forming pseudohorn cyst, Squamous cells with prominent intercellular bridges indicative of edema

Age of the patient, mass involving the medial canthus and clinical appearance of the lesion favoured the diagnosis of basal cell carcinoma. Irritated type of seborrheic keratosis can masquerade as noduloulcerative type of basal cell carcinoma. There are reported cases in literature where a malignancy was found in the benign lesion like seborrheic keratosis.<sup>1</sup>Here is a case where a benign lesion was found in a malignant appearing lesion.



In conclusion-We present a rare case of seborrheic keratosis which masquerade as a noduloulcerative basal cell carcinoma. If seborrheic keratosis becomes inflamed may be mistaken for basal cell carcinoma/ squamous cell carcinoma.Incisional biopsy can be done in large lesions to limit the amount of excision.Aggressive benign lesion can masquerade as malignant lesions.However, rapid growth or transformation of seborrheic keratosis may be a sign of the appearance of malignancy. In these cases, adequate and complete excision of the lesion is recommended.<sup>3</sup>

**Fiancial Disclosure- None**

**Conflicts of Interest- None**

## References

1. Mikhail GR, Mehregan AH.J.Am Acad Dermat Basal cell carcinoma in seborrheic keratosis. 1982 Apr;6(4 Pt 1):500-6.
2. Yap W P, TonP H, Ong BH An Acad Med Singapore.Malignancy arising in seborrheic keratosis: a report of two cases. 1997 Mar;26(2):235-7.
3. L.carnero,R.soloeta, N.gonzolia pera. Actas Dermosifiliogr.Squamous cell carcinoma on seborrheic keratosis 2009;100:621

## Case report

# Corneal bee sting injury

Dr Kaiyoor Surya Divyalakshmi<sup>1</sup>, Dr Aditi Vidha<sup>1</sup>

<sup>1</sup>Department of Ophthalmology, Yenepoya Medical College, Mangalore, Karnataka  
Correspondence - Dr Divyalakshmi K S, Associate Professor, Dept of Ophthalmology, Yenepoya Medical College, Mangalore – 575018, divyalakshmikns2002@yahoo.com

### Abstract

Retained Corneal bee stinger is a rare condition that can lead to potentially devastating complications in the eye if not intervened early. Due to the rarity of the condition, there are no structured guidelines in the management of the same. Here we are reporting a case of a young male who presented with white cornea due to a retained bee stinger.

**Key words:** retained bee stinger, surgical technique, specular microscopy

### Introduction

Corneal bee sting is an uncommon environmental eye injury that can result in various ocular complications with an etiology of penetrating, immunologic, and toxic effects of the stinger and its injected venom.<sup>1-5</sup> Due to the rarity of this condition, there is no clear guideline for the management of affected individuals. We are reporting a case of white cornea due to retained bee-sting and its successful removal using a modified technique with good visual outcome.

### Case Report

A 20 year old young male presented with history of pain, redness and diminution of vision in right eye following an alleged bee-sting injury of 1 day duration. He had earlier consulted an ophthalmologist immediately after trauma and the bee sting removal was attempted. He was referred to our centre the next day for further management. He presented to us 12 hours after the incident. His best corrected visual acuity (BCVA) was counting fingers close to face. Ocular examination showed lid edema with matting of eye lashes, ciliary congestion. Cornea was hazy and appeared white (Fig1a). Severe stromal edema was seen with Descemet membrane folds. A retained bee-sting was seen deep in stroma in superior cornea with surrounding 1.5mm infiltration paracentrally at 3o'clock hours (Fig 1b). Rest of the details was not clearly made out. Digitally intraocular pressure was normal. Sting was successfully removed within 3 hours of presentation (Fig 2a&2b). As the sting was in deep stroma, a modified bimanual technique with two 26 G needles was used. A linear gutter was made over the sting. First needle was used to gently retract the wall of the gutter laterally and with the help of second needle, the sting was levitated from below upwards. Once it was in anterior stroma it was gently removed using microrrhesis forceps.

Postoperatively, he was started on Prednisolone eye drops every 4<sup>th</sup> hourly with Moxifloxacin eye drops hourly for a week with Atropine eye drops and oral Prednisolone at a dose of 1mg/kg body weight. He was followed up every week with weekly tapering of topical and oral steroids. (Fig 3a)

At 2 months follow up, BCVA improved to 6/12, with near complete resolution of corneal edema and infiltration. A macular grade corneal opacity was noted with pigment deposits on the back of cornea in the inferior quadrant with an anterior capsular cataract of lens. (Fig 3b) Iris showed diffuse atrophic patches and rigid pupil was noted. Dilated fundoscopy showed normal retinal study. At 6 months follow up, BCVA was maintained at 6/12 with stable macular corneal opacity and no further progression of anterior capsular cataract. Pigment deposits were persisting on back of cornea. Specular microscopy of the endothelium of affected eye showed cell density of 1631cells/mm<sup>3</sup> as compared to 3065 cells/mm<sup>3</sup> in normal eye with features suggestive of polymegathism.

### Discussion

Corneal bee sting is a rare condition that can lead to potentially devastating complications including keratitis, corneal opacity, uveitis, iris atrophy, glaucoma, cataract, lens subluxation, bullous keratopathy,

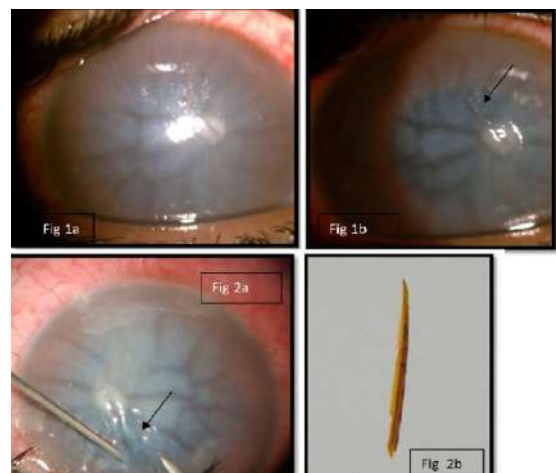
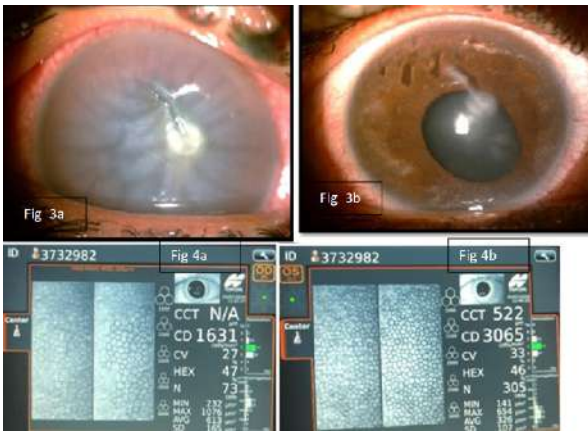


Fig1a: Severe corneal haze. Fig 1b: Retained bee stinger; Fig2a: Removal of stinger using two 26G needles Fig 2b: Bee stinger



**Fig 3a: Post op day 1 Fig 3b: Post op 2 months; Fig 4a & b: Specular microscopy of RE & LE**

need surgical intervention considering the risk of leaving broken fragments within the cornea<sup>4</sup>. The stinger can be removed by extracting its visible end manually from the cornea<sup>8</sup> or with the help of needle to prevent the complication of retained stinger. Unfortunately, there are no prescribed guidelines for the management of corneal sting injury.

In this case report, we have described successful removal of a retained bee stinger located in deep cornea by a modified bimanual technique with two 26G needles in a young patient who presented late to us with white cornea of more than 12 hours duration after injury. He further showed good response to oral and topical steroids with antibiotics with near complete recovery of vision and corneal haze.

Corneal bee sting can result in various ocular complications, including corneal epithelial defect, corneal stromal infiltration, endothelial cell loss, glaucoma, cataract, anterior uveitis, optic neuritis, and even permanent vision loss.<sup>[1-4]</sup> In our case corneal endothelial damage with compromised endothelial count with extensive iris atrophy and anterior subcapsular cataract was noted.

### Conclusion

Cases of corneal bee sting injuries reported late have been found to have poor visual outcome. In spite of the delayed presentation, we could successfully remove the bee sting completely using a modified bimanual technique. A multimodal therapy which included surgical removal followed by aggressive management with steroids resulted in good clinical outcome which was maintained at 6 months. However endothelial cell count on specular microscopy being low is of concern in view of late onset corneal decompensation. Thus these patients need long term follow up.

**Financial Disclosure- None**

**Conflicts of Interest- None**

### References

1. LIN PH, WANG NK, HWANG YS, ET AL. BEE STING OF THE CORNEA AND CONJUNCTIVA: MANAGEMENT AND OUTCOMES. CORNEA. 2011; 30(4): 392–394.
2. GÜRLÜ VP, ERDA N. CORNEAL BEE STING-INDUCED ENDOTHELIAL CHANGES. CORNEA. 2006; 25(8):981–983.
3. ARCIERI ES, FRANÇA ET, DE OLIVERIA HB, ET AL. OCULAR LESIONS ARISING AFTER STINGS BY HYMENOPTERAN INSECTS. CORNEA. 2002; 21(3):328–330.
4. TEOH SC, LEE JJ, FAM HB. CORNEAL HONEYBEE STING. CAN J OPHTHALMOL. 2005; 40(4):469–471.
5. CHINWATTANAKUL S, PRABHASAWAT P, KONGSAP P. CORNEAL INJURY BY BEE STING WITH RETAINED STINGER: A CASE REPORT J MED ASSOC THAI. 2006; 89(10): 1766–1769.
6. KIM J. M., KANG S. J., KIM M. K., WEE W. R., LEE J. H. CORNEAL WASP STING ACCOMPANIED BY OPTIC NEUROPATHY AND RETINOPATHY. JAPANESE JOURNAL OF OPHTHALMOLOGY. 2011; 55(2):165–167.
7. RAZMJOO H., ABTAHI M.-A., ROOMIZADEH P., MOHAMMADI Z., ABTAHI S.-H. MANAGEMENT OF CORNEAL BEE STING. CLINICAL OPHTHALMOLOGY. 2011; 5(1):1697–1700
8. KIM JH, KIM M, LEE SJ, HAN SB, HYON JY. CORNEAL BEE STING CONTROLLED WITH EARLY SURGICAL INTERVENTION AND SYSTEMIC HIGH-DOSE STEROID THERAPY. CASE REP OPHTHALMOL MED. 2014; 2014:140626.
9. CHUAH G, LAW E, CHAN WK, ANG CL. CASE REPORTS AND MINI REVIEW OF BEE STINGS OF THE CORNEA. SINGAPORE MED J. 1996; 37(4):389–391
10. GILBOA M, GDAL-ON M, ZONIS S. BEE AND WASP STINGS OF THE EYE. RETAINED INTRALENTICULAR WASP STING: A CASE REPORT. BRJ OPHTHALMOL. 1977; 61(10): 662–664.

## *Surgical Pearls in handling cataract surgery complications*

# How to manage post cataract surgery temporal reflections and shadows

**Dr Prakash VS<sup>1</sup>**

<sup>1</sup>Comtrust charitable Trust Eye Hospital, Kozhikode, Kerala

Dysphotopiasias, both negative and positive, although diverse in cause and cure, represent undesired optical phenomena following cataract surgery. They interfere significantly with quality of vision and the perceived success of surgery. In reality, dysphotopsia represents a failure of both the manufacturing sector and the clinician in recognizing and correcting the matter. Presently, dysphotopsia accounts for the greatest incidence of patient dissatisfaction after otherwise uncomplicated cataract surgery, and its importance has been overlooked greatly. Given that negative dysphotopsia (ND) and positive dysphotopsia (PD) differ in etiology and management, they will be considered separately. However, both conditions may exist simultaneously.

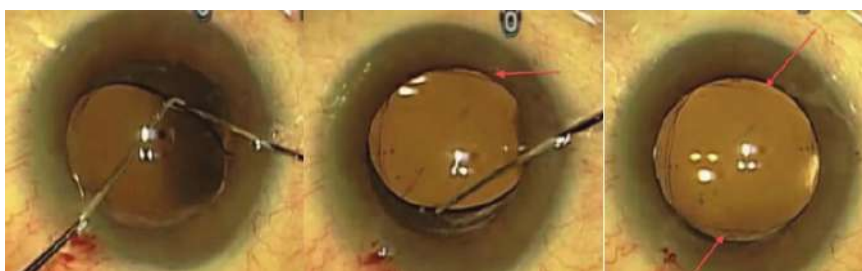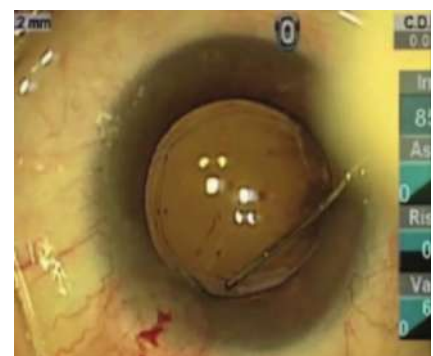
### **Negative Dysphotopsia**

Negative dysphotopsia was originally described by Davison as complaints of a dark temporal crescent, similar to horse blinders.<sup>1</sup> Clinical experience dictates that there are no beneficial medical therapies for the patient with symptomatic ND. However, surgical methods have been devised that have proved to be useful in reducing ND visual symptoms. Although ND rarely induces visual disability sufficient to require an operative approach, some patients are very disturbed by it and can be very vocal in their complaints. This may be particularly true when premium intraocular lenses (IOLs) have been implanted. Perhaps the most frustrating aspect of this problem for the surgeon and patient alike is that ND occurs only in cases of what we consider to be perfect surgery. That is, ND has been reported only in cases where the posterior chamber IOL (PC IOL) is well-centered within the confines of the capsular bag. To our understanding, ND has never been reported with sulcus-placed PC IOLs or anterior chamber IOLs. In our investigation, we found that ND occurs with any type of in-the-bag PC IOLs, with overlap of the anterior capsulorrhexis onto the anterior surface of the PC IOL.<sup>2</sup> Fortunately, symptoms are transient in most cases.

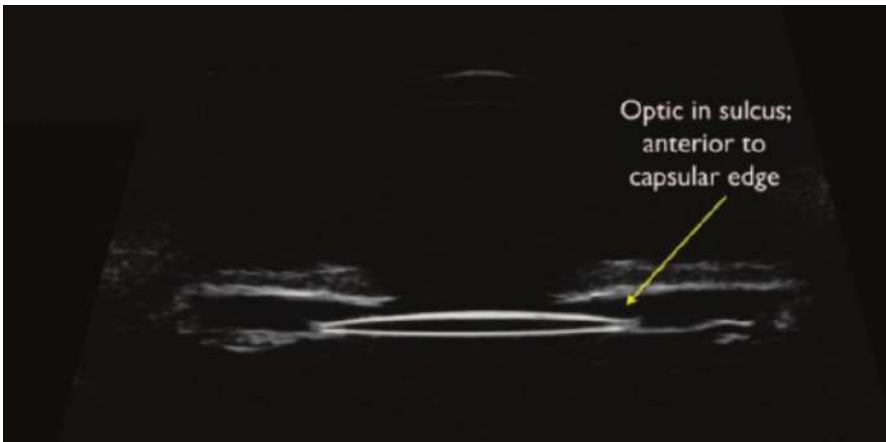
### **Reverse Optic Capture**

Given the above, and in keeping with our studies, 2 surgical strategies have emerged as beneficial for patients with chronic symptoms: reverse optic capture (ROC) and placement of a secondary piggyback IOL. Failed surgical strategies include within-the-bag IOL exchange, wherein the original implant is removed and another IOL of different material, shape, or edge design is replaced within the capsular bag. This is in keeping with the work of Vamosi et al.<sup>3</sup> Reverse optic capture may be used in a secondary surgery for symptomatic patients or as a primary prophylactic strategy. In cases of the latter, the method has been applied to the second eye of patients who were significantly symptomatic following routine, uncomplicated surgery in their first eye. It should be noted, however, that ND symptoms are not necessarily bilateral.

Secondary ROC, performed for symptomatic patients, may be applied if the anterior capsulotomy is not too small, too thick, or rigid from postoperative fibrosis. At surgery, the anterior capsule is freed from the underlying optic by gentle, blunt dissection and viscodissection.



Next, the nasal anterior capsular edge is retracted with one Sinskey hook (Bausch & Lomb Inc) or a similar device, while the optic edge is elevated and the capsular edge is allowed to slip under the optic. This maneuver is repeated 180 degrees away temporally, leaving the haptics undisturbed in the bag.



UBM demonstrating reverse optic capture with the optic edge anterior to the capsular edge.

Primary or prophylactic ROC is performed at the time of initial cataract surgery for the symptomatic patient's fellow eye. It should be recognized that surgical success in achieving primary or secondary ROC is highly dependent on a properly sized and centered anterior capsulorrhexis. There seems to be little optical consequence of ROC, as the haptics remain in the bag; theoretically,

however, a modest myopic shift would be induced, varying directly with the power of the IOL.

### Positive Dysphotopsia

Positive dysphotopsia is reported by patients as light streaks, halos, starbursts, and so forth. It may be induced by internal reflections from either the optic edge or the optic surfaces.<sup>5</sup> Therefore, PD appears to be related directly to IOL material, optic size, index of refraction, radius of curvature, surface reflectivity, and edge design. Typically, PD is associated with a thick, square-edged design, high index of refraction, low radius of curvature, and high surface reflectivity.<sup>6,7</sup> Unlike ND, patients may perceive benefit from use of miotic agents, particularly under dim light conditions. Medical management of PD includes brimonidine tartrate 0.15%, which can be tried initially. Also useful is a dilute solution of pilocarpine, typically 0.5%. Although topical miotics may be helpful, they are associated with the potential for allergies and side effects. Should miotic therapy prove unsuccessful and the symptoms mandate further treatment, IOL exchange may be highly successful. In this situation, opt for a lens with a low index of refraction, large optic diameter, and a thin, round-edged design.

### Conclusion

Patients with either ND or PD require careful, concerned attention to their symptoms and a meaningful discussion of the suspected etiology, and they should be presented with a supportive plan for assistance.

### Financial Disclosure- None

### Conflicts of Interest- None

---

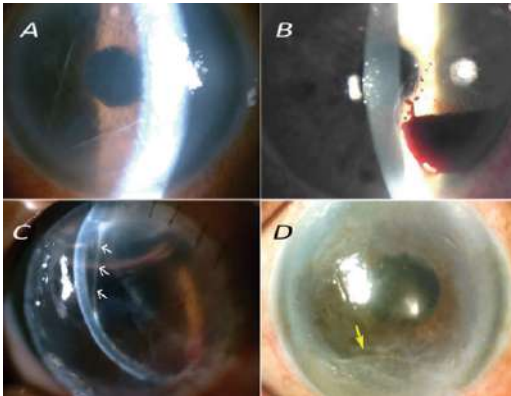
## References

1. DAVISON JA. POSITIVE AND NEGATIVE DYSPHOTOPSIA IN PATIENTS WITH ACRYLIC INTRAOCULAR LENSES. J CATARACT REFRACT SURG. 2000;26(9):1346-1355.
2. MASKET S, FRAM NR. PSEUDOPHAKIC NEGATIVE DYSPHOTOPSIA: SURGICAL MANAGEMENT AND NEW THEORY OF ETIOLOGY. J CATARACT REFRACT SURG. 2011;37(7):1199-1207.
3. VAMOSI P, CSÁKÁNY B, NÉMETH K. INTRAOCULAR LENS EXCHANGE IN PATIENTS WITH NEGATIVE DYSPHOTOPSIA SYMPTOMS. J CATARACT REFRACT SURG. 2010;36(3):418-424.
4. ERNEST PH. SEVERE PHOTIC PHENOMENON. J CATARACT REFRACT SURG. 2006;32(4):685-686.
5. HOLLADAY JT, LANG A, PORTNEY V. ANALYSIS OF EDGE GLARE PHENOMENA IN INTRAOCULAR LENS EDGE DESIGNS. J CATARACT REFRACT SURG. 1999;25(6):748-752.
6. MASKET S. TRUNCATED EDGE DESIGN, DYSPHOTOPSIA, AND INHIBITION OF POSTERIOR CAPSULE OPACIFICATION. J CATARACT REFRACT SURG. 2000;26(1):145-147.
7. MASKET S, GERAGHTY E, CRANDALL AS, ET AL. UNDESIRED LIGHT IMAGES ASSOCIATED WITH OVOID INTRAOCULAR LENSES. J CATARACT REFRACT SURG. 1993;19(6):690-694.

# How to manage Descemet's membrane detachment?

Dr Varun Malhotra<sup>1</sup>

<sup>1</sup>Center for Sight, Hyderabad, Tealanga



## Types of Descemet's membrane detachments. (Jacob S et al)

- Rhegmatogenous detachment
- Bullous detachment
- Tractional detachment
- Complex detachment

## Prevention

The following routine steps can be taken during cataract surgery to help prevent tears or detachments of DM:

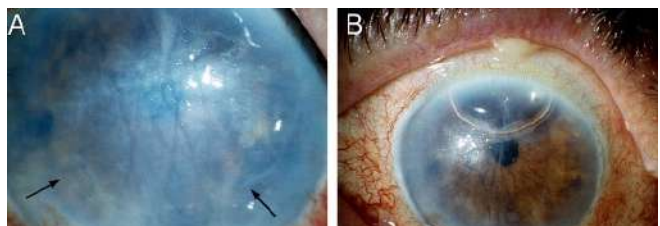
- First, use a sharp blade for all incisions. If any substantial resistance during wound construction is encountered, the blade should be removed, inspected, and preferably replaced with a new blade.
- Avoid forceful insertion of any instrument or device by altering the angle of insertion or enlarging the clear corneal or paracentesis incision.
- Ensure that the cannula tip has passed completely through the cornea into the anterior chamber before initiating injection of viscoelastic or other substances into the anterior chamber so to prevent dissection of DM from the stroma.

As soon as a DM tear or detachment is noted intraoperatively, the following precautions should be taken to avoid further damage to DM, particularly the anterior portion that lies superior to the incision site because of its potential to extend centrally:

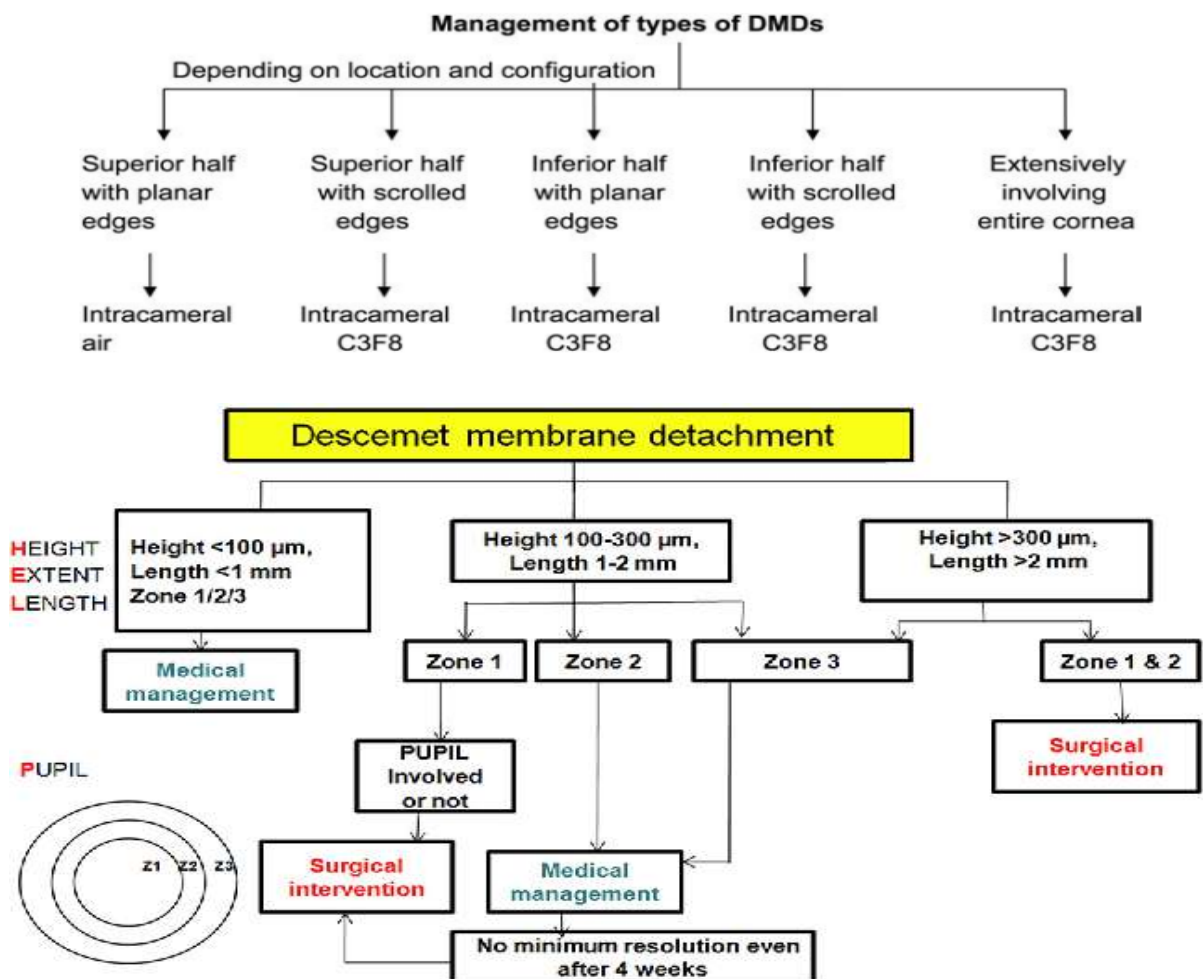
- Special attention should be given to posterior corneal abnormalities, particularly Fuchs' endothelial dystrophy. These conditions probably predispose the patient to easier stripping of DM during cataract surgery, due to a compromised endothelial pump.<sup>3</sup>
- Careful visualization of instruments and devices under higher magnification during insertion can help to prevent catching DM.
- Because it is more crucial to avoid the anterior portion of DM, placing more posterior pressure on the posterior lip of the incision during instrument or device insertion can help to avoid further stripping of DM centrally.
- Enlarging the incision and lubricating the incision with viscoelastic can ease the entry of instrument or device insertion through a tight wound.
- Using a dispersive (Viscoat; Alcon Laboratories) or adaptive (Healon<sup>5</sup>; Abbott Medical Optics Inc) viscoelastic can provide a temporary tamponade of the detachment. An alternate incision site is recommended (ie, the paracentesis incision is used for viscoelastic tamponade of DM detachment at the clear corneal incision and vice versa), and extra precaution needs to be taken to ensure that viscoelastic is not injected between DM and the stroma.

## Treatment

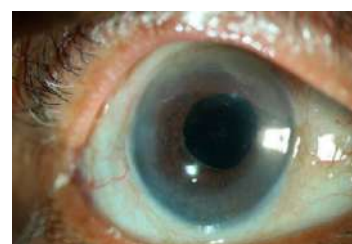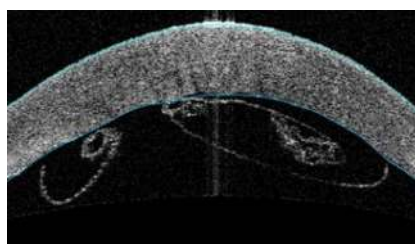
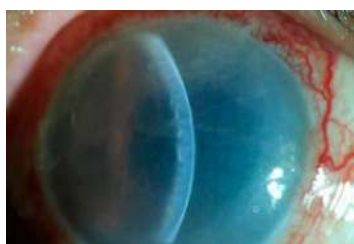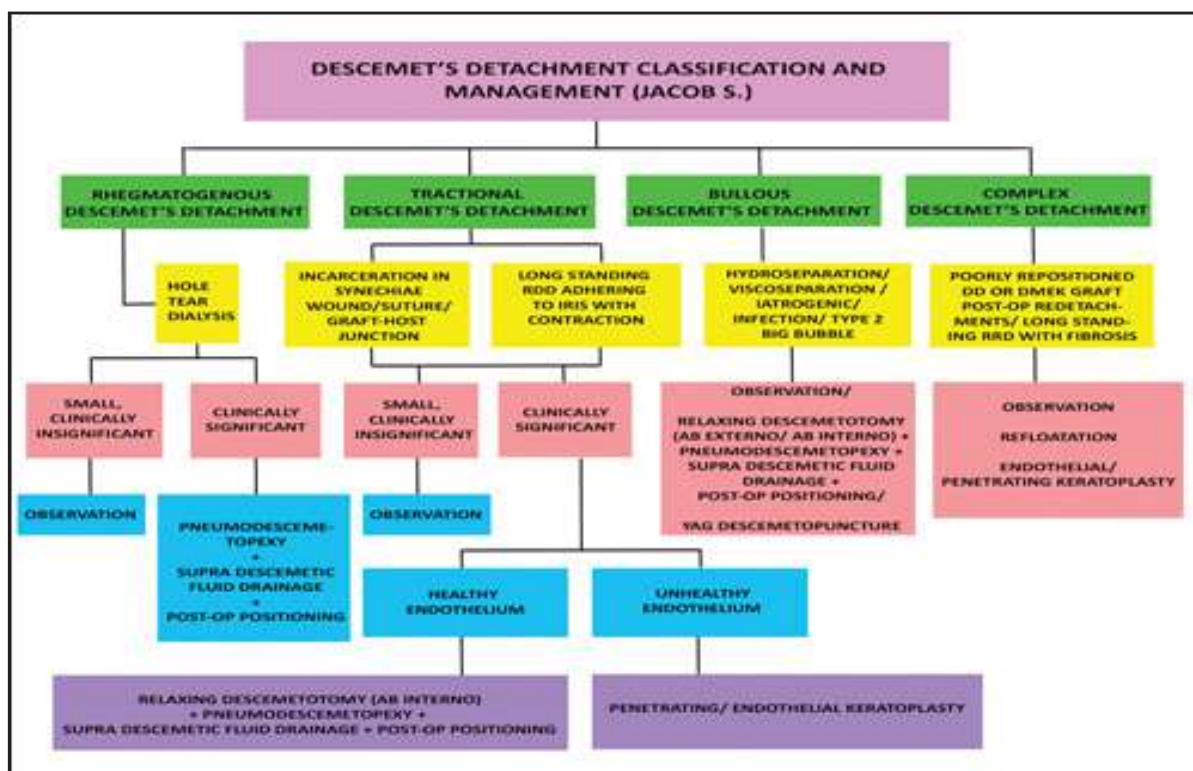
- For small DM detachments noted intraoperatively, no particular treatment is generally necessary.
- However, moderate- or large-sized detachments may necessitate aborting the cataract procedure and warrant intraoperative treatment with either air or gas tamponade, or perhaps suturing, at the conclusion of the case.



- The DM tear or scroll may need to be repositioned prior to tamponade treatment and, if so, excessive manipulation and direct contact with DM with any instrument should be avoided to minimize endothelial loss.
- If the detached DM is too torn, shredded, or scrolled, air or gas injection alone will not suffice. Intracameral air injection lasts a shorter time than gas and should be used for smaller detachments.
- For more extensive DM detachments, injection of a nonexpansive 20% concentration of SF6 gas with approximately 60% to 70% fills of the anterior chamber.
- With air or gas injection, proper head positioning may be required to ensure that the bubble is positioned correctly against the DM.
- These patients should be followed closely for intraocular pressure monitoring and DM reattachment, and they should be given cycloplegic medications to avoid pupillary block glaucoma.
- Frequently, DM detachments are not noted until slit-lamp examination is performed post-operatively. Clinically, these patients can present with severe corneal edema overlying the DM detachment, which can make the diagnosis difficult.
- The use of topical glycerin to clear the edema temporarily or imaging modalities (ie, AS OCT or UBM) can help to confirm the diagnosis.
- Topical corticosteroid therapy and observation are usually the first steps of treatment, with the hopes of spontaneous DM reattachment.
- For persistent DM detachments, the same aforementioned techniques utilizing air or gas can be used to reattach DM. Of note,
- A simplified technique for reattaching DM detachments postoperatively is using intracameral 20% SF6 gas. It can be performed with minimal instruments in a minor operating room or at the slit-lamp microscope.<sup>4</sup>
- Finally, various transcorneal suturing techniques may be necessary to address the more severe and refractory DM detachments.<sup>5</sup>
- 







**Prognosis-** The prognosis for small to moderate DM detachments remains excellent, especially with the more recently described technique of intracameral gas injection. However, permanent corneal decompensation can ensue with severe detachments and will require corneal transplantation. In this scenario, a posterior lamellar approach (ie, Descemet's stripping endothelial keratoplasty) can help minimize incision size, reduce postoperative astigmatism, and hasten visual recovery. In general, the surprising resiliency of the corneal endothelium allows these cells to remain viable, even in the state of DM detachment, so that continued pump function can resume upon successful treatment.

**Financial Disclosure- None**

**Conflicts of Interest- None**

## References

1. Monroe WD. Gonioscopy after cataract extraction. *South Med J.* 1971;64(9):1122-1124.
2. Pieramici D, Green WR, Stark WJ. Stripping of Descemet's membrane: a clinicopathologic correlation. *Ophthalmic Surg.* 1994;25(4):226-231.
3. Ti SE, Chee SP, Tan DT, Yang YN, Shuang SL. Descemet membrane detachment after phacoemulsification surgery: risk factors and success of air bubble tamponade. *Cornea.* 2013;32(4):454-459.
4. Kim T, Hasan SA. A new technique for repairing Descemet membrane detachments using intracameral gas injection. *Arch Ophthalmol.* 2002;120(2):181-183.
5. Olson RJ. Corneal problems associated with phacoemulsification. In: Fishkind WJ, ed. *Complications in Phacoemulsification: Recognition, Avoidance, and Management.* New York, NY: Thieme Medical Publishing; 2002.
6. Kumar DA, Agarwal A, Sivanganam S, Chandrasekar R. Height-, extent-, length-, and pupil-based (HELP) algorithm to manage post-phacoemulsification Descemet membrane detachment. *J Cataract Refract Surg.* 2015 Sep;41(9):1945-53.
7. Jacob S, Agarwal A, Chaudhry P, Narasimhan S, Chaudhry VN. A new clinico-tomographic classification and management algorithm for Descemet's membrane detachment. *Cont Lens Anterior Eye.* 2015 Oct;38(5):327-33.

## Surgical Technique

# Artificial Bag with Optic Capture (ABC) technique for Secondary Intraocular Lens Implantation

Dr Sunil Ganekal<sup>1</sup>

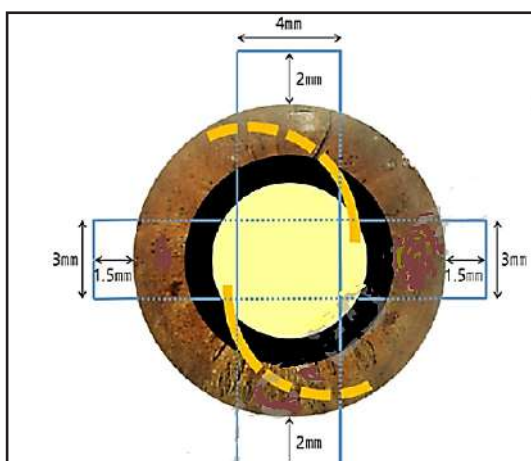
<sup>1</sup>Davangere Netralaya, Davangere, Karnataka, India

### Introduction

Several surgical techniques have been developed for the implantation of intraocular lenses (IOLs) in patients with weak or no zonular support, and recent studies have described various new methods of secondary IOL implantation. Since the first introduction of sutureless intrascleral fixation of the posterior chamber IOL by Gabor and Pavlidis in 2007,<sup>1,2</sup> the procedures of anterior chamber IOL (AC IOL), retro-pupillary iris-claw lens implantation,<sup>3</sup> Gore-Tex sutured IOL implantation<sup>4</sup>, and sutureless intrascleral fixation have been introduced by Dr. Yamane and performed in patients with zonule issues.<sup>5</sup> Compared to the suture-fixed IOL technique, the intrascleral fixation technique reduces IOL dislocation due to suture breakage or degradation and irritation or chronic conjunctival inflammation caused by exposure of the suture knot. However, the intrascleral fixation technique requires a long learning curve and is a particularly burdensome procedure from the perspective of the surgeon<sup>5</sup>. In this report, we introduce a newly developed secondary IOL implantation technique that uses an artificial bag with optic capture (i.e., ABC technique), and demonstrate the performance of this surgery in patients via "in-the-bag IOL dislocation."

Surgical technique-After the vitrectomy, correctly mark the center of the cornea and 4 directions (3, 6, 9 and 12 o'clock) at 90° intervals. A 25-gauge anterior chamber

maintainer was inserted into the clear cornea near the limbus at the at 7 o'clock position to maintain an intraocular pressure of 25 mmHg. A 10-0 prolene straight needle was inserted at either 3 or 9 o'clock and a distance 1.5 mm posterior from the corneal limbus, and was pulled through the opposite position (9 or 3 o'clock) using a 30-gauge guide needle. The needle was then passed horizontally beneath the conjunctiva for 3 mm, entered the sclera at the 9 or 3 o'clock position and was removed from the sclera at the opposite position (3 or 9 o'clock) using a 30-gauge guide needle. The needle was then passed horizontally under the conjunctiva for 3 mm and tied. After tying, the knot was rotated to secure its position in the sclera. The sutures were then reciprocated as described above at the 6 or 12 o'clock position, a distance 2 mm posterior from the corneal limbus and a 4 mm distance horizontally to form a rectangular shape. The sutures at 6 and 12 o'clock were confirmed to pass over the sutures at 3 and 9 o'clock. A 2.8-mm incision was made in the clear cornea, and a 3-piece IOL was inserted into the anterior chamber using the IOL injector. First, the haptic was placed on the iris. The haptic of the IOL was placed slowly in the sulcus, and the optic was initially placed at the center of the rectangular-shaped suture. Next, the optic was captured in the suture between 6 and 12 o'clock, and IOL centration was performed. The pupil was constricted using carpinol, the anterior maintainer was removed and the operation was completed once no leakage was confirmed. All



Schematic diagram of the ABC technique. Blue lines represent 10-0 prolene sutures, and the blue dashed line indicates the suture beneath the iris and optic of the intraocular lens (IOL). Yellow lines represent the IOL haptics, and the yellow dashed line indicates a location under the iris plane.

existing secondary IOL implantation methods<sup>1-5</sup> have advantages and disadvantages in terms of accessibility, ease of use, stability (e.g., corneal endothelial loss) and the possibility of postoperative IOL tilting<sup>6</sup>. In this report, we have introduced a new technique of secondary IOL implantation, the ABC technique, which is easy to perform and causes little IOL tilt. The maintenance of a stable IOL during the ABC technique relies on 3 major factors. First, because the optic is supported by an artificial bag formed by the suture, the haptics are correctly positioned at the sulcus after IOL insertion. Second, the posterior suture is located 0.5 mm in front of the anterior suture at the limbus, enabling the stable position of the optic via capture between the 2 sutures. Third, the posterior suture prevents dislocation of the IOL into the vitreous. Several surgical strategies can facilitate the performance of the ABC technique. First, we advise using corneal markers to mark the exact puncture site. Second, we recommend to minimizing the use of an ophthalmic viscoelastic device in favor of an anterior chamber maintainer. The latter device allows the sutures to be visualized clearly. Moreover, the intraocular pressure can be adjusted to stabilize the knots and bury them into the sclera more conveniently. Third, the order of suturing is important. We recommend performing the suture located 1.5 mm posterior from the limbus after the suture located 2 mm posterior from the limbus, because the performance of these sutures in the opposite order would cause the passage of the needle or guide needle back and forth over the existing (i.e., 1.5 mm posterior) suture and may cause damage. The ABC technique provides the following advantages. First, the procedure is simple and requires no special tools. Recently performed sutureless intrascleral fixation techniques require specific 3-piece IOLs and a low-temperature cautery to induce thermal deformation of the end of the haptic.<sup>5</sup> During Gore-Tex-sutured IOL implantation, the ophthalmologic use of Gore-Tex is off-label, and a ringed IOL is required.<sup>4</sup> In contrast, the ABC technique can be applied using common prolene sutures and any type of 3-piece IOL. Moreover, the ABC technique is convenient

for surgeons because it requires less IOL movement and fewer special manipulations. Second, the ABC technique is associated with few IOL position abnormalities such as tilting. Masket et al. previously introduced the “basket suture” to support the IOL in secondary implantation.<sup>7</sup> Our technique uses this basket suture with optic capture to ensure that not only is the haptic of the IOL precisely located at the sulcus, but the optic is also located stably between the 2 sutures. Consequently, IOL tilt and subluxation or phacodonesis are very unlikely. Third, because the suture is located beneath the conjunctiva, the knot should be located inside the sclera or in the vitreous. This removes the need for a scleral flap, reduces knot erosion and potentially decreases the total operative time. Still, the ABC technique also has some potential disadvantages. First, suture-related problems such as knot breakage might occur as the postoperative interval increases. This case study included a small number of cases and had a short duration of follow-ups. Therefore, we could not compare the rate of suture-related problems between the ABC technique and conventional transscleral fixation technique; further cohort-case studies or comparative casecontrol studies are needed. Second, the procedure involves 8 scleral punctures via needles and guide needles, which could result in hemorrhage or ciliary body injury or detachment. However, these potential complications might be prevented by using a sharp needle and ensuring a precise needle entry at least 1.5 mm posterior from limbus. If the site of needle penetration is not marked correctly and the puncture is not performed correctly during the procedure, optic capture may be difficult or the IOL may be less stable. Third, the sutures are located within the range of pupil dilation. Therefore, we cannot completely rule out the possibility of postoperative optical problems or altered visual functions. In conclusion, the ABC technique is a simple, easy-to-perform technique that can achieve stable results without causing IOL tilt and conjunctival problems in patients with zonular weakness or no zonular support. This new secondary IOL implantation method is also easily accessible to surgeons.

## References

1. Gabor SGB, Pavlidis MM. Sutureless intrascleral posterior chamber intraocular lens fixation. *J Cataract Refract Surg* 2007; 33:1851–1854
2. Saleh M, Heitz A, Bourcier T, et al. Sutureless intrascleral intraocular lens implantation after ocular trauma. *J Cataract Refract Surg* 2013; 39:81–86
3. Jing W, Guanlu L, Qianyin Z, et al. Iris-claw intraocular lens and scleral-fixated posterior chamber intraocular lens implantations in correcting aphakia: a meta-analysis. *Invest Ophthalmol Vis Sci* 2017; 58:3530–3536
4. Khan MA, Gerstenblith AT, Dollin ML, et al. Scleral fixation of posterior chamber intraocular lenses using gore-tex suture with concurrent 23-gauge pars plana vitrectomy. *Retina* 2014; 34:1477–1480.
5. Yamane S, Sato S, Maruyama-Inoue M, Kadonosono K. Flanged intrascleral intraocular lens fixation with double-needle technique. *Ophthalmology* 2017; 124:1136–1142
6. Nudleman E, Yonekawa Y, Prenner JL. Sutureless transscleral fixation of secondary intraocular lenses. *Curr Opin Ophthalmol* 2018; 29:210–216
7. Masket S, Fram NR. Safety-basket suture for management of malpositioned posterior chamber intraocular lens. *J Cataract Refract Surg* 2013; 11:1633–1635.



# KARNATAKA OPHTHALMIC SOCIETY

## KOSCON 2022

HOSTED BY  
HUBLI -DHARWAD  
OPHTHALMIC SOCIETY

 **BLOCK YOUR DATE!**

Dates: 9<sup>th</sup>, 10<sup>th</sup> & 11<sup>th</sup> Dec' 2022

Place: Hubli

Venue: Denissons hotel

### Management Committee Members



Dr. Shivanand B Patil  
President



Dr. Hemanth Murthy  
President Elect



Dr. Krishna Prasad Kudlu  
Vice President



Dr. Shrinivas M Joshi  
Hon Secretary



Dr. Vikram Jain  
Hon Joint Secretary



Dr. Chaithra Jayadev  
Scientific Committee  
Chairman



Dr. Elankumaran P  
Treasurer



Dr. Sunil Ganekal  
Editor, Journal



Dr. Rajashekar Y L  
Immediate President

### Scientific Committee Members



Dr. Mallikarjun Heralgi



Dr. Thirumalesh M B



Dr. Ajay Kudva



Dr. Basavaraj Kadiwal C



Dr. Shibi Deb B N